

# Progressive non-ischaemic cardiomyopathy resulting in T-wave oversensing and inappropriate shocks: case report

Postępująca kardiomiopatia nieniedokrwienna powodująca nadczułość załamek T i nieprawidłową stymulację – opis przypadku

Bahri Koroglu, Umüt Celikyurt, Aysen Agacdiken, Ahmet Vural

Kocaeli University Medical Faculty, Department of Cardiology, Kocaeli, Turkey

## Abstract

T-wave oversensing is one of the causes of inappropriate shocks. It results from various conditions, including progressive cardiomyopathy, diminution of R-wave amplitude and relative or dynamic gain in the T-wave amplitude, electrolyte abnormalities and injury current-related increase in the T-wave voltage. We report a 59-year-old patient, who presented with implantable cardioverter-defibrillator shocks after the 5-year implantation period with decreased R-wave amplitude and T-wave changes on 12-lead electrocardiography.

Key words: progressive non-ischaemic cardiomyopathy, T-wave oversensing, inappropriate shocks

Folia Cardiologica 2018; 13, 1: 51–54

## Case report

A 59-year-old female with hypertension and non-ischaemic dilated cardiomyopathy was examined for recurrent implantable cardioverter-defibrillator (ICD) shocks (10 shocks in 24 hours). In the medical history of the patient, dual-chamber ICD was implanted in 2011 because of dilated cardiomyopathy and decreased left ventricular systolic function (ejection fraction 10–15%) for the primary prevention of sudden cardiac death. Medical therapy included ACE-inhibitor, beta-blocker, spironolactone and furosemide. The electrocardiography (ECG) revealed R-wave progression loss in V1–V4 (Figure 1). The subsequent ECG revealed decreased R-wave amplitude with T-wave negativity in D II, III, aVF and V5–V6, compared to previous ECG 5 years ago (Figure 2). Blood chemistry was within a normal range except for slightly increased cardiac marker levels, which was thought as a result of the ICD shocks. A posteroanterior chest radiography showed a normal position of right

ventricular lead. Transthoracic echocardiography revealed dilated cardiomyopathy (DCM) with decreased left ventricular systolic function. The left ventricular end-diastolic and systolic diameters of the left ventricle increased from 68 to 72 mm and from 57 to 60 mm, respectively. At pacemaker interrogation, R-wave amplitude was 18.1 mV with a pacing threshold of 0.7 V at 0.40 ms and R-wave sensitivity of 0.30 mV. The stored electrograms revealed T-wave oversensing with resultant inappropriate double counting and inappropriate ICD shocks (Figures 3, 4). At initial implantation, R-wave amplitude was 24.4 mV with a ventricular pacing threshold 0.6 V at 0.40 ms and R-wave sensitivity of 0.30 mV.

## Discussion

T-wave oversensing is one of the causes of inappropriate shocks. Possible causes of T-wave oversensing include progressive cardiomyopathy, diminution of R-wave amplitude

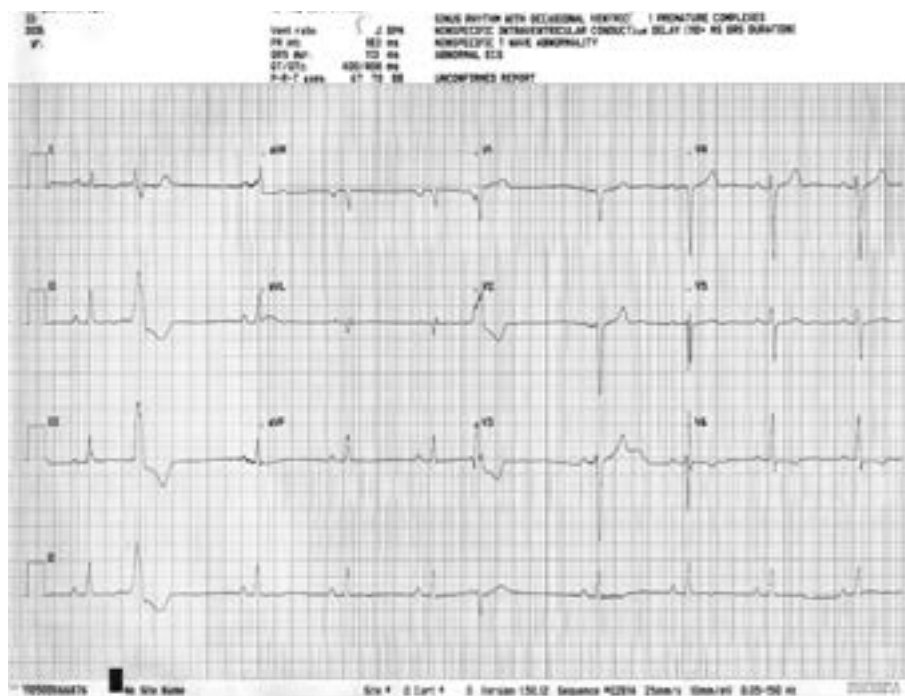


Figure 1. Electrocardiography of the patient at the time of implantable cardioverter-defibrillator implantation

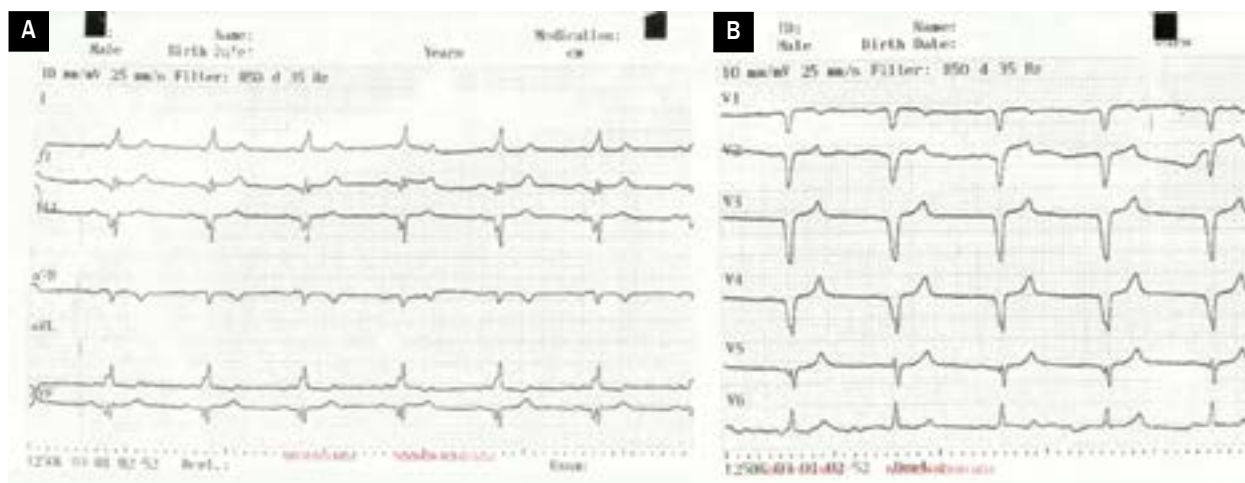


Figure 2A, B. Electrocardiography of the patient at hospital admission due to inappropriate shocks

and relative or dynamic gain in the T-wave amplitude, electrolyte abnormalities and injury current-related increase in the T-wave voltage [1–3].

Dilated cardiomyopathy is a progressive disease characterised by the enlargement of the left ventricle, systolic dysfunction and decreased myocardial wall thickness. The progression of DCM in our patient could be the reason of the alteration of R-wave and T-wave amplitudes, as well as T-wave oversensing. Watanabe et al. reported T-wave

oversensing in seven patients at  $16.7 \pm 19.3$  months after ICD implantation [4]. An R-wave of  $< 5$  mV in intracardiac electrogram (EGM) was recorded in six of their seven patients. Interestingly, low R-wave amplitude was not present in our case. However, an increased T-wave amplitude was detected on EGM.

Elimination of T-wave oversensing could be possible by the correction of the reversible causes, repositioning of the ventricular sensing lead or addition of a sensing




Figure 3. Intracardiac tachogram showing classical railroad track

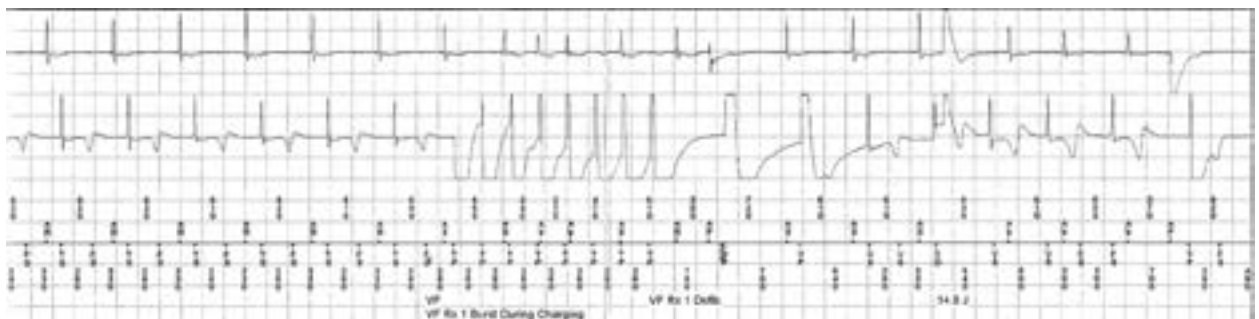


Figure 4. Intracardiac electrogram showing T-wave oversensing, ventricular fibrillation detection, antitachycardia pacing and defibrillation

lead [4]. Reprogramming the ICD to lower sensitivity could also be helpful. Although decreasing the sensitivity to prevent T-wave oversensing may result in delayed confirmation of arrhythmic events and undersensing of ventricular tachyarrhythmias, we simply reduced the sensitivity from 0.30 mV to 0.45 mV, as the sensing and pacing parameters were normal. At three months follow-up, the patient was asymptomatic without any shocks.

This case reflects the importance of 12-lead ECG on the follow-up of patients with ICDs. Although intracardiac R-wave sensing was normal, T-wave oversensing should be suspected in patients with progressive decreased R-wave amplitude and T-wave changes on 12-lead ECG.

#### Conflicts of interest(s)

None.

#### Streszczenie

Nadczułość załamka T jest jedną z przyczyn nieprawidłowej stymulacji. Może być ona spowodowana różnymi zaburzeniami, takimi jak postępująca kardiomiopatia, zmniejszenie amplitudy załamka R i względne lub dynamiczne zwiększenie amplitudy załamka T, zaburzenia elektrolitowe oraz zwiększenie woltażu załamka T spowodowane prądem uszkodzenia. Przedstawiono przypadek 59-letniego chorego z wszczepionym 5 lat wcześniej kardiowerterem-defibrylatorem serca, u którego stwierdzono w 12-odprowadzeniowym elektrokardiogramie zmniejszoną amplitudę załamków R i zmienione załamki T.

Słowa kluczowe: postępująca kardiopatia nieniedokrwienna, nadczułość załamka T, nieprawidłowa stymulacja

Folia Cardiologica 2018; 13, 1: 51–54

## References

1. Jimenez-Lopez J, Arias MA, Akerstrom F, et al. A single shock during an episode of ventricular tachycardia: is the device working properly? *Indian Pacing Electrophysiol J.* 2012; 12(5): 226–228, doi: [10.1016/s0972-6292\(16\)30545-9](https://doi.org/10.1016/s0972-6292(16)30545-9), indexed in Pubmed: [23071384](https://pubmed.ncbi.nlm.nih.gov/23071384/).
2. Srivathsan K, Scott LR, Altemose GT. T-wave oversensing and inappropriate shocks: a case report. *Europace.* 2008; 10(5): 552–555, doi: [10.1093/europace/eun083](https://doi.org/10.1093/europace/eun083), indexed in Pubmed: [18442965](https://pubmed.ncbi.nlm.nih.gov/18442965/).
3. Rasania SP, Mountantonakis S, Patel VV. Inappropriate ICD shocks caused by T-wave oversensing due to acute alcohol intoxication. *Pacing Clin Electrophysiol.* 2012; 35(9): e267–e271, doi: [10.1111/j.1540-8159.2012.03348.x](https://doi.org/10.1111/j.1540-8159.2012.03348.x), indexed in Pubmed: [22385111](https://pubmed.ncbi.nlm.nih.gov/22385111/).
4. Watanabe H, Chinushi M, Izumi D, et al. Decrease in amplitude of intracardiac ventricular electrogram and inappropriate therapy in patients with an implantable cardioverter defibrillator. *Int Heart J.* 2006; 47(3): 363–370, doi: [10.1536/ihj.47.363](https://doi.org/10.1536/ihj.47.363), indexed in Pubmed: [16823242](https://pubmed.ncbi.nlm.nih.gov/16823242/).