

Acute coronary syndrome in 16-year-old boy: case report

Ostry zespół wieńcowy u 16-letniego chłopca – opis przypadku

Santosh Kumar Sinha, Puneet Kumar, Karandeep Singh, Mahmudula Razi,
Ramesh Thakur, Chandra Mohan Varma, Umeshwar Pande

Department of Cardiology, LPS Institute of Cardiology, G.S.V.M. Medical College, Kanpur, India

Abstract

Spontaneous coronary artery dissection is a rare but important cause of acute coronary syndromes in young patients. 16-year-old boy presented as acute anterior wall myocardial infarction for which he was thrombolysed. Coronary angiogram showed spiral luminal filling defects, with extensive contrast staining of proximal left anterior descending artery and its branches. The patient refused angioplasty, which was advised, and was managed conservatively. Three weeks later he presented with acute coronary syndrome with unstable angina. Repeated angiogram showed complete healing of dissection. The hospital course of the patient was uncomplicated. This shows, that sometimes higher grade dissection beside intervention, can respond to conservative management as well.

Key words: spontaneous coronary artery dissection, thrombolysis, unstable angina

Folia Cardiologica 2018; 13, 1: 47–50

Introduction

Spontaneous coronary artery dissection (SCAD) is a rare but important cause of acute coronary syndromes. In comparison with the usual myocardial infarction population, it occurs in relatively young people with a striking predilection for women. Clinical presentation ranges from asymptomatic to acute coronary syndrome, ventricular arrhythmias, heart failure and sudden cardiac death. Predisposing factors include atherosclerosis, the peripartum period, and structural and inflammatory conditions affecting the arterial wall or extension of aortic dissection. In interventional era, early angiography in the primary percutaneous coronary angioplasty has led to earlier identification of patients with SCAD and may encourage an increased use of various revascularisation strategies. Prompt diagnosis and treatment of patients with dissection improves survival. Management of SCAD can sometimes be challenging. Various treatment options have been utilised, including medical therapy, percutaneous coronary intervention (PCI) and coronary artery

bypass graft surgery (CABG), though primary percutaneous coronary intervention remains the reperfusion strategy of choice. The present article describes the case of spontaneous healing of type-D dissection, where PCI would have been the first choice, showing that sometimes watchful waiting can pay.

Case report

A 16-year-old apparently healthy boy presented with acute anterior wall myocardial infarction of a 2-hour window period. His pulse rate was 85 beats/min and arterial blood pressure was 110/84 mm Hg. His risk factors included smoking. Other physical examination findings were all normal. Admission electrocardiogram showed normal sinus rhythm and ST-elevation in V1 to V6 with reciprocal depression in inferior leads. An echocardiogram revealed anteroseptal, apical and lateral wall hypokinesia, mild left ventricular (LV) systolic dysfunction with ejection fraction (EF) of 45%. Blood chemistry was normal. After preloading

with aspirin 300 mg and clopidogrel 300 mg, the patient was thrombolysed with Tenecteplase on weight based dosing. At 90 minute there was a little resolution of chest pain with ECG showing failed lyses. Injection of tirofiban was started with loading dose of 0.4 mcg/kg/minutes for 30 minutes followed by 0.1 mcg/kg/minute. Coronary angiography was performed next day using 6 F Judkins left and right catheters (Medtronic, Minneapolis, USA) through femoral route after proper consent. There was a spiral dissection (type D) with dissection flap beginning from the proximal segment extending up to the mid left anterior descending (LAD) artery and another involving first diagonal (Figures 1–3). The dissection was appreciated

with the first injection and the position of the catheter tip was well away from the origin of the LAD. The rest of the patient coronary arteries were normal without any evidence of atherosclerosis or dissection. Urgent PTCA to LAD was planned and advised, but the patient refused any intervention and therefore was managed conservatively with guideline-directed medical therapy and discharged on fifth day in stable condition. After 4 weeks he again presented with unstable angina and was managed accordingly. Coronary angiography was performed using 6 F Judkins left and right catheters (Medtronic, Minneapolis, USA) through femoral route. There was the complete healing of the dissection (Figure 4). Echocardiography indicated normal LV systolic

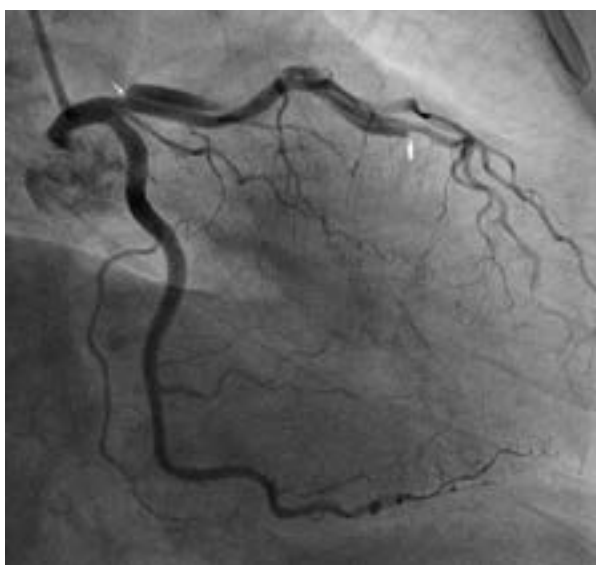

Figure 1. Right anterior oblique caudal view showing spiral dissection of proximal left anterior descending (LAD) artery (white arrow showing flap)

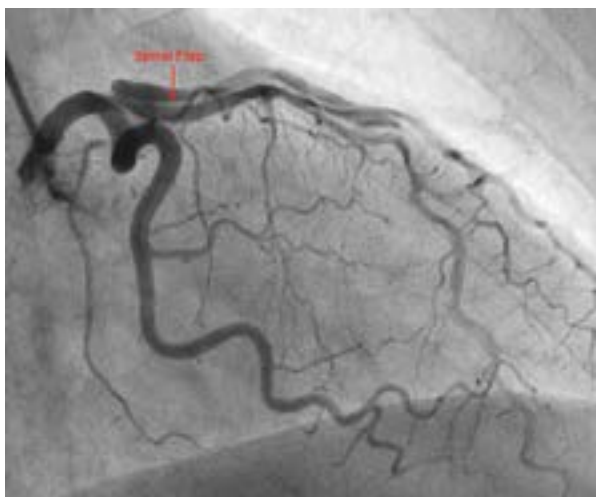


Figure 2. Right anterior oblique caudal view showing spiral dissection in proximal left anterior descending (LAD) artery and first diagonal

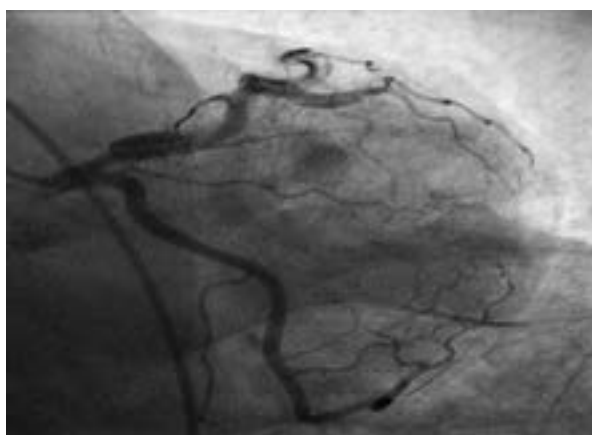


Figure 3. Anterior-posterior caudal view showing the dissection flap

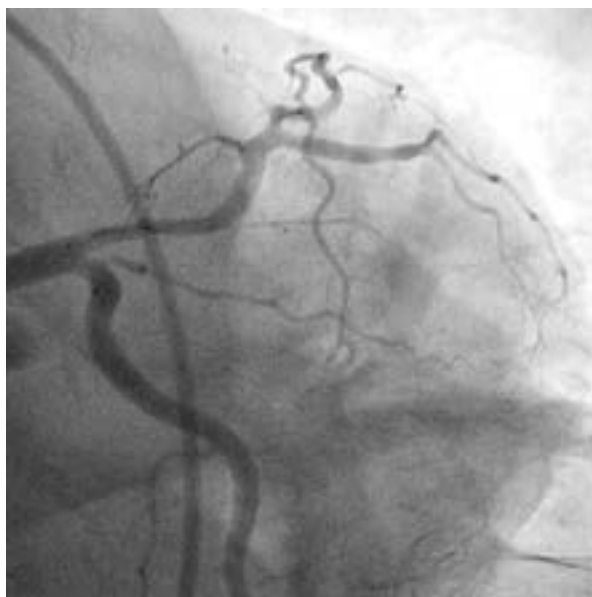

Figure 4. Anterior-posterior caudal view showing complete healing of dissection

function. The patient was then discharged on third day in stable condition with anti-platelets, statin, beta-blocker, ACE-inhibitor and feeling well since then.

Discussion

Coronary artery dissection is defined as the separation of the media by haemorrhage with or without an associated intimal tear [1]. Accordingly, The National Heart Lung and Blood Institute (NHLBI) classification of dissection has been proposed [2]. A dissection can be very benign without any haemodynamic effect or flow may be compromised by the dissection flap which, in turn, may cause myocardial ischaemia or infarction. Spontaneous dissection of the coronary arteries is a rare cause of myocardial infarction, and usually females predominates over males. The majority of dissections that do not result in acute ischaemic complications heal with time, leaving no negative impact on the restenosis rate [3]. There is no consensus on the treatment strategies of SCAD. Conservative medical management may be an option [4, 5]. It is rational to give anti-platelet therapy because of the potential limitation of the flow caused by the platelet-rich thrombi [6]. The exact role of thrombolysis during an acute myocardial infarction due to SCAD is uncertain with both reports of angiographic worsening and improvement. Thrombolytic agents may help to lyse the

thrombus of the false lumen enabling the coronary flow to be established in the true lumen, which is beneficial in preserving myocardial viability [7, 8]. Glycoprotein IIb/IIIa (GP IIb/IIIa) antagonist, tirofiban, has been successfully used in this context [9]. Invasive strategies, especially percutaneous transluminal coronary angioplasty (PTCA), are more common of the mentioned treatments. Although stent implantation may provide a prompt mechanical relief for the impaired coronary flow, this strategy involves the risks of coronary perforation, extending the dissection by extruding the intramural thrombus and implantation of the stent in the false lumen [7]. This case reports an unusual cause of an acute myocardial infarction. A SCAD should be entertained in the differential diagnosis of an acute coronary event, especially in a young, otherwise healthy male. As mortality in this disease stems from the acute event, an urgent coronary angiogram examination may help to establish the diagnosis and the proper management. The role of a thrombolytic agent during the acute event is exactly not known. This case may illustrate the possible benefit of thrombolysis in SCAD, as well as conservative strategy, where PTCA would have been warranted.

Conflict of interest(s)

None.

Streszczenie

Samoistne rozwarstwienie tętnicy wieńcowej jest rzadką, lecz ważną, przyczyną ostrych zespołów wieńcowych u młodych pacjentów. W niniejszej pracy przedstawiono przypadek 16-letniego chłopca, u którego wystąpił ostry zawał ściany przedniej. Zastosowano leczenie trombolityczne. W koronarografii stwierdzono ubytki wypełnienia w kształcie spiralnym z silnym zakontrastowaniem proksymalnego odcinka gałęzi międzykomorowej przedniej i jej gałęzi. Zalecono wykonanie angioplastyki wieńcowej, jednak chory nie wyraził zgody na zabieg i w związku z tym zastosowano leczenie zachowawcze. Po 3 tygodniach u pacjenta wystąpił ostry zespół wieńcowy w postaci niestabilnej dławicy piersiowej. W wykonanym powtórnie angiogramie stwierdzono całkowite wygojenie rozwarstwienia. Hospitalizacja chorego przebiegała bez powikłań. Opisany przypadek pokazuje, że w niektórych rozwarstwieniach znacznego stopnia można uzyskać dobrą odpowiedź na leczenie zachowawcze bez zabiegów interwencyjnych.

Słowa kluczowe: samoistne rozwarstwienie tętnicy wieńcowej, tromboliza, niestabilna dławica piersiowa

Folia Cardiologica 2018; 13, 1: 47–50

References

1. Waller B.F. Hurst's the heart. Chapter 47. 11th edition. Indiana University, Indianapolis 2017.
2. Huber MS, Mooney JF, Madison J, et al. Use of a morphologic classification to predict clinical outcome after dissection from coronary angioplasty. *Am J Cardiol.* 1991; 68(5): 467–471, doi: [10.1016/0002-9149\(91\)90780-o](https://doi.org/10.1016/0002-9149(91)90780-o), indexed in Pubmed: [1872273](https://pubmed.ncbi.nlm.nih.gov/1872273/).
3. Savage M, Dischman D, Bailey S, et al. Vascular remodelling of balloon-induced dissection: Long-term angiographic assessment. *J Am Coll Cardiol.* 1995; 25: 135A.
4. Zampieri P, Aggio S, Roncon L, et al. Follow up after spontaneous coronary artery dissection: a report of five cases. *Heart.* 1996; 75(2): 206–209, doi: [10.1136/hrt.75.2.206](https://doi.org/10.1136/hrt.75.2.206), indexed in Pubmed: [8673763](https://pubmed.ncbi.nlm.nih.gov/8673763/).

5. Oka S, Manabe K, Gondo H, et al. A case of acute myocardial infarction due to primary coronary dissection. *Jpn Circ J.* 1997; 61(11): 954–957, doi: [10.1253/jcj.61.954](https://doi.org/10.1253/jcj.61.954), indexed in Pubmed: [9391865](https://pubmed.ncbi.nlm.nih.gov/9391865/).
6. Butler R, Webster MWI, Davies G, et al. Spontaneous dissection of native coronary arteries. *Heart.* 2005; 91(2): 223–224, doi: [10.1136/hrt.2003.014423](https://doi.org/10.1136/hrt.2003.014423), indexed in Pubmed: [15657239](https://pubmed.ncbi.nlm.nih.gov/15657239/).
7. Buys EM, Suttorp MJ, Morshuis WJ, et al. Extension of a spontaneous coronary artery dissection due to thrombolytic therapy. *Cathet Cardiovasc Diagn.* 1994; 33(2): 157–160, doi: [10.1002/ccd.1810330216](https://doi.org/10.1002/ccd.1810330216), indexed in Pubmed: [7834730](https://pubmed.ncbi.nlm.nih.gov/7834730/).
8. Behnam R, Tillinghast S. Thrombolytic therapy in spontaneous coronary artery dissection. *Clin Cardiol.* 1991; 14(7): 611–614, indexed in Pubmed: [1747972](https://pubmed.ncbi.nlm.nih.gov/1747972/).
9. Cheung S, Mithani V, Watson R. Healing of spontaneous coronary dissection in the context of glycoprotein IIB/IIIA inhibitor therapy: a case report. *Catheter Cardiovasc Interv.* 2000; 51(1): 95–100, doi: [10.1002/1522-726x\(200009\)51:1<95::aid-ccd22>3.0.co;2-m](https://doi.org/10.1002/1522-726x(200009)51:1<95::aid-ccd22>3.0.co;2-m), indexed in Pubmed: [10973029](https://pubmed.ncbi.nlm.nih.gov/10973029/).