

Successful percutaneous retrieval of a dislodged J-tip guide wire by a self-constructed snare in a 75-year-old patient: a safe and feasible approach

Skuteczne usunięcie przemieszczonego przewodnika z końcówką w kształcie „J”
za pomocą samodzielnie skonstruowanej pętli u 75-letniego pacjenta
– bezpieczna i dostępna metoda

Santosh Kumar Sinha, Mukesh Jitendra Jha, Divendu Khanra, Avinash Kumar Singh,
Vikas Mishra, Pradyot Tiwari, Ramesh Thakur

Department of Cardiology, LPS Institute of Cardiology, G.S.V.M. Medical College, Kanpur, India

Abstract

Since the first report of percutaneous retrieval of intravascular foreign body in 1964, it has been accepted as a favourite approach for intravascular foreign body removal. Snares, biopsy forceps, dormia basket or tip deflecting wires are available in the armamentarium for this approach. Herein, we report percutaneous retrieval of a dislodged J-tip guide-wire by self-constructed snare. A patient was a 75-year-old woman who was admitted with capture failure following post pacemaker implantation. J-tip guide-wire was inadvertently left in her inferior vena cava during temporary pacemaker insertion. The guide wire was approached through right subclavian vein by a self-constructed snare and it was removed without any complications. Use of snares for intravascular foreign body removal is frequently reported and has been successful with low complication rates; also, the low cost of such snares makes it safe and economical.

Key words: intravascular foreign body, J-tip guide wire, percutaneous retrieval, self-constructed snare

Folia Cardiologica 2017; 12, 4: 371–374

Introduction

Temporary pacing lead insertion is done before permanent lead implantation. Complications may arise in as many as 5–8% of these procedures, although loss of the guide wire is rare. Non-invasive retrieval of intravascular foreign bodies has become a preferred approach for intravascular objects removal since the first report by Thomas et al. in 1964 [1]. Further efforts with various techniques have lead to higher success rates and low complications. Herein, we report retrieval of a dislodged J-tip guide-wire by self-constructed snare in a 75-year-old woman.

Case report

A 75-year-old woman was admitted with recurrent episodes of syncope following post pacemaker implantation two weeks back. Her electrocardiogram was showing complete heart block with the right bundle branch block (RBBB) type of ventricular escape and there was loss of pacemaker capture. Her pulse rate was 30/min. Her vitals were stable with normal biochemistry. Echocardiogram was normal. There was dislodgement of lead which was evident on fluoroscope (Figure 1). Temporary pacemaker implantation was done through the femoral route after obtaining proper

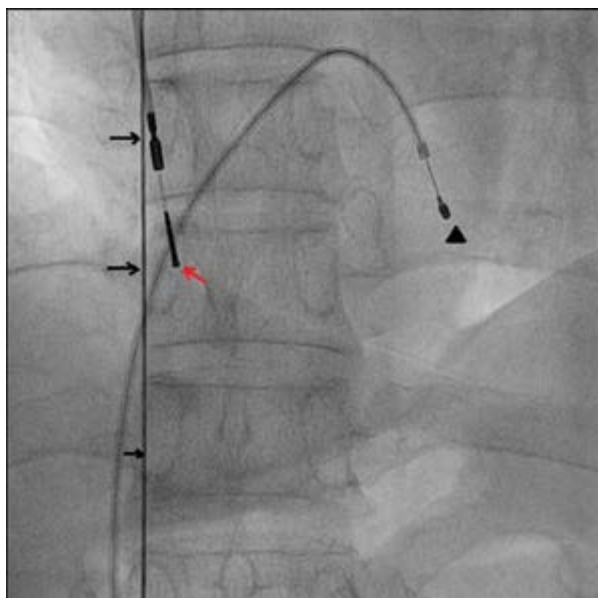


Figure 1. Dislodgement of permanent pacing lead (red arrow), embolised J-tip guide wire (black arrow) and temporary pacing lead (black arrowhead)

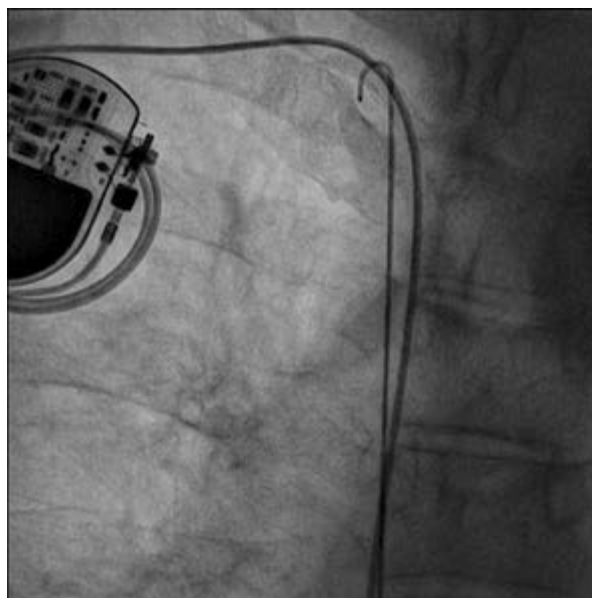


Figure 2. Distal fragment of J-tip guide wire was seen in the right superior vena cava

consent as bail out procedure. After infiltrating the skin with 2% xylocaine as local anaesthesia, the femoral vein was punctured. A 6 F 11 cm INPUT™ TS introducer sheath (Medtronic, USA) was inserted into the femoral vein. Temporary pacing lead was put and regular pacing was obtained but J-shaped 0.038" wire was left inadvertently (Figure 1, 2). Fluoroscopy was performed to check for dislodgement. Distal fragment was found in the right superior vena cava whereas proximal was in inferior vena cava (Figure 2). The patient was asymptomatic. Retrieval was planned, but we had no snare available at that time. The right cephalic vein was punctured using extra-thoracic technique under fluoroscope and a 7 F 11 cm INPUT™ TS introducer sheath (Medtronic, USA) was inserted taking utmost care not to injure the permanent pacing lead. A 0.014" 180 cm percutaneous transluminal coronary angioplasty wire was taken and its loop was passed through standard 6 F JR4 Proflo® guiding catheters (Medtronic, USA), the lengths of which were shortened by cutting 20 cm from the tip to accommodate the loop, as the length of both the JR4 and the loop was 90 cm, and thus a snare was constructed by catching both free ends with arterial forceps (Figure 3). Guiding catheter was passed into the venous sheath over 0.035" terumo straight tip wire and parked in inferior vena cava below the proximal tip of venous wire. Terumo wire was then withdrawn. Customised snare was passed through guiding catheter and the embolized fragment was tried to be retrieved but failed (Figure 4). Snare was removed then and a small curve was provided 2–3 cm. proximal




Figure 3. Self-constructed snare being caught by both free ends with arterial forceps

to distal tip (Figure 3). This snare was re-introduced into the inferior vena cava under fluoroscopic guidance and the embolized fragment was successfully retrieved (Figures 5, 6). Ventricular pacing lead (passive fixation lead-Selox ST 60, Biotronik) was repositioned and parameters were tested. The patient was discharged in stable condition after one week with regular capture and regularly following up since then.

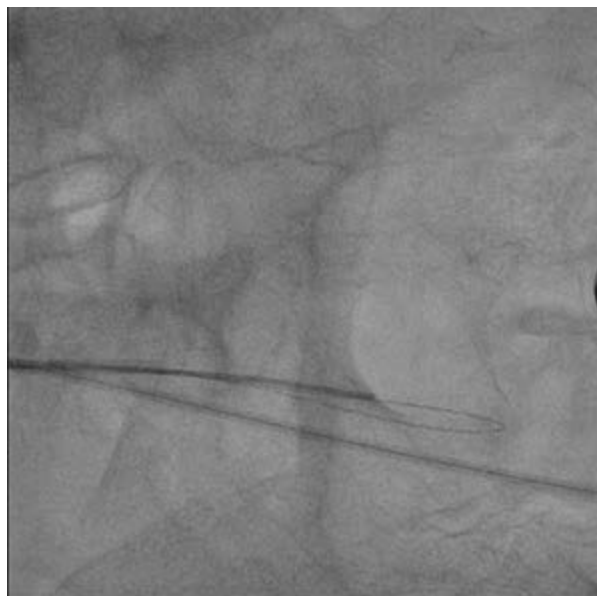


Figure 4. Snare was passed through guiding catheter and the embolized fragment was tried to be retrieved but failed

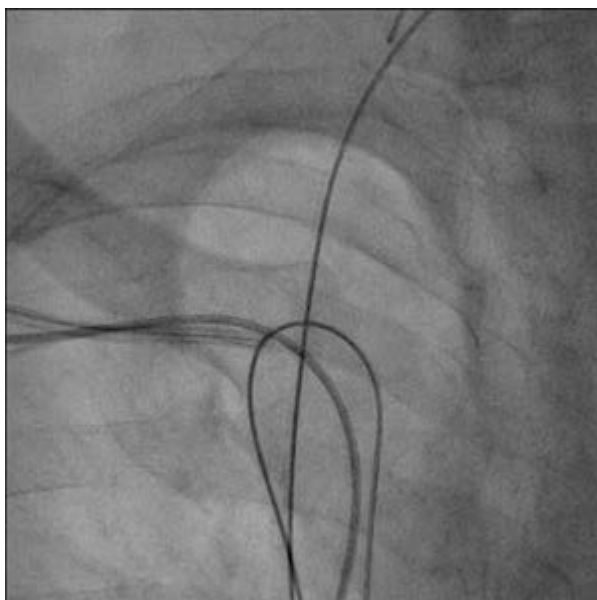


Figure 5. Embolized fragment was successfully trapped by snare

Discussion

Percutaneous retrieval of intravascular foreign bodies was first introduced in 1964 by Thomas et al. [1], presenting non-surgical retrieval of a broken segment of steel spring

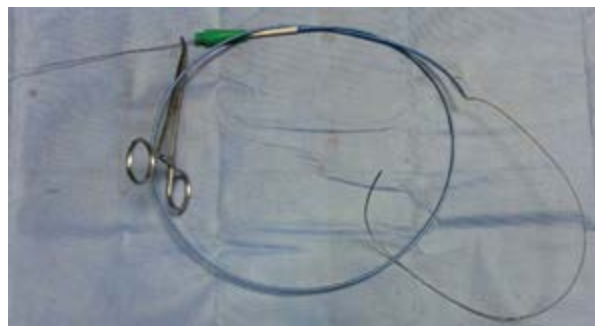

Figure 6. Snare with embolized fragment after successful retrieval

guide from right atrium and inferior vena cava. Today it is a more frequently applied technique as varieties of intravascular foreign bodies (including coils, stents, vena cava filters, etc) has increased because of numbers of interventional procedures has skyrocketed [2]. So, multiple options in the form of snares, biopsy forceps, dormia basket or tip deflecting wires are being utilized as retrieval tools depending on the need [3–5]. Retrieval of foreign objects by snare is more convenient but manier times commercial nitinol gooseneck micro snare are not available. Infection, thrombogenicity, distal ischemia, perforation of chambers and thromboembolism are the usual complications depending on the type of foreign object. Guide wires in venous system can damage or embolize the vessel's wall,so requires their immediate removal [6]. Patients with cardiopulmonary localization of foreign objects are at risk of severe complications varying from cardiac arrhythmia to perforation of cardiac chambers [7]. The success rate of retrieval of dislodged guide wires about 90% [8]. Self-constructed snare as in our case offers a great chance of rotational capabilities and a wider diameter to grasp the foreign object. Its profile also makes it extremely handy to guide into desired position. In addition, its cost-effectiveness makes it less of a burden to the patient. When snare was straight, it was not able to catch-hold the embolised wire but once it was little angled by a providing a proximal curve, job was easily done. Greatest advantages of self-constructed snares are that they can be shaped depending on the need. Percutaneous removal should be the first choice in the management of intravascular foreign bodies and should be performed as soon as the diagnosis is made.

Conflict of interest(s)

Authors declared no conflict of interest(s).

Streszczenie

Od publikacji pierwszego doniesienia o przezskórnym usunięciu śródnaczyniowego ciała obcego w 1964 roku metoda ta jest najczęściej wybieraną techniką w przypadku śródnaczyniowej lokalizacji ciała obcego. Dostępne instrumentarium do takich zabiegów obejmuje pętle, kleszczyki biopsyjne, koszyki typu dormia oraz przewodniki z giętką końcówką. W niniejszej pracy opisano przezskórne usunięcie przemieszczonego przewodnika z końcówką w kształcie „J” za pomocą pętli własnej konstrukcji. Kobieta w wieku 75 lat została przyjęta do placówki medycznej po nieudanej próbie usunięcia ciała obcego pozostającego po wszczepieniu stymulatora serca. Podczas wprowadzania czasowego stymulatora przypadkowo pozostawiono przewodnik z końcówką w kształcie „J” w żyłę głównej dolnej pacjentki. Przewodnik uchwycono za pomocą pętli własnej konstrukcji wprowadzonej przez prawą tętnicę podobojczykową, a następnie wydobyto bez powikłań. Dostępnych jest wiele publikacji opisujących wykorzystanie pętli do usuwania śródnaczyniowych ciał obcych jako metody skutecznej i cechującej się niskim odsetkiem powikłań. Niskie koszty tego rodzaju pętli sprawiają, że metoda ta jest nie tylko bezpieczna, ale i ekonomiczna.

Słowa kluczowe: śródnaczyniowe ciało obce, przewodnik z końcówką w kształcie J, przezskórne usunięcie, pętla własnej konstrukcji

Folia Cardiologica 2017; 12, 4: 371–374

References

1. Thomas J, Sinclair-Smith B, Bloomfield D. On-surgical retrieval of a broken segment of steel spring guide from the right atrium and inferior vena cava. *Circulation*. 1964; 30: 106–108, indexed in Pubmed: [14197828](#).
2. Sheth R, Someshwar V, Warawdekar G. Percutaneous retrieval of misplaced intravascular foreign objects with the Dormia basket: an effective solution. *Cardiovasc Intervent Radiol*. 2007; 30(1): 48–53, doi: [10.1007/s00270-005-0297-4](#), indexed in Pubmed: [17031735](#).
3. Dotter CT, Rösch J, Bilbao MK. Transluminal extraction of catheter and guide fragments from the heart and great vessels; 29 collected cases. *Am J Roentgenol Radium Ther Nucl Med*. 1971; 111(3): 467–472, indexed in Pubmed: [5548746](#).
4. Curry JL. Recovery of detached intravascular catheter or guide wire fragments. A proposed method. *Am J Roentgenol Radium Ther Nucl Med*. 1969; 105(4): 894–896, indexed in Pubmed: [5803618](#).
5. Kim JY, Yoon J, Jung HS, et al. Broken guidewire fragment in the radio-brachial artery during transradial sheath placement: percutaneous retrieval via femoral approach. *Yonsei Med J*. 2005; 46(1): 166–168, doi: [10.3349/ymj.2005.46.1.166](#), indexed in Pubmed: [15744822](#).
6. Gabelmann A, Kramer S, Gorich J. Percutaneous retrieval of lost or misplaced intravascular objects. *AJR Am J Roentgenol*. 2001; 176(6): 1509–1513, doi: [10.2214/ajr.176.6.1761509](#), indexed in Pubmed: [11373221](#).
7. Doering RB, Stemmer EA, Connolly JE. Complications of indwelling venous catheters, with particular reference to catheter embolus. *Am J Surg*. 1967; 114(2): 259–266, indexed in Pubmed: [6028989](#).
8. Dondelinger RF, Lepoutre B, Kurdziel JC. Percutaneous vascular foreign body retrieval: experience of an 11-year period. *Eur J Radiol*. 1991; 12(1): 4–10, indexed in Pubmed: [1999209](#).