

CLINICAL VIGNETTE

Endokrynologia Polska
DOI: 10.5603/EPa2019.0052
Volume/Tom 70; Number/Numer 6/2019
ISSN 0423-104X

Liver transplantation as an option of treatment for a giant primary hepatic neuroendocrine tumour

Grzegorz Oczkowicz¹, Artur Caban¹, Anna Zemczak², Jolanta Kunikowska³, Beata Kos-Kudła², Robert Król¹

¹Department of General, Vascular and Transplant Surgery, Medical University of Silesia, Katowice, Poland

²Department of Endocrinology and Neuroendocrine Tumours, Department of Pathophysiology and Endocrinology, Medical University of Silesia, Katowice, Poland

³Nuclear Medicine Department, Medical University of Warsaw, Warsaw, Poland

Abstract

There are no clear guidelines for the treatment of hepatic neuroendocrine tumours. Surgical resections — though rarely radical — seem to be the treatment of choice. Thermoablation, chemoembolisation, or cytoreductive surgery of hepatic focal lesions are often recommended. Pharmacological treatment is based on somatostatin analogues. Liver transplantation is available for a strictly selected group of patients with hepatic neuroendocrine tumours [5]. In the case described above, there were a number of factors that affected the decision about eligibility: first of all — very slow growth of the tumour, its size, and typical multifocality, which made it impossible to perform resection, lack of neoplastic focus outside the liver, and low Ki-67 proliferation index of $\leq 2\%$. The surgical risk was escalated due to the giant tumour mass and the laparotomy, which was performed twice. (*Endokrynol Pol* 2019; 70 (6): 520–521)

Key words: oncology; neuroendocrine tumour; liver transplantation

Introduction

Primary hepatic neuroendocrine tumours (PHNETs) are very rare. They constitute only 0.3% of all hepatic neuroendocrine tumours. The first report of a case of PHNET was provided by Edmondson in 1968 [1]. Until today, there have been approximately 150 cases described in the literature. PHNETs are tumours hard in their structure and clinically aggressive; they impair both the anatomy and function of the liver. The first symptoms are often the result of mass effect. PHNETs can be characterised with multifocality and very often lack of hormonal function activity. They are different from other neuroendocrine tumours due to their asymptomatic and slow growth [2]. Primary hepatic neuroendocrine tumours may resemble hepatocellular carcinoma or metastatic lesions in CT imaging. Histopathological assessment including positive synaptophysin (Syn) immunostaining and neuron-specific enolase are said to be a decisive diagnostic procedure. Long post-operative observation, with no primary sites identified in imaging, is crucial for the acknowledgment of a formal diagnosis [3].


There are no clear guidelines for treatment of PHNETs. Resection is deemed to be the first-line treatment. Systemic chemotherapy, radiotherapy, or transarterial

chemoembolisation (TACE) fail to prolong the life of a patient [4]. Orthotopic liver transplantation is occasionally applied.

Case study

In February 2008, in a 54-year-old female patient, who failed to report significant complaints, numerous hepatic tumour-like and fluid-filled lesions were incidentally identified in ultrasound imaging, with the largest lesion having the diameter of 18 cm. Endoscopic and imaging examinations showed no primary site. The patient underwent laparotomy, which resulted in the conclusion that the lesions were non-resectable. The metastasis of *adenocarcinoma mucocellulare* was diagnosed in a histopathological test performed on the basis of the collected tissue samples. The patient was given six cycles of palliative chemotherapy (5-fluorouracil and leucovorin), which was concluded in December 2008. No improvement was achieved, and due to intensified side effects, the patient refused to be treated any further.

The follow-up contrast-enhanced CT scan showed continued growth of tumour-like lesions in the liver. After seven years, because the patient's status was stable, a decision was made that relaparotomy was necessary

 Grzegorz Oczkowicz, Department of General, Vascular, and Transplant Surgery, Medical University of Silesia, Franuska 20–24, 40–027 Katowice, Poland; oczkowicz@hot.pl

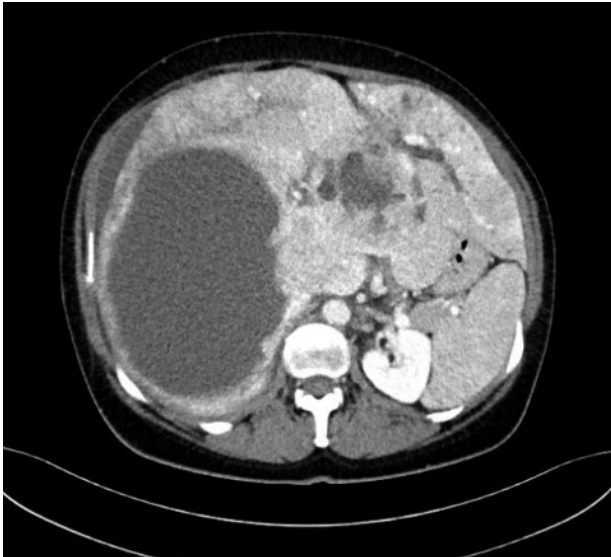


Figure 1. CT scan with a dominant tumour of the right hepatic lobe

and that the histopathological diagnosis should be verified. The patient lost 30 kg of body mass. On the basis of immunochemistry [chromatogranin (+), Syn (+), TTF-1 negative], well-differentiated endocrine tumour was diagnosed (Ki-67 index $\leq 2\%$). Somatostatin receptor (SSR) scintigraphy proved overexpression in the right hepatic tumour.

In the face of this new diagnosis, stable general status, and the giant mass of the tumour, an initial decision that the patient was eligible for liver transplantation was taken. Upon deciding on her eligibility at the transplantation clinical hospital, the patient presented benign ascites. The degree of liver failure was assessed to be 9, in accordance with model of end-stage liver disease (MELD) and 6 in accordance with the Child-Pugh score. Levels were as follows: bilirubin — 0.66 mg%, creatinine — 1.17mg%, INR — 1.3, and albumin concentration — 4.40 g/L. The liver mass was estimated to be approx. 10 kg in CT scan (Fig. 1). Orthotopic liver transplantation was performed with a traditional technique and with use of a veno-venous pump in November 2016. The surgery took more than seven hours. The ‘leading tumour’, having a diameter of 35 cm, was identified in the right lobe of the removed liver. The initial diagnosis was confirmed by histopathological examination. No surgical complications occurred after the procedure. Immunosuppressive therapy was administered based on a three-drug regimen: tacrolimus, mycophenolate mofetil, and prednisone. Until now, the patient has not been diagnosed with a relapse. Follow-up PET/CT scan with ^{68}Ga -DOTATATE revealed normal uptake without places of pathological expression of SSR (Fig. 2).

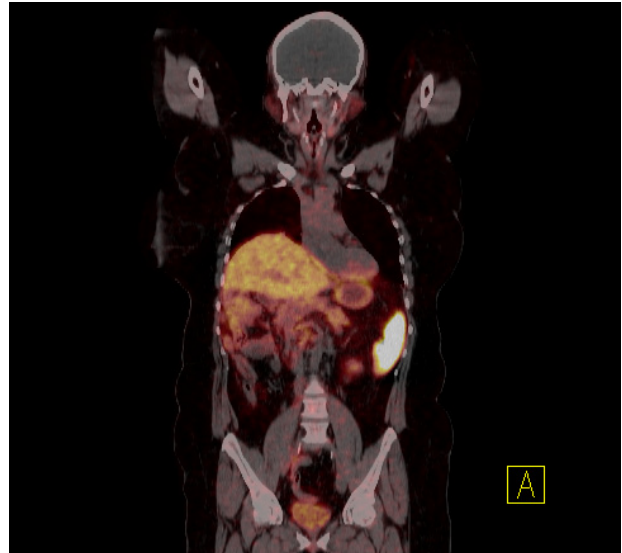


Figure 2. ^{68}Ga -DOTATATE PET/CT scan. The examination revealed normal distribution without pathological somatostatin expression

Conclusion

There are no clear guidelines for the treatment of hepatic neuroendocrine tumours. Surgical resections — though rarely radical — seem to be the treatment of choice. Thermoablation, chemoembolisation, or cytoreductive surgery of hepatic focal lesions are often recommended. Pharmacological treatment is based on somatostatin analogues. Liver transplantation is available for a strictly selected group of patients with hepatic neuroendocrine tumours [5]. In the case described above, there were a number of factors that affected the decision about eligibility: first of all — very slow growth of the tumour, its size, and typical multifocality, which made it impossible to perform resection, lack of neoplastic focus outside the liver, and low Ki-67 proliferation index of $\leq 2\%$. The surgical risk was escalated due to the giant tumour mass and the laparotomy, which was performed twice.

References

1. Scheuer P. Tumors of the Liver and Intrahepatic Bile Ducts. *J Clin Pathol.* 1990; 43(9): 786–786, doi: [10.1136/jcp.43.9.786-d](https://doi.org/10.1136/jcp.43.9.786-d).
2. Song JE, Kim BS, Lee CH. Primary hepatic neuroendocrine tumor: A case report and literature review. *World J Clin Cases.* 2016; 4(8): 243–247, doi: [10.12998/wjcc.v4.i8.243](https://doi.org/10.12998/wjcc.v4.i8.243), indexed in Pubmed: 27574614.
3. Cha DIk, Kang TW, Jang KM, et al. Hepatic neuroendocrine tumors: gadoxetic acid-enhanced magnetic resonance imaging findings with an emphasis on differentiation between primary and secondary tumors. *Abdom Radiol (NY).* 2018; 43(12): 3331–3339, doi: [10.1007/s00261-018-1653-6](https://doi.org/10.1007/s00261-018-1653-6), indexed in Pubmed: 29858937.
4. Zhao ZM, Wang J, Uguwo UC, et al. Primary hepatic neuroendocrine carcinoma: report of two cases and literature review. *BMC Clin Pathol.* 2018; 18: 3, doi: [10.1186/s12907-018-0070-7](https://doi.org/10.1186/s12907-018-0070-7), indexed in Pubmed: 29507528.
5. Bonaccorsi-Riani E, Apestegui C, Jouret-Mourin A, et al. Liver transplantation and neuroendocrine tumors: lessons from a single centre experience and from the literature review. *Transpl Int.* 2010; 23(7): 668–678, doi: [10.1111/j.1432-2277.2010.01086.x](https://doi.org/10.1111/j.1432-2277.2010.01086.x), indexed in Pubmed: 20478000.