



Temozolomide therapy for aggressive pituitary Crooke's cell corticotropinoma causing Cushing's Disease — a case report with literature review

Terapia temozolomidem agresywnego guza korykotropowego przysadki z komórek Crooke'a będącego przyczyną choroby Cushinga — opis przypadku i przegląd piśmiennictwa

Aleksandra Gilis-Januszewska^{1, 2}, Małgorzata Wilusz², Jacek Pantofliński², Renata Turek-Jabrocka^{1, 2}, Grzegorz Sokołowski², Anna Sowa-Staszczak^{1, 2}, Łukasz Kluczyński^{1, 2}, Dorota Pach^{1, 2}, Grzegorz Zieliński³, Alicja Hubalewska-Dydejczyk^{1, 2}

¹Department of Endocrinology, Jagiellonian University, Krakow, Poland

²University Hospital, Krakow, Poland

³Department of Neurosurgery, Military Medical Institute, Warsaw, Poland

Abstract

Introduction: Aggressive pituitary tumours causing Cushing's Disease are very rare, difficult to treat, and usually resistant to conventional therapy. There is growing evidence for the use of temozolomide (TMZ), an alkylating chemotherapeutic agent, as first-line chemotherapy in such tumours.

Objective: To present the response to TMZ in an aggressive pituitary tumour and Cushing's Disease and to review the literature referring to similar cases.

Case report: A sixty-one-year-old male patient was diagnosed with Cushing's Disease and invasive macroadenoma in 2011. Four transphenoidal non-radical neurosurgeries (2012, 2013) with rapid tumour progression, repeated non-radical bilateral adrenalectomy (2012, 2013) and stereotactic radiotherapy, and gamma knife surgery (2013, 2015) were performed. Histopathological examination revealed macroadenoma with high cell polymorphism and the presence of Crooke's cells, Ki-67 < 2%. Since 2015 the patient has been treated with six cycles of TMZ with clinical and biochemical improvement and stabilised tumour size and no side effects. TMZ was continued for up to nine cycles; however, symptoms like headaches, visual field impairment, and hearing loss were progressing. After the ninth cycle of TMZ, there was a sudden increase in the size of the tumour with deterioration of the clinical status. The patient died in February 2016.

Conclusions: The case of our patient suggests that the response to the TMZ treatment monotherapy in an aggressive pituitary tumour causing Cushing's Disease could be partial, followed by rapid progression of the tumour mass. Further research should be carried out to investigate predictors of responsiveness and to extend duration of TMZ treatment. (*Endokrynol Pol* 2018; 69 (3): 306–312)

Key words: aggressive pituitary tumours, Cushing's Disease, treatment, temozolomide

Streszczenie

Wstęp: Agresywne guzy przysadki powodujące chorobę Cushinga występują bardzo rzadko, są trudne do leczenia i zazwyczaj odporne na terapię konwencjonalną. Istnieje coraz więcej dowodów na zastosowanie temozolomidu (TMZ), alkilującego środka chemioterapeutycznego, jako chemioterapii pierwszej linii w tego rodzaju guzach.

Cel: Zaprezentowanie odpowiedzi na leczenie TMZ w przypadku agresywnego guza przysadki i choroby Cushinga oraz przegląd piśmiennictwa odnoszącego się do podobnych przypadków.

Opis przypadku: Mężczyzna w wieku 61 lat, ze zdiagnozowaną od 2011 roku chorobą Cushinga i inwazyjnym makrogruczolakiem. Przeprowadzono następujące zabiegi: cztery transfenoidalne nieradykalne zabiegi neurochirurgiczne (2012, 2013 r.) z szybko postępującym guzem, powtarzaną nieradykalną obustronną adrenalectomię (2012, 2013 r.) oraz radioterapię stereotaktyczną i zabieg nożem gamma (2013, 2015 r.). Badanie histopatologiczne wykazało obecność makrogruczolaka z wysokim stopniem polimorfizmu komórkowego oraz obecność komórek Crooke'a, Ki-67 < 2%. Od 2015 roku pacjent przeżył sześć cykli leczenia TMZ z poprawą parametrów klinicznych i biochemicznych, z ustabilizowaną wielkością guza i brakiem efektów ubocznych. Leczenie TMZ kontynuowane było do dziewięciu cykli, jednak objawy, takie jak bóle głowy, zaburzenia pola widzenia oraz utrata słuchu postępowały. Po zakończeniu dziewiątego cyklu leczenia TMZ nastąpił nagły wzrost wielkości guza razem z pogorszeniem stanu klinicznego. Pacjent zmarł w lutym 2016 roku.

Wnioski: Przykład opisywanego pacjenta może sugerować, że odpowiedź na monoterapię TMZ w przebiegu agresywnego guza przysadki powodującego chorobę Cushinga może być częściowa, z następującym później szybkim wzrostem masy guza. Wskazane jest prowadzenie dalszych badań, aby przeanalizować czynniki mające wpływ na odpowiedź oraz wydłużyć czas trwania leczenia TMZ. (*Endokrynol Pol* 2018; 69 (3): 306–312)

Słowa kluczowe: agresywne guzy przysadki, choroba Cushinga, leczenie, temozolomid



Aleksandra Gilis-Januszewska, Department of Endocrinology, Jagiellonian University, Krakow, Poland,
e-mail: myjanusz@cyf-kr.edu.pl

Abbreviations

TMZ — temozolomide
 ACTH — adrenocorticotrophic hormone
 PRL — prolactin
 TSH — thyroid-stimulating hormone
 FSH — follicle-stimulating hormone
 LH — luteinising hormone
 ESE — European Society of Endocrinology
 MGMT — O6-methyl-guanine-DNA methyltransferase
 MMMRI — magnetic resonance imaging
 CAPTEM — capecitabine and temozolomide
 PPRT — peptide receptor radionuclide therapy
 PET-CT — positron emission tomography-computed tomography
 European Society of Endocrinology

Introduction

The prevalence of clinically relevant pituitary tumours is 80–100 cases per 100,000 with an annual incidence of one new case per 100,000 [1–3]. Some of the pituitary tumours could remain clinically silent for a long time as many grow slowly over several years. However, some pituitary tumours present as aggressive with rapid growth. They are usually invasive macroadenomas with a high recurrence rate, resistant to repeated treatments [1–4]. There is no clear definition of aggressive pituitary tumours. Therefore, the European Society of Endocrinology (ESE) is currently preparing guidelines for the diagnosis and management of aggressive pituitary tumours (www.ese-hormones.org/). Also, little is known about the prevalence and treatment effectiveness of aggressive pituitary tumours causing Cushing's Disease. The management of aggressive pituitary tumours is a multidisciplinary challenge to clinicians with neurosurgery as a first-line treatment followed by radiotherapy and pharmacotherapy. There is growing evidence for the use of temozolomide (TMZ) monotherapy as first-line chemotherapy. In 2017 Halevy and Whitelaw published a review of the literature regarding the effectiveness of TMZ in pituitary tumour treatment [4].

Temozolomide (TMZ) is an alkylating cytostatic drug, used initially for the treatment of glioblastoma multiforme, but shown to be effective also in other central nervous system neoplasms. Recently it has been used in the treatment of aggressive pituitary adenomas. Temozolomide causes DNA damage through methylation of the O6 position of guanine, creating the cytotoxic DNA adducts, apoptosis of target cells, and cell necrosis, and consequently decreases tumour volume [5–8].

Aggressive pituitary tumours secreting ACTH are a rare type of corticotropinoma, which demonstrate invasive growth, high recurrence rate, and are resistant to conventional therapy [7]. Less than 1% of all pituitary

adenomas are built with Crooke's cells and only about 4.4–14% of corticotropinomas contain Crooke's cells. To date, there are only about 80 described cases of Crooke's cell adenoma [9, 10].

Case presentation

We present a case of a patient with ACTH-dependent Cushing's syndrome caused by Crooke's cell corticotropinoma. A 61-year-old male patient was referred to our clinic in December 2011. During the first hospitalisation the patient presented with signs and symptoms of severe hypercorticism and an excess ACTH level (abdominal obesity, moon face, hyperpigmentation of the skin, supraclavicular fat and dorsocervical fat pads [buffalo hump], purple striae, easy bruising, depression, swelling of feet, diabetes mellitus, hypertension). The patient suffered from advanced heart failure, severe headaches, and progressing visual field impairment. Progressing symptoms of the disease were present for 2–3 years before diagnosis. We observed advanced osteoporosis in the DEXA scan examination and a fracture of the Th5 vertebra in the X-ray examination. In 2011 the patient also underwent a neurosurgical intervention of the spine (L5-S1).

Upon admission, the laboratory tests revealed: morning ACTH level — 192.6 pg/mL, mean serum cortisol level 30.81 µg/d, and a lack of suppression serum cortisol after the administration of two-day low- and high-dose dexamethasone. Magnetic resonance imaging (MRI) showed a 33 × 29 × 26-mm mass with suprasellar extension, right cavernous sinus invasion, and a moved right carotid artery. The tumour mass elevated the optic chiasm. The abdominal ultrasound was non-significant. The patient was referred to the Department of Neurosurgery, where transsphenoidal surgery was performed (January 2012). Histopathological examination revealed a macroadenoma with high cell polymorphism and the presence of Crooke's cells, Ki-67 < 2%; immunohistochemistry was positive for ACTH and negative for other pituitary hormones (growth hormone, PRL, TSH, FSH, LH). Due to refractory signs and symptoms of severe hypercorticism, in 2012 and 2013, the patient was qualified for bilateral adrenalectomy for life-saving indications with post-operative fast recurrence of hypercorticism. Due to tumour regrowth, another three transsphenoidal non-radical neurosurgeries were performed (2012 and 2013). Repeated stereotactic radiotherapy (Dc 50.4 Gy and Dc 18 Gy, CyberKnife) was performed (August 2013 and April 2015) (Table I). From the time of diagnosis, the patient had been treated with ketoconazole (300 to 600 mg per day). The treatment was modified several times due to the exacerbation

Table I. Chronology of the treatments implemented in the patient**Tabela I. Zabiegi przeprowadzone u pacjenta, w kolejności chronologicznej**

The management	Date
1 st transsphenoidal Non-radical neurosurgery	05.01.2012
Non-radical left adrenalectomy	27.04.2012
Right adrenalectomy	21.05.2012
2 nd transsphenoidal Non-radical neurosurgery	19.06.2012
3 rd transsphenoidal Non-radical neurosurgery	08.10.2012
Left adrenalectomy	28.02.2013
4 th transsphenoidal Non-radical neurosurgery	19.04.2013
Stereotactic radiotherapy	08.2013
Stereotactic radiotherapy	04.2015
9 cycles of temozolomide therapy	04–12. 2015
Pasireotide treatment	01–02.2016

of hypercorticism and the observed deterioration of liver function.

The clinical status of the patient gradually worsened with the progression of severe cardiac insufficiency. The patient was not qualified for another gamma-knife surgery; the patient suffered from severe headaches and right oculomotor nerve paresis. Deterioration of the visual field was also observed.

Based on the above, we decided to start treatment with temozolomide. The first course was initiated in April 2015. We administered a standard dose of TMZ, widely used for malignant glioma (150–200 mg/m²) once daily in the morning, for five consecutive days (28-day cycle). From the beginning of the diagnosis the patient was continuously treated with ketoconazole (average dose 600 mg). Since 2015 he was treated with six cycles of TMZ (320 mg per day for five consecutive days (28-day cycle). Clinical and biochemical improvement was observed. During the third cycle, morning cortisol and ACTH decreased by 17% and 40%, respectively, compared to baseline measurement (April 2015) (Table II). The maximal decrease of morning cortisol and ACTH with clinical improvement was observed after the seventh cycle (decrease by 52% and 56%, respectively, compared to baseline measurement) (Table II, Figure 1). Clinical improvement manifested from the third cycle with less frequent and less severe headaches, improved right oculomotor nerve paresis, improvement of the visual field, and improved physical fitness and mood. Clinical and cardiographic improvement of heart insufficiency was also seen. In the control MRI (July 2015) the size of the tumour was the same as in the previous MRI examination (30 × 35 × 35 mm). We continued the treatment to the ninth cycle and observed a stable

Table II. Serum cortisol [$\mu\text{g/dL}$] and ACTH levels [pg/mL] measured before the TMZ cycle and after discontinuation of the treatment**Tabela II. Wartości stężenia kortyzolu w surowicy krwi [$\mu\text{g/dL}$] oraz stężenie ACTH [pg/mL], mierzone przed cyklem leczenia TMZ**

DATE	Before cycle	Serum cortisol level [$\mu\text{g/dL}$]*		ACTH [pg/mL]**
		8 am	12 pm	
24.04.2015	1 st cycle	36.2	35.6	1317
27.05.2015	2 nd cycle	29.4	19.53	1108
24.06.2015	3 rd cycle	30	28	785
22.07.2015	4 th cycle	39.1	35.8	1057
20.08.2015	5 th cycle	30.95	27.2	840
17.09.2015	6 th cycle	24.1	26.3	689
15.10.2015	7 th cycle	17.3	19.91	572
16.11.2015	8 th cycle	20.66	16.1	957
17.12.2015	9 th cycle	29.4	25.61	779
14.01.2016	Post***	22.03	22.58	769
05.02.2016	Post***	21.02	16.22	1080

*serum cortisol normal range [2.30–23.30 $\mu\text{g/dL}$]

**serum ACTH range [6.0–56.0 pg/mL]

***measurements performed after temozolomide discontinuation

decrease and stabilisation in the level of cortisol and ACTH during the consecutive cycles. However, the clinical symptoms such as the headaches, visual field impairment, and finally hearing loss started to progress from the eighth cycle (December 2016). After the ninth cycle of TMZ, in December 2015, there was a sudden increase in the size of the tumour to 35 × 53 × 54 mm, while the cortisol and ACTH levels remained stable. The tumour reached the inner ear with visible compression on the cochlea. In February 2016, one month after discontinuation of TMZ, the cortisol serum level remained stable while ACTH increased by 28% when compared to a measurement from January 2016 (Table II). After discontinuation of TMZ, we observed the progressing impairment of the patient's clinical status with a sudden clinical status crisis: sight deterioration, strong headache, right oculomotor nerve paresis, and hearing loss. Progressive hearing loss was observed from the eighth/ninth cycle. We decided to start treatment with Pasireotide (0.6 mg s.c twice a day). After the implementation of the drug, a rapid deterioration of diabetes was observed. The patient died in February 2015. The most probable reason for death was compression of the brainstem, which had been observed in the last MRI of the pituitary (Figure 2 and 3).

Haematological parameters, liver function tests, and careful clinical observation were performed periodically. To prevent possible side effects, the patient received

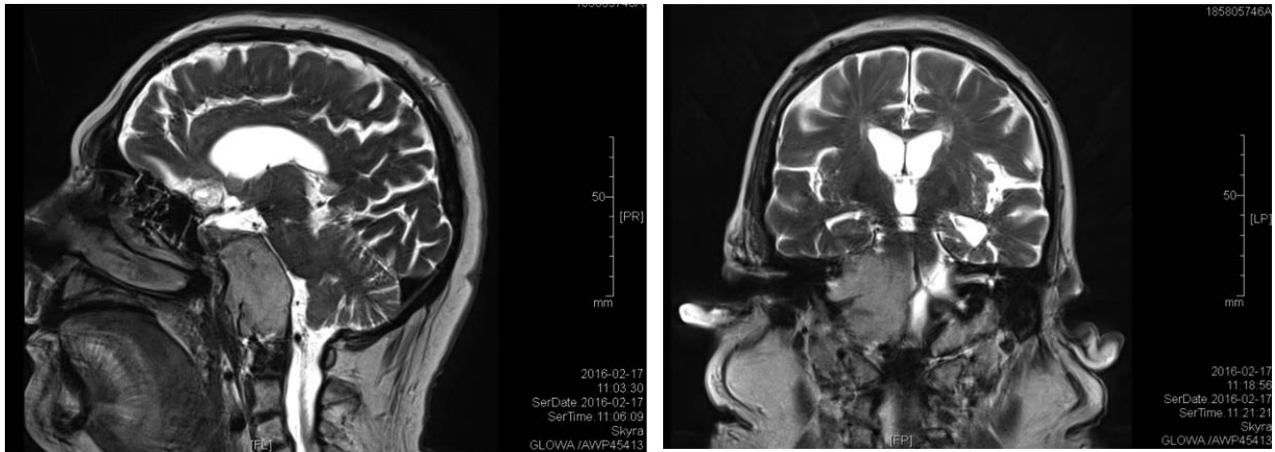


Figure 1 and 2. MRI of the pituitary, February 2016
Rycina 1, 2. MRI przysadki mózgowej, luty 2016

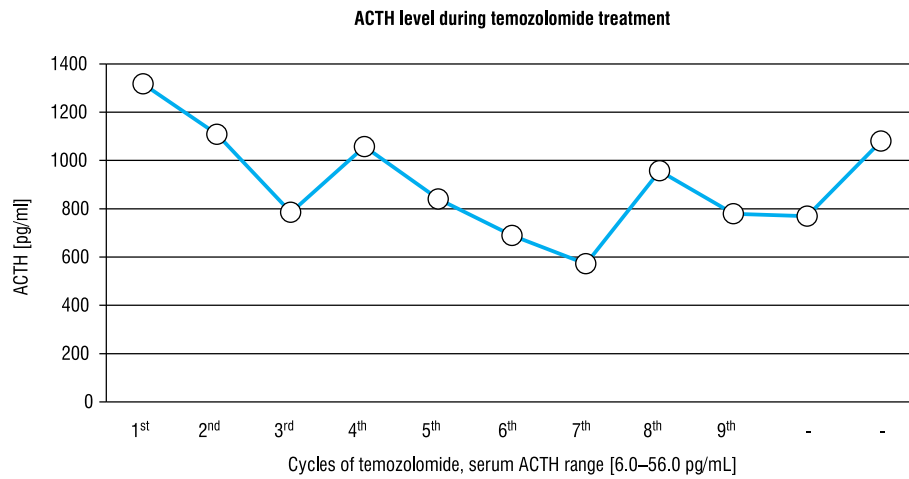


Figure 2. ACTH [pg/mL] during temozolomide treatment and after treatment discontinuation
Rycina 2. Lortykotropina (ACTH) [pg/ml] podczas leczenia temozolomidem oraz po zaprzestaniu leczenia

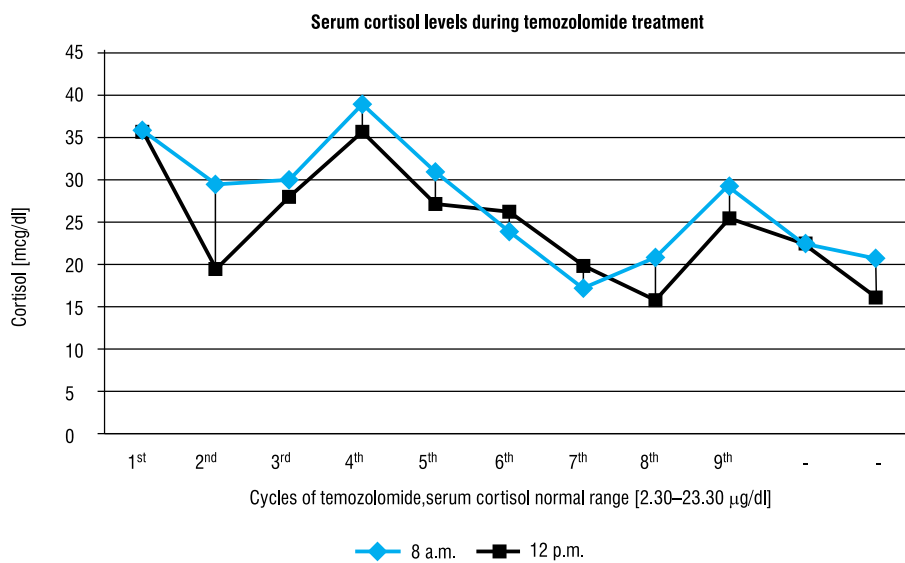


Figure 3. Serum cortisol levels during 9 cycles of temozolomide treatment and after treatment discontinuation
Rycina 3. Wartości stężenia kortyzolu w surowicy krwi podczas dziewięciu cykli leczenia temozolomidem oraz po zaprzestaniu leczenia

ondansetron and trimethoprim-sulfamethoxazole. Apart from mild nausea, we did not observe any common adverse effects during treatment.

Discussion

In our case, a patient with an aggressive pituitary corticotroph tumour with severe clinical symptoms of Cushing's Disease, resistant to repeated neurosurgery, bilateral adrenalectomy, and radiotherapy, improved after the implementation of TMZ. Serum cortisol and ACTH levels significantly decreased and were stable up to the ninth cycle, while the clinical progression of symptoms due to tumour mass effects were present from the eighth cycle. We did not observe any typical TMZ side effects, except for mild nausea and progressive hearing loss from the eighth/ninth cycle. The treatment was continued for nine cycles. During the ninth cycle sudden clinical deterioration and rapid tumour growth were observed.

Similarly to our case, aggressive pituitary tumours usually respond badly to standard medical treatments. The first-line treatment of aggressive pituitary tumours is neurosurgery; however, in about 35% of patients we observe regrowth with median follow-up of regrowth by 5.9 years [11].

Radiotherapy is usually the third-line treatment. Unlike repeated operations that can be considered in suitable patients, radiation treatment is limited by the risk of necrosis of the brain cells and a high risk of pituitary dysfunction. Radiotherapy is frequently ineffective and thus the search for other therapeutic options has been carried out [10, 12]. Our experience with TMZ treatment comes from the studies on glioblastoma multiforme, followed by the first use of the medication in aggressive pituitary tumours in 2006 [13, 14]. These reports were quickly followed by a number of case reports and a few studies on a series of patients. According to a review by Halevy and Whitelaw published in 2017, the overall response rate was 45% with a further 27% reporting stable disease [4]. In a series of 24 patients, Bengtsson et al. reported a 46% response to the treatment: three patients having undergone a complete response, nine complete tumour regression, and in eight patients a partial regression was observed [15]. TMZ therapy resulted in stabilising the disease (total remission, partial remission, or lack of progression) in more than 60% of patients [4, 15–17]. Clinically functional tumours responded better than non-functioning ones, with up to a 50% response rate in prolactinomas and corticotroph tumours [4, 15–17]. The results of the studies might be related to publication bias. The published studies are difficult to compare due to different durations of treatment, follow-up, and different protocols used. There is

also a probability of reporting mostly positive results, or results with short follow-up. According to Halevy et al., the response is usually seen within three cycles [4]. An absence of response after three cycles might predict resistance to the treatment, as suggested by Raverot et al. [4, 7]. The mean treatment duration in published series was 9–12 months [4]. Our patient, similarly to other cases with corticotropinoma aggressive tumours, had rapid tumour progression after transsphenoidal neurosurgeries, all non-radical due to the size of the tumour and invasive growth with infiltration of the clivus, suprasellar region, cavernous sinus, carotid arteries, and optic chiasm. Also, repeated bilateral adrenalectomy was not radical, performed as 'life saving' in the course of severe hypocortisolism. Stereotactic radiotherapy and gamma knife surgery were also ineffective. We observed clinical and biochemical response after TMZ implementation from the third course up to the 7–8th course of therapy with stabilised tumour size assessed after the third cycle. However, clinical symptoms of tumour mass effect like headaches, visual field impairment, and finally hearing loss started to progress from the 7–8th cycle. A similar case of invasive corticotroph adenoma (Crooke's cell corticotropinoma with MIB-1 index < 1) resistant to standard therapy treated with temozolomide was described by Kurowska et al. in 2016 [18]. In that case the authors achieved long-term (33-month) complete remission after TMZ treatment [18]. After six courses of standard TMZ therapy tumour regression was observed, and nine courses resulted in a total radiological tumour shrinkage and hormonal normalisation [18]. In another case of invasive corticotroph adenoma (a patient with Nelson Syndrome after bilateral adrenalectomy) resistant to standard therapy treated with TMZ, tumour volume reduction was about 20% after three cycles with TMZ with a decrease in ACTH level [19]. The patient received nine cycles of TMZ without the progression of the disease and with a stable volume of the tumour. However, after TMZ withdrawal and remission during a six-month follow-up tumour progression was observed [19].

Significant tumour shrinkage with decreased hormone secretion was also reported by Raverot et al. in two of five patients with pituitary carcinoma (one with ACTH- and another with PRL-secreting carcinoma) [7]. Moyes et al. presented a case of a patient with an aggressive corticotroph adenoma with significant clinical improvement, reduction of serum plasma ACTH from 2472 to 389 pmol/L (about 84%), and regression of tumour in NMR after four cycles of TMZ treatment [20]. Curto et al. also described a case report of a patient with an ACTH-secreting carcinoma, in whom TMZ therapy induced dramatic tumour size reduction (> 90%) [21].

There are also suggested biochemical markers of TMZ responsiveness that were not analysed in our case. O6-methyl-guanine-DNA methyltransferase (MGMT) is a DNA repair protein that reverses alkylation at the O6 position of guanine by transferring the alkyl group to a sulphur group of cysteine, removing the alkylating adducts induced by TMZ treatment, and providing resistance to TMZ. The effectiveness of TMZ is suggested to be related to the down-expression of O6-methylguanine-DNA methyltransferase (MGMT) [22].

According to Lau et al. [23] and others, high MGMT expression is suggestive of a lack of response to TMZ.

DNA mismatch repair protein (MSH6) also correlated with the responses of atypical pituitary adenomas and pituitary carcinomas to temozolomide. In a Japanese study Hirohata T et al. [24] showed that preserving MSH6 function was contributory to the effectiveness of TMZ in malignant pituitary neoplasms.

Side effects

Temozolomide (TMZ) is characterised by good tolerability and low toxicity. Most information regarding side effects comes from experience in the treatment of gliomas. The most common adverse effects of TMZ were quoted in the description made by the producer of TMZ. They are the following: fatigue, nausea/vomiting, headache, constipation, anorexia, hemiparesis, diarrhoea, fever, dizziness, viral infection, amnesia, insomnia, and haematological disorders. There is also evidence, although limited, of the side effects of TMZ in aggressive pituitary tumours. According to Bengtsson et al., in a series of 24 patients with aggressive pituitary tumours, adverse effects were reported in 54% cases, with most being mild [21]. Fatigue is the most common side effect of TMZ therapy (60% of patients) [25, 26], followed by myelosuppression (31%) and nausea/vomiting [26, 27]. In our case, we did not observe typical side effects of TMZ, but hearing loss started to progress from the eighth cycle. According to Zachary et al., in a cohort of seven patients treated with TMZ for aggressive pituitary tumours, in one case progressive bilateral sensorineural hearing loss was observed. The authors claimed that they had not seen hearing loss in a large group of patients with malignant gliomas treated with TMZ in their centre, but they could not exclude TMZ as the causative agent in this case [28]. In our case, an MRI examination revealed massive invasion of the inner ear with compression on the right cochlea, which could explain the hearing loss. Our patient initially had liver steatosis in the course of the disease. During the treatment with ketoconazole, a potentially hepatotoxic agent, we observed the deterioration of the liver function. In our case the additional implementation of TMZ had no impact on liver function. However, in several

cases TMZ caused liver function impairment ranging from mild to severe [29, 30].

We also obtained a full haematological profile at day 14 during standard 28-day TMZ dosing cycles. Haematological parameters and liver function tests were comparable with results before treatment. To prevent nausea and vomiting we used ondansetron during the five-day chemotherapy course. Our patient received prophylactic trimethoprim-sulfamethoxazole to prevent the risk of opportunistic infection, particularly *Pneumocystis pneumonia* (PCP), as suggested by Righi et al. [31].

Combination therapy and other treatment options

The last treatment we decided to use was a somatostatin analogue pasireotide. However, the evidence on the effectiveness of pasireotide in aggressive corticotroph tumours is very scarce. In a similar case of a patient with a large corticotroph tumour, following bilateral adrenalectomy, the lowering of ACTH (from 42710 pg/mL to 4272 pg/mL) and the sustained reduction of the suprasellar tumour after one month of therapy were observed, remaining stable over 19 months of follow-up [32]. In another eight patients with Nelson's syndrome, pasireotide had minimal effects on tumour volume; however, reductions in ACTH levels in most patients were observed. In our case, due to the very short duration of treatment, any conclusions on the treatment with pasireotide cannot be drawn. Regarding side effects, we observed rapid deterioration of diabetes mellitus after implementation of pasireotide.

To improve response rates of TMZ, combination treatments have been investigated. In a study with capecitabine given before TMZ (CAPTEM) a partial response of long duration in four out of four corticotroph tumours was observed [33]. In other studies, capecitabine had been added to TMZ after TMZ failure, or at progression after an initial response to TMZ alone, but with no enhanced effect observed [16, 25, 34].

Another promising therapeutic option, which is still not in use, is peptide receptor radionuclide therapy (PPRT) based on the assumption that pituitary uptake of ^{68}Ga -DOTATATE or other radiolabelled somatostatin analogues has been demonstrated in PET/CT of aggressive pituitary tumours [35, 36].

Conclusions

The results of the presented case suggest that TMZ treatment monotherapy could have only partial response in aggressive corticotroph adenoma causing Cushing Disease, followed by sudden progression, while in the literature review mostly responsive cases

were presented, albeit with different durations of response. Therefore, further research on the factors of responsiveness and on novel methods to extend the duration of the effect of TMZ should be carried out.

References

- Daly AF, Rixhon M, Adam C, et al. High prevalence of pituitary adenomas: a cross-sectional study in the province of Liege, Belgium. *J Clin Endocrinol Metab.* 2006; 91(12): 4769–4775, doi: [10.1210/jc.2006-1668](https://doi.org/10.1210/jc.2006-1668), indexed in Pubmed: [16968795](https://pubmed.ncbi.nlm.nih.gov/16968795/).
- Fernandez A, Karavitaki N, Wass JAH. Prevalence of pituitary adenomas: a community-based, cross-sectional study in Banbury (Oxfordshire, UK). *Clin Endocrinol (Oxf).* 2010; 72(3): 377–382, doi: [10.1111/j.1365-2265.2009.03667.x](https://doi.org/10.1111/j.1365-2265.2009.03667.x), indexed in Pubmed: [19650784](https://pubmed.ncbi.nlm.nih.gov/19650784/).
- Raappana A, Koivukangas J, Ebeling T, et al. Incidence of pituitary adenomas in Northern Finland in 1992–2007. *J Clin Endocrinol Metab.* 2010; 95(9): 4268–4275, doi: [10.1210/jc.2010-0537](https://doi.org/10.1210/jc.2010-0537), indexed in Pubmed: [20534753](https://pubmed.ncbi.nlm.nih.gov/20534753/).
- Halevy C, Whitelaw BC. How effective is temozolomide for treating pituitary tumours and when should it be used? *Pituitary.* 2017; 20(2): 261–266, doi: [10.1007/s11102-016-0745-y](https://doi.org/10.1007/s11102-016-0745-y), indexed in Pubmed: [27581836](https://pubmed.ncbi.nlm.nih.gov/27581836/).
- Fadul CE, Kominsky AL, Meyer LP, et al. Long-term response of pituitary carcinoma to temozolomide. Report of two cases. *J Neurosurg.* 2006; 105(4): 621–626, doi: [10.3171/jns.2006.105.4.621](https://doi.org/10.3171/jns.2006.105.4.621), indexed in Pubmed: [17044568](https://pubmed.ncbi.nlm.nih.gov/17044568/).
- Hagen C, Schroeder HD, Hansen S, et al. Temozolomide treatment of a pituitary carcinoma and two pituitary macroadenomas resistant to conventional therapy. *Eur J Endocrinol.* 2009; 161(4): 631–637, doi: [10.1530/EJE-09-0389](https://doi.org/10.1530/EJE-09-0389), indexed in Pubmed: [19654234](https://pubmed.ncbi.nlm.nih.gov/19654234/).
- Raverot G, Sturm N, de Fraipont F, et al. Temozolomide treatment in aggressive pituitary tumors and pituitary carcinomas: a French multicenter experience. *J Clin Endocrinol Metab.* 2010; 95(10): 4592–4599, doi: [10.1210/jc.2010-0644](https://doi.org/10.1210/jc.2010-0644), indexed in Pubmed: [20660056](https://pubmed.ncbi.nlm.nih.gov/20660056/).
- Syro LV, Ortiz LD, Scheithauer BW, et al. Treatment of pituitary neoplasms with temozolomide: a review. *Cancer.* 2011; 117(3): 454–462, doi: [10.1002/cncr.25413](https://doi.org/10.1002/cncr.25413), indexed in Pubmed: [20845485](https://pubmed.ncbi.nlm.nih.gov/20845485/).
- Di Ieva A, Davidson JM, Syro LV, et al. Crouke's cell tumors of the pituitary. *Neurosurgery.* 2015; 76(5): 616–622, doi: [10.1227/NEU.0000000000000657](https://doi.org/10.1227/NEU.0000000000000657), indexed in Pubmed: [25635886](https://pubmed.ncbi.nlm.nih.gov/25635886/).
- Burman P, van Beek AP, Biller BMK, et al. Radiotherapy, Especially at Young Age, Increases the Risk for De Novo Brain Tumors in Patients Treated for Pituitary/Sellar Lesions. *J Clin Endocrinol Metab.* 2017; 102(3): 1051–1058, doi: [10.1210/jc.2016-3402](https://doi.org/10.1210/jc.2016-3402), indexed in Pubmed: [28359095](https://pubmed.ncbi.nlm.nih.gov/28359095/).
- Tampourlou M, Ntali G, Ahmed S, et al. Outcome of Nonfunctioning Pituitary Adenomas That Regrow After Primary Treatment: A Study From Two Large UK Centers. *J Clin Endocrinol Metab.* 2017; 102(6): 1889–1897, doi: [10.1210/jc.2016-4061](https://doi.org/10.1210/jc.2016-4061), indexed in Pubmed: [28323946](https://pubmed.ncbi.nlm.nih.gov/28323946/).
- Ding D, Starke RM, Sheehan JP. Treatment paradigms for pituitary adenomas: defining the roles of radiosurgery and radiation therapy. *J Neurooncol.* 2014; 117(3): 445–457, doi: [10.1007/s11060-013-1262-8](https://doi.org/10.1007/s11060-013-1262-8), indexed in Pubmed: [24122025](https://pubmed.ncbi.nlm.nih.gov/24122025/).
- Fadul CE, Kominsky AL, Meyer LP, et al. Long-term response of pituitary carcinoma to temozolomide. Report of two cases. *J Neurosurg.* 2006; 105(4): 621–626, doi: [10.3171/jns.2006.105.4.621](https://doi.org/10.3171/jns.2006.105.4.621), indexed in Pubmed: [17044568](https://pubmed.ncbi.nlm.nih.gov/17044568/).
- Lim S, Shahinian H, Maya MM, et al. Temozolomide: a novel treatment for pituitary carcinoma. *Lancet Oncol.* 2006; 7(6): 518–520, doi: [10.1016/S1470-2045\(06\)70728-8](https://doi.org/10.1016/S1470-2045(06)70728-8), indexed in Pubmed: [16750503](https://pubmed.ncbi.nlm.nih.gov/16750503/).
- Zacharia BE, Gulati AP, Bruce JN, et al. High response rates and prolonged survival in patients with corticotroph pituitary tumors and refractory Cushing disease from capecitabine and temozolomide (CAPTEM): a case series. *Neurosurgery.* 2014; 74(4): E447–55; discussion E455, doi: [10.1227/NEU.0000000000000251](https://doi.org/10.1227/NEU.0000000000000251), indexed in Pubmed: [24226425](https://pubmed.ncbi.nlm.nih.gov/24226425/).
- Bruno OD, Juárez-Allen L, Christiansen SB, et al. Temozolomide Therapy for Aggressive Pituitary Tumors: Results in a Small Series of Patients from Argentina. *Int J Endocrinol.* 2015; 2015: 587893, doi: [10.1155/2015/587893](https://doi.org/10.1155/2015/587893), indexed in Pubmed: [26106414](https://pubmed.ncbi.nlm.nih.gov/26106414/).
- Hirohata T, Asano K, Ogawa Y, et al. DNA mismatch repair protein (MSH6) correlated with the responses of atypical pituitary adenomas and pituitary carcinomas to temozolomide: the national cooperative study by the Japan Society for Hypothalamic and Pituitary Tumors. *J Clin Endocrinol Metab.* 2013; 98(3): 1130–1136, doi: [10.1210/jc.2012-2924](https://doi.org/10.1210/jc.2012-2924), indexed in Pubmed: [23365123](https://pubmed.ncbi.nlm.nih.gov/23365123/).
- Kurowska M, Tarach JS, Malicka J, et al. Long-term complete remission of Crouke's corticotropinoma after temozolomide treatment. *Endokrynol Pol.* 2016; 67(5): 526–533, doi: [10.5603/EP.2016.0060](https://doi.org/10.5603/EP.2016.0060), indexed in Pubmed: [27828691](https://pubmed.ncbi.nlm.nih.gov/27828691/).
- Kurowska M, Nowakowski A, Zieliński G, et al. Temozolomide-Induced Shrinkage of Invasive Pituitary Adenoma in Patient with Nelson's Syndrome: A Case Report and Review of the Literature. *Case Rep Endocrinol.* 2015; 2015: 623092, doi: [10.1155/2015/623092](https://doi.org/10.1155/2015/623092), indexed in Pubmed: [26221547](https://pubmed.ncbi.nlm.nih.gov/26221547/).
- Moyes VJ, Alusi G, Sabin HI, et al. Treatment of Nelson's syndrome with temozolomide. *Eur J Endocrinol.* 2009; 160(1): 115–119, doi: [10.1530/EJE-08-0557](https://doi.org/10.1530/EJE-08-0557), indexed in Pubmed: [18984772](https://pubmed.ncbi.nlm.nih.gov/18984772/).
- Curtò L, Torre ML, Ferraù F, et al. Temozolomide-induced shrinkage of a pituitary carcinoma causing Cushing's disease—report of a case and literature review. *ScientificWorldJournal.* 2010; 10: 2132–2138, doi: [10.1100/tsw.2010.210](https://doi.org/10.1100/tsw.2010.210), indexed in Pubmed: [21057727](https://pubmed.ncbi.nlm.nih.gov/21057727/).
- Takeshita A, Inoshita N, Taguchi M, et al. High incidence of low O(6)-methylguanine DNA methyltransferase expression in invasive macroadenomas of Cushing's disease. *Eur J Endocrinol.* 2009; 161(4): 553–559, doi: [10.1530/EJE-09-0414](https://doi.org/10.1530/EJE-09-0414), indexed in Pubmed: [19589911](https://pubmed.ncbi.nlm.nih.gov/19589911/).
- Lau Q, Scheithauer B, Kovacs K, et al. MGMT immunoreexpression in aggressive pituitary adenoma and carcinoma. *Pituitary.* 2010; 13(4): 367–379, doi: [10.1007/s11102-010-0249-0](https://doi.org/10.1007/s11102-010-0249-0), indexed in Pubmed: [20740317](https://pubmed.ncbi.nlm.nih.gov/20740317/).
- Hirohata T, Asano K, Ogawa Y, et al. DNA mismatch repair protein (MSH6) correlated with the responses of atypical pituitary adenomas and pituitary carcinomas to temozolomide: the national cooperative study by the Japan Society for Hypothalamic and Pituitary Tumors. *J Clin Endocrinol Metab.* 2013; 98(3): 1130–1136, doi: [10.1210/jc.2012-2924](https://doi.org/10.1210/jc.2012-2924), indexed in Pubmed: [23365123](https://pubmed.ncbi.nlm.nih.gov/23365123/).
- Bengtsson D, Schrader HD, Andersen M, et al. Long-term outcome and MGMT as a predictive marker in 24 patients with atypical pituitary adenomas and pituitary carcinomas given treatment with temozolomide. *J Clin Endocrinol Metab.* 2015; 100(4): 1689–1698, doi: [10.1210/jc.2014-4350](https://doi.org/10.1210/jc.2014-4350), indexed in Pubmed: [25646794](https://pubmed.ncbi.nlm.nih.gov/25646794/).
- McCormack AL, Wass JAH, Grossman AB. Aggressive pituitary tumours: the role of temozolomide and the assessment of MGMT status. *Eur J Clin Invest.* 2011; 41(10): 1133–1148, doi: [10.1111/j.1365-2362.2011.02520.x](https://doi.org/10.1111/j.1365-2362.2011.02520.x), indexed in Pubmed: [21496012](https://pubmed.ncbi.nlm.nih.gov/21496012/).
- Danson SJ, Middleton MR. Temozolomide: a novel oral alkylating agent. *Expert Rev Anticancer Ther.* 2001; 1(1): 13–19, doi: [10.1586/14737140.1.1.13](https://doi.org/10.1586/14737140.1.1.13), indexed in Pubmed: [12113120](https://pubmed.ncbi.nlm.nih.gov/12113120/).
- Bush ZM, Longtine JA, Cunningham T, et al. Temozolomide treatment for aggressive pituitary tumors: correlation of clinical outcome with O(6)-methylguanine methyltransferase (MGMT) promoter methylation and expression. *J Clin Endocrinol Metab.* 2010; 95(11): E280–E290, doi: [10.1210/jc.2010-0441](https://doi.org/10.1210/jc.2010-0441), indexed in Pubmed: [20668043](https://pubmed.ncbi.nlm.nih.gov/20668043/).
- Losa M, Bogazzi F, Cannavo S, et al. Temozolomide therapy in patients with aggressive pituitary adenomas or carcinomas. *J Neurooncol.* 2016; 126(3): 519–525, doi: [10.1007/s11060-015-1991-y](https://doi.org/10.1007/s11060-015-1991-y), indexed in Pubmed: [26614517](https://pubmed.ncbi.nlm.nih.gov/26614517/).
- Trouillas J, Roy P, Sturm N, et al. members of HYPOPRONOS. A new prognostic clinicopathological classification of pituitary adenomas: a multicentric case-control study of 410 patients with 8 years post-operative follow-up. *Acta Neuropathol.* 2013; 126(1): 123–135, doi: [10.1007/s00401-013-1084-y](https://doi.org/10.1007/s00401-013-1084-y), indexed in Pubmed: [23400299](https://pubmed.ncbi.nlm.nih.gov/23400299/).
- Righi A, Agati P, Sisto A, et al. A classification tree approach for pituitary adenomas. *Hum Pathol.* 2012; 43(10): 1627–1637, doi: [10.1016/j.humpath.2011.12.003](https://doi.org/10.1016/j.humpath.2011.12.003), indexed in Pubmed: [22446019](https://pubmed.ncbi.nlm.nih.gov/22446019/).
- Katznelson L. Sustained improvements in plasma ACTH and clinical status in a patient with Nelson's syndrome treated with pasireotide LAR, a multireceptor somatostatin analog. *J Clin Endocrinol Metab.* 2013; 98(5): 1803–1807, doi: [10.1210/jc.2013-1497](https://doi.org/10.1210/jc.2013-1497), indexed in Pubmed: [23539733](https://pubmed.ncbi.nlm.nih.gov/23539733/).
- Raverot G, Sturm N, de Fraipont F, et al. Temozolomide treatment in aggressive pituitary tumors and pituitary carcinomas: a French multicenter experience. *J Clin Endocrinol Metab.* 2010; 95(10): 4592–4599, doi: [10.1210/jc.2010-0644](https://doi.org/10.1210/jc.2010-0644), indexed in Pubmed: [20660056](https://pubmed.ncbi.nlm.nih.gov/20660056/).
- Losa M, Bogazzi F, Cannavo S, et al. Temozolomide therapy in patients with aggressive pituitary adenomas or carcinomas. *J Neurooncol.* 2016; 126(3): 519–525, doi: [10.1007/s11060-015-1991-y](https://doi.org/10.1007/s11060-015-1991-y), indexed in Pubmed: [26614517](https://pubmed.ncbi.nlm.nih.gov/26614517/).
- Kuyumcu S, Özkan ZG, Sanli Y, et al. Physiological and tumoral uptake of (68)Ga-DOTATATE: standardized uptake values and challenges in interpretation. *Ann Nucl Med.* 2013; 27(6): 538–545, doi: [10.1007/s12149-013-0718-4](https://doi.org/10.1007/s12149-013-0718-4), indexed in Pubmed: [23543506](https://pubmed.ncbi.nlm.nih.gov/23543506/).
- Xiao J, Zhu Z, Zhong D, et al. Improvement in diagnosis of metastatic pituitary carcinoma by 68Ga DOTATATE PET/CT. *Clin Nucl Med.* 2015; 40(2): e129–e131, doi: [10.1097/RLU.0000000000000462](https://doi.org/10.1097/RLU.0000000000000462), indexed in Pubmed: [24873798](https://pubmed.ncbi.nlm.nih.gov/24873798/).