



Cerebellar metastasis of papillary thyroid carcinoma detected with somatostatin receptor scintigraphy

Przerzut do mózdzku raka brodawkowego tarczycy wykryty w scyntygrafii receptorów somatostatynowych

Rafał Czepczyński, Anna Wyszomirska, Maria Gryczyńska, Ewelina Szczepanek-Parulska, Marek Ruchała

Department of Endocrinology, Metabolism, and Internal Medicine, Poznan University of Medical Sciences, Poznan, Poland

Abstract

Introduction: Distant metastases of papillary thyroid carcinoma (PTC) may lack the ability to concentrate radioiodine. In such cases, positive somatostatin receptor scintigraphy might be useful in demonstrating the expression of somatostatin receptors that are potential therapeutic targets. To date, only a few cerebellar metastases from PTC have been reported in the literature.

Patient findings: We present an 82-year-old female, in whom an asymptomatic cerebellar metastasis from PTC was diagnosed by means of Tc-99m-EDDA/HYNIC-TOC scintigraphy four years after the initial diagnosis. She was previously treated with total thyroidectomy and regional lymph node dissection, followed by three cycles of radioiodine therapy. Despite persistently elevated thyroglobulin, no specific radioiodine accumulation was found in the whole body post-treatment scan. Tc-99m-EDDA/HYNIC-TOC scintiscan revealed foci of increased tracer uptake in the lungs, cervical lymph nodes, and a single focus in the head. Thus, therapy with octreotide LAR was initiated. The patient died four months later due to disseminated PTC.

Summary: In this paper, a patient with asymptomatic previously unknown non-iodine avid cerebellar metastasis of PTC diagnosed by means of scintigraphy using somatostatin analogue Tc-99m-EDDA/HYNIC-TOC is reported.

Conclusions: Somatostatin receptor scintigraphy might be useful in the visualisation of non-iodine avid PTC metastases and demonstrating the expression of somatostatin receptors that are potential therapeutic targets. (*Endokrynol Pol* 2018; 69 (1): 24–27)

Key words: differentiated thyroid carcinoma, papillary thyroid carcinoma, cerebellar metastases, somatostatin receptors, somatostatin receptor scintigraphy

Streszczenie

Wstęp: Odległe przerzuty raka brodawkowego tarczycy (*papillary thyroid carcinoma*, PTC) mogą nie wykazywać zdolności do gromadzenia radiojodu. W takich przypadkach użytecznym badaniem może być scyntygrafia receptorów somatostatynowych, która może wykazać ekspresję receptorów somatostatynowych będących potencjalnym celem terapeutycznym. Dotychczas opisano zaledwie kilka przypadków przerzutów PTC do mózdzku.

Opis przypadku: U pacjentki w wieku 82 lat cztery lata po ustaleniu wstępnej diagnozy wykryto bezobjawowy przerzut PTC do mózdzku za pomocą badania scyntygraficznego z użyciem znacznika Tc-99m-EDDA/HYNIC-TOC. Wcześniejsze leczenie chorej obejmowało całkowitą tyroidektomię z resekcją regionalnych węzłów chłonnych, po której zastosowano trzy cykle radioterapii. Mimo stale podwyższonego stężenia tyreoglobuliny nie stwierdzono miejscowego gromadzenia radiojodu w scyntygrafii całego ciała wykonanej po leczeniu. Przeprowadzone później badanie scyntygraficzne z użyciem Tc-99m-EDDA/HYNIC-TOC wykazało ogniska zwiększonego wychwytu znacznika w płucach i węzłach chłonnych szyi, a także pojedyncze ognisko w mózdzku. W związku z wynikiem badania rozpoczęto leczenie oktreotydem LAR. Chora zmarła cztery miesiące później z powodu rozsianego PTC.

Podsumowanie: W tej pracy opisano przypadek chorej z bezobjawowym, niewykrytym wcześniej niejodochwytnym przerzutem do mózdzku raka brodawkowego tarczycy, który został rozpoznany za pomocą badania scyntygraficznego z użyciem analogu somatostatynowego Tc-99m-EDDA/HYNIC-TOC.

Wnioski: Scyntygrafia receptorów somatostatynowych może być użyteczna do wizualizacji niejodochwytnych przerzutów PTC i wykrywania ekspresji receptorów somatostatynowych, które są potencjalnym celem terapeutycznym. (*Endokrynol Pol* 2018; 69 (1): 24–27)

Słowa kluczowe: zróżnicowany rak tarczycy, rak brodawkowy tarczycy, przerzuty do mózdzku, receptory somatostatynowych, scyntygrafia receptorów somatostatynowych

Introduction

Distant metastases occur rarely in patients with differentiated thyroid carcinoma (DTC). Brain metastases are very rare and cerebellar metastases are extremely rare

[1–3]. Usually brain metastases are detected by means of radioiodine whole-body scan (WBS) or magnetic resonance.

Somatostatin receptor scintigraphy (SRS) using radiolabelled somatostatin analogues has been employed



Prof. Marek Ruchała M.D., Ph.D., Department of Endocrinology, Metabolism, and Internal Medicine, Poznan University of Medical Sciences, Przybyszewskiego St. 49, 60-355 Poznan, Poland, tel. +48 61 869 13 30, +48 601 748 905, fax: +48 61 869 16 82, e-mail: mpruchala@ump.edu.pl

in the evaluation of some patients with advanced DTC with the aim of visualisation of non-iodine avid metastases. In the last decade, Tc-99m-labeled somatostatin analogues were developed, which replaced In-111-DTPA-octreotide (OctreoScan) in some centres [4–6]. Tc-99m-EDDA/HYNIC-TOC demonstrated relatively high sensitivity and specificity in the detection of recurrence in patients with elevated thyroglobulin and negative WBS [7].

We hereby report a patient in whom an asymptomatic non-iodine avid cerebellar metastasis from DTC was diagnosed by means of scintigraphy using somatostatin analogue Tc-99m-EDDA/HYNIC-TOC.

Patient

A 78-year-old Caucasian female was diagnosed with advanced papillary thyroid carcinoma (PTC) and subjected to total thyroidectomy with regional lymph node dissection (staging pT4N1M0), followed by L-thyroxine suppressive therapy. Subsequently, radioiodine ablation with 90 mCi was performed. The post-treatment WBS demonstrated slight radioiodine accumulation in the cervical lymph nodes, and persistent structural disease in the local lymph nodes was treated surgically. Later, radioiodine therapy was repeated twice due to persistent elevation of thyroglobulin (Tg), so the cumulative dose was 390 mCi. No specific radioiodine accumulation was found in the WBS performed seven days after recent radioiodine therapy. Neck sonography showed several enlarged hypoechoic lymph nodes on the left side of the neck. Computed tomography of the thorax disclosed three metastatic pulmonary nodules of size less than 10 mm.

Due to poor response to radioiodine therapy, possibly caused by dedifferentiation of PTC cells, other forms of treatment had to be considered. At that time tyrosine kinase inhibitors were not regularly available for the therapy of metastatic thyroid cancer, so we needed to consider somatostatin analogues as one of the potential therapies. In order to evaluate the status of somatostatin receptors in PTC cells, a Tc-99m-EDDA/HYNIC-TOC scan was performed.

In consistence with our protocol, the whole-body images were obtained three and 24 h after the IV injection of 20 mCi of Tc-99m-EDDA/HYNIC-TOC manufactured by Polatom, Poland. The scans were registered using an Infinia Hawkeye 4 (General Electric) gamma camera. The images showed foci of increased tracer uptake in the metastatic cervical lymph nodes and lungs, and a small focus of uptake in the head. Additional SPECT/CT of the head was performed. It showed a focus of increased tracer accumulation in the left cerebellar hemisphere 8 mm in size. (Fig. 1).

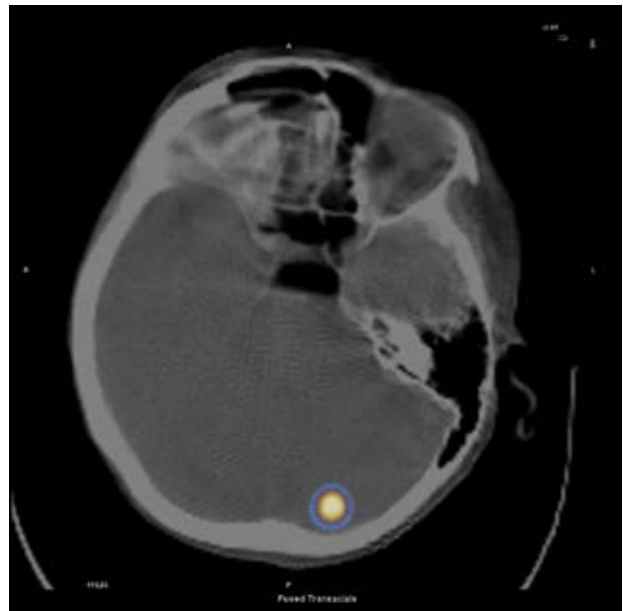


Figure 1. Focus of increased accumulation of Tc-99m-EDDA/HYNIC-TOC in the left cerebellar hemisphere visualised in SPECT/CT representing a cerebellar metastasis of papillary thyroid carcinoma

Rycina 1. W obrazie badania SPECT/CT zwraca uwagę zwiększone gromadzenie Tc-99m-EDDA/HYNIC-TOC w lewej półkuli odpowiadające przerzutowi do mózdzku raka brodawkowego tarczycy

Neurological examination did not reveal any signs of cerebellar dysfunction. As expression of somatostatin receptors was demonstrated in the metastatic foci and no radioiodine uptake was observed, experimental treatment with somatostatin analogue (Sandostatin LAR) was initiated. The therapy was well-tolerated. However, the patient died four months later at the age of 83 years due to advanced thyroid carcinoma.

Discussion

Metastases to the central nervous system among patients with DTC are extremely rare. Among 1200 patients with thyroid carcinoma treated in our institution, fewer than 1% had distant metastases detected at the time of initial diagnosis. The number of patients with distant metastases increases during follow-up and accounts for 5-10% of the patients. The most common locations are lungs (53%) and bones (28%) [8]. Brain metastases were present in only 1.5% patients treated in M.D. Anderson Cancer Centre over 51 years [9]. Most commonly they were located in the cerebral hemispheres. The median survival was 4.7 months following the diagnosis of brain metastases [9]. Misaki et al. reported nine patients with DTC that metastasised to the brain [10]. Lack of radioiodine accumulation in

the metastases was observed by several authors [10, 11]. In some patients, the metastases were detected in cases of occult thyroid carcinoma [12, 13].

Cerebellar metastases are even less common. Only 12 cases of metastatic changes in the cerebrum from DTC were reported in the literature, some of them occurring as solitary distant metastasis [2, 3, 13–17]. The metastatic lesion in our patient was not solitary. For the first time, however, a previously unknown cerebellar metastasis was first demonstrated by SRS, while WBS performed after radioiodine treatment was negative.

Overexpression of somatostatin receptors, especially SSTR2, in neuroendocrine tumours is the basis for using radiolabelled analogues of this hormone for imaging purposes. For many years, In-111-DTPA-octreotide (OctreoScan) has been used in the diagnosis of neuroendocrine tumours. The sensitivity of this method reported by different authors was 51–82% in subjects presenting DTC with elevated Tg concentrations and negative WBS [18, 19]. The wide range of positive results can be attributed to study qualification criteria (stage of the disease, Tg levels) and image registration protocols.

Disadvantages of scintigraphy with In-111-DTPA-octreotide include suboptimal energy of gamma radiation emitted by In-111, higher dose equivalent obtained by patient and personnel, delayed time of acquisitions, and relatively high cost of the radiopharmaceutical. Therefore, introduction of new somatostatin analogues labelled with Tc-99m represent significant progress in endocrine oncology [6]. Decristoforo et al. and Gabriel et al. found that Tc-99m-EDDA/HYNIC-TOC scintigraphy provided superior scans and higher tumour/background ratios than In-111-DTPA-octreotide [4, 5]. Several authors reported a high rate of positive results of scintigraphy with Tc-99m-EDDA/HYNIC-TOC or Tc-99m-EDDA/HYNIC-octreotide in different neuroendocrine tumours [20, 21]. The use of Tc-99m-EDDA/HYNIC-TOC in advanced stages of DTC was also extensively studied. As reported by Gabriel et al., sensitivity of this imaging method in patients with non-iodine avid DTC reached 66%, but was lower than that of 18F-FDG PET [7]. Also in our centre, SRS using Tc-99m-EDDA/HYNIC-TOC has been widely used, demonstrating encouraging results in patients with DTC, as well as with medullary thyroid carcinoma [22]. Although PET using F-18-FDG exhibits advantageous values of sensitivity and accuracy, SRS has been successfully used in our centre to evaluate the receptor status of endocrine malignancies. Similarly to neuroendocrine tumours, some of the patients with DTC were also experimentally treated with Y-90-labelled as well as with non-labelled ('cold') somatostatin analogues, with positive SRS being a major qualification criterion. Demonstration of positive status of metastatic changes for SRS was the

basis for the decision on the therapy with somatostatin receptor analogues. Therefore, the authors decided that PET imaging (not widely available at the time of management) was not performed in our patient.

A limitation of our report is the lack of histopathological confirmation of the PTC origin of the brain lesion, presenting uptake of Tc-99m-EDDA/HYNIC-TOC. The patient died due to disseminated PTC, hence an autopsy was medically unwarranted. However, normal chromogranin A level, no signs of primary focus of neuroendocrine tumour, and intracerebellar localisation argue against neuroendocrine tumour metastasis or meningioma, which are the two other types of lesions potentially presenting the expression of somatostatin receptors [5, 23].

To conclude, this report demonstrates not only an extremely rare location of DTC metastases but also the utility of SRS using technetium-labelled compound in the diagnosis of non-iodine avid metastases.

Author disclosure statement

No competing financial interests exist.

References

- Salvati M, Frati A, Rocchi G, et al. Single brain metastasis from thyroid cancer: report of twelve cases and review of the literature. *J Neurooncol.* 2001; 51(1): 33–40, indexed in Pubmed: [11349878](#).
- Pazaitou-Panayiotou K, Kaprara A, Chrisoulidou A, et al. Cerebellar metastasis as first metastasis from papillary thyroid carcinoma. *Endocr J.* 2005; 52(6): 653–657, indexed in Pubmed: [16410655](#).
- Al-Dhahri SE, Al-Amro AS, Al-Shakwer W, et al. Cerebellar mass as a primary presentation of papillary thyroid carcinoma: case report and literature review. *Head Neck Oncol.* 2009; 1: 23, doi: [10.1186/1758-3284-1-23](#), indexed in Pubmed: [19558727](#).
- Decristoforo C, Mather SJ, Cholewinski W, et al. 99m-Tc-EDDA/HYNIC-TOC: a new 99m-Tc-labelled radiopharmaceutical for imaging somatostatin receptor-positive tumors: first clinical result and intra-patient comparison with 111-In-labelled octreotide derivatives. *Eur J Nucl Med.* 2000; 27: 1318–1325, indexed in Pubmed: [11007513](#).
- Gabriel M, Decristoforo C, Donnemiller E, et al. An inpatient comparison of 99m-Tc EDDA/HYNIC-TOC with 111-In-DTPA-octreotide for diagnosis of somatostatin receptor expressing tumors. *J Nucl Med.* 2003; 44(5): 708–716, indexed in Pubmed: [12732671](#).
- Bangard M, Béhé M, Guhlke S, et al. Detection of somatostatin receptor-positive tumours using the new 99mTc-tricine-HYNIC-D-Phe1-Tyr3-octreotide: first results in patients and comparison with 111In-DTPA-D-Phe1-octreotide. *Eur J Nucl Med.* 2000; 27(6): 628–637, indexed in Pubmed: [10901448](#).
- Gabriel M, Froehlich F, Decristoforo C, et al. 99mTc-EDDA/HYNIC-TOC and (18)F-FDG in thyroid cancer patients with negative (131)I whole-body scans. *Eur J Nucl Med Mol Imaging.* 2004; 31(3): 330–341, doi: [10.1007/s00259-003-1376-x](#), indexed in Pubmed: [14625664](#).
- Schlumberger M, Pacini F. *Thyroid tumors.* Éditions Nucléon, Paris 2003.
- Chiu AC, Delpassand ES, Sherman SI. Prognosis and treatment of brain metastases in thyroid carcinoma. *J Clin Endocrinol Metab.* 1997; 82(11): 3637–3642, doi: [10.1210/jcem.82.11.4386](#), indexed in Pubmed: [9360519](#).
- Misaki T, Iwata M, Kasagi K, et al. Brain metastasis from differentiated thyroid cancer in patients treated with radioiodine for bone and lung lesions. *Ann Nucl Med.* 2000; 14(2): 111–114, indexed in Pubmed: [10830528](#).
- Cha ST, Jarrahy R, Mathiesen RA, et al. Cerebellopontine angle metastasis from papillary carcinoma of the thyroid: case report and literature review. *Surg Neurol.* 2000; 54(4): 320–326, indexed in Pubmed: [11136987](#).
- Michie HR, O'Bryan-Tear CG, Marsh H, et al. Cerebral metastases from occult papillary carcinoma of the thyroid. *Br J Surg.* 1987; 74(7): 647, indexed in Pubmed: [3620879](#).
- Ota T, Bando Y, Hirai M, et al. Papillary carcinoma of the thyroid with distant metastases to the cerebrum: a case report. *Jpn J Clin Oncol.* 2001; 31(3): 112–115, indexed in Pubmed: [11336322](#).

14. Pacak K, Sweeney DC, Wartofsky L, et al. Solitary cerebellar metastasis from papillary thyroid carcinoma: a case report. *Thyroid*. 1998; 8(4): 327–335, doi: [10.1089/thy.1998.8.327](https://doi.org/10.1089/thy.1998.8.327), indexed in Pubmed: [9588498](https://pubmed.ncbi.nlm.nih.gov/9588498/).
15. Jyothirmayi R, Edison J, Nayar PP, et al. Case report: brain metastases from papillary carcinoma thyroid. *Br J Radiol*. 1995; 68(811): 767–769, doi: [10.1259/0007-1285-68-811-767](https://doi.org/10.1259/0007-1285-68-811-767), indexed in Pubmed: [7640935](https://pubmed.ncbi.nlm.nih.gov/7640935/).
16. Lecumberri B, Alvarez-Escolá C, Martín-Vaquero P, et al. Solitary hemorrhagic cerebellar metastasis from occult papillary thyroid microcarcinoma. *Thyroid*. 2010; 20(5): 563–567, doi: [10.1089/thy.2010.0062](https://doi.org/10.1089/thy.2010.0062), indexed in Pubmed: [20450434](https://pubmed.ncbi.nlm.nih.gov/20450434/).
17. Xu YH, Song HJ, Qiu ZL, et al. Brain metastases with exceptional features from papillary thyroid carcinoma: report of three cases. *Hell J Nucl Med*. 2011; 14(1): 56–59, indexed in Pubmed: [21512667](https://pubmed.ncbi.nlm.nih.gov/21512667/).
18. Giammarile F, Houzard C, Bournaud C, et al. Diagnostic management of suspected metastatic thyroid carcinoma: clinical value of octreotide scintigraphy in patients with negative high-dose radioiodine scans. *Eur J Endocrinol*. 2004; 150(3): 277–283, indexed in Pubmed: [15012611](https://pubmed.ncbi.nlm.nih.gov/15012611/).
19. Stokkel MPM, Reigman HIE, Verkooijen RBT, et al. Indium-111-Octreotide scintigraphy in differentiated thyroid carcinoma metastases that do not respond to treatment with high-dose I-131. *J Cancer Res Clin Oncol*. 2003; 129(5): 287–294, doi: [10.1007/s00432-003-0435-9](https://doi.org/10.1007/s00432-003-0435-9), indexed in Pubmed: [12750997](https://pubmed.ncbi.nlm.nih.gov/12750997/).
20. Plachcińska A, Mikołajczak R, Maecke HR, et al. Clinical usefulness of ^{99m}Tc-EDDA/HYNIC-TOC scintigraphy in oncological diagnostics: a preliminary communication. *Eur J Nucl Med Mol Imaging*. 2003; 30(10): 1402–1406, doi: [10.1007/s00259-003-1254-6](https://doi.org/10.1007/s00259-003-1254-6), indexed in Pubmed: [12845490](https://pubmed.ncbi.nlm.nih.gov/12845490/).
21. Hubalewska-Dydejczyk A, Fröss-Baron K, Mikołajczak R, et al. ^{99m}Tc-EDDA/HYNIC-octreotate scintigraphy, an efficient method for the detection and staging of carcinoid tumours: results of 3 years' experience. *Eur J Nucl Med Mol Imaging*. 2006; 33(10): 1123–1133, doi: [10.1007/s00259-006-0113-7](https://doi.org/10.1007/s00259-006-0113-7), indexed in Pubmed: [16721571](https://pubmed.ncbi.nlm.nih.gov/16721571/).
22. Czepczyński R, Parisella MG, Kosowicz J, et al. Somatostatin receptor scintigraphy using ^{99m}Tc-EDDA/HYNIC-TOC in patients with medullary thyroid carcinoma. *Eur J Nucl Med Mol Imaging*. 2007; 34(10): 1635–1645, doi: [10.1007/s00259-007-0479-1](https://doi.org/10.1007/s00259-007-0479-1), indexed in Pubmed: [17530247](https://pubmed.ncbi.nlm.nih.gov/17530247/).
23. Barresi V, Alafaci C, Salpietro F, et al. Sstr2A immunohistochemical expression in human meningiomas: is there a correlation with the histological grade, proliferation or microvessel density? *Oncol Rep*. 2008; 20(3): 485–492, indexed in Pubmed: [18695896](https://pubmed.ncbi.nlm.nih.gov/18695896/).