



Macular amyloidosis complicating macroprolactinoma — a novel clinical association

Amyloidoza plamkowata jako powikłanie makrogruczolaka prolaktynowego przysadki — nowy związek kliniczny

Deep Dutta¹, Arvind Ahuja², Lokesh Sharma³, Minakshi Bhardwaj², Bindu Kulshreshtha¹

¹Department of Endocrinology Post Graduate Institute of Medical Education&Research (PGIMER) and Dr. Ram ManoharLohia (RML) Hospital, New Delhi 110001, India

²Department of Pathology, Post Graduate Institute of Medical Education&Research (PGIMER) and Dr. Ram ManoharLohia (RML) Hospital, New Delhi 110001, India

³Department of Biochemistry, Post Graduate Institute of Medical Education&Research (PGIMER) and Dr. Ram ManoharLohia (RML) Hospital, New Delhi 110001, India

Abstract

Amyloid deposition in the pituitary gland is a rare localised form of amyloidosis, and most commonly reported with prolactinoma. Macular amyloidosis is a rare form of localised cutaneous amyloidosis of obscure aetiology. In contrast to most localised amyloidosis, the precursor protein(s) of both macular amyloidosis and prolactinoma are unknown. A 35-year-old man with chronic headache (six years), blurring of vision (three years), and hyperpigmented macular lesion involving arms, legs, and back (two years) was diagnosed to have hyperprolactinaemia (8927 ng/mL) and secondary adrenal insufficiency. MRI revealed pituitary macroadenoma compressing the optic chiasma, encasing the right carotid artery and extending into the sphenoid sinus. A biopsy of skin from the right upper arm revealed thickened stratum corneum, acanthosis, and deposition of pale eosinophilic material in papillary dermis that gave a rose pink colour under methyl-violet and appeared congophilic with Congo red stain, which under polarised light showed green birefringence, diagnostic of macular amyloidosis. Headache, bitemporal haemianopia, and skin lesion improved following cabergoline therapy. Temporal profile of the disease characterised by symptoms of macroprolactinoma preceding onset of macular amyloidosis with resolution of symptoms of macroprolactinoma, accompanied by reductions in prolactin, and concomitant improvement in macular amyloidosis with cabergoline therapy may suggest some link between macroprolactinoma and macular amyloidosis. This report intends to highlight this novel association of macular amyloidosis and macroprolactinoma. (*Endokrynol Pol* 2015; 66 (6): 555–558)

Key words: macular amyloidosis; macroprolactinoma; prolactin; macroadenoma; pituitary

Streszczenie

Złogi amyloidu w przysadce to rzadka forma lokalizacji amyloidozy. Najczęściej występuje razem z gruczolakiem prolaktynowym przysadki. Amyloidoza plamkowata to rzadka forma skupionej amyloidozy skórnej o niewyjaśnionej etiologii. Przeciwnie do większości amyloidoz występujących w jednym miejscu, białko prekursora zarówno amyloidozy plamkowej, jak i gruczolaka prolaktynowego pozostają nieznane. U 35-letniego mężczyzny cierpiącego na przewlekły ból głowy (od 6 lat), nieostre widzenie (od 3 lat) oraz plamkowe zmiany pigmentacyjne na rękach, nogach i plecach (od 2 lat) zdiagnozowano hiperprolaktynemię (8927 ng/ml) i wtórną niedoczynność kory nadnerczy. Badanie rezonansem magnetycznym ujawniło makrogruczolaka przysadki mózgowej, uciskającego skrzyżowanie wzrokowe, prawą tętnicę szyjną i ekspansję/rozrostem do zatoki klinowej. Biopsja skóry z górnej części prawego ramienia wykazała pogrubienie warstwy rogowej naskórka, akantozę, złogi bladego materiału kwasochłonnego w warstwie brodawkowatej skóry właściwej, które barwiły na różowo przy zetknięciu z fioletem metylowym i wydawały się podatne na barwienie czerwienią kongo, które w świetle spolaryzowanym ujawniało zieloną dwójłomność, wskazując na występowanie amyloidozy plamkowej. Ból głowy, niedowidzenie połowicze dwuskroniowe, a także zmiany skórne uległy poprawie po zastosowaniu leczenia kabergoliną. Czas wystąpienia choroby, charakteryzującej się objawami makrogruczolaka prolaktynowego przysadki, poprzedzającymi rozpoczęcie amyloidozy plamkowej wraz ze złagodzeniem objawów makroprolaktynomy oraz redukcją stężenia prolaktyny, a także jednoczesnej poprawie amyloidozy plamkowej przy terapii kabergoliną może sugerować, że istnieje związek między makrogruczolakiem prolaktynowym i amyloidozą plamkową. Niniejszy raport ma na celu naświetlenie nowego związku między amyloidozą plamkową i makrogruczolakiem prolaktynowym przysadki. (*Endokrynol Pol* 2015; 66 (6): 555–558)

Słowa kluczowe: amyloidoza plamkowata; makrogruczolak prolaktynowy; prolaktyna; makrogruczolak; przysadka

Introduction

Amyloidoses are a heterogeneous group of disorders characterised by extracellular deposition of proteins in various

organs and tissues, resulting in disruption of normal homeostatic mechanisms and cell death [1]. Amyloidosis can be systemic (multiple sites/organs of deposition of amyloid protein, with the primary pathology leading to



Deep Dutta M.D., Department of Endocrinology, Post Graduate Institute of Medical Education & Research (PGIMER) and Dr Ram ManoharLohia (RML) Hospital, New Delhi 110001, India, phone: +91 991 154 40 96, e-mail: deepdutta2000@yahoo.com

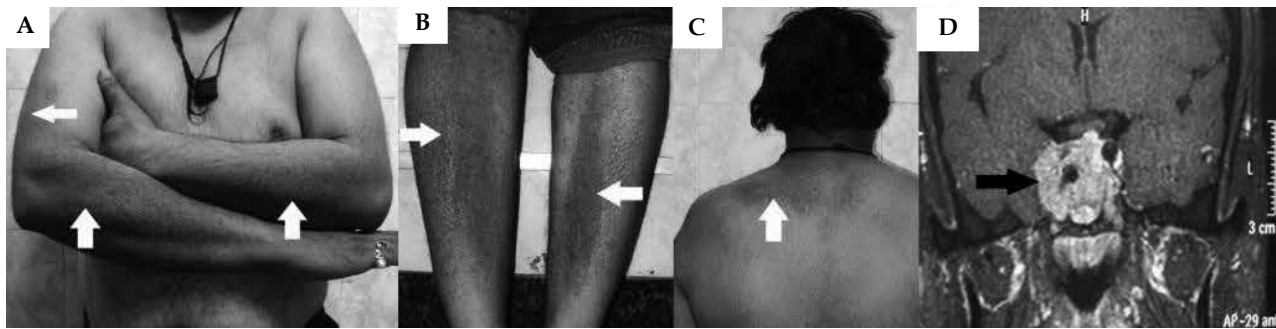


Figure 1A. Hyper-pigmented brownish 3–5 mm diameter macular lesions seen on bilateral upper arms and forearms (white arrows); **B.** Similar hyperpigmented lesions seen on shin of bilateral tibia (right greater than left) (white arrows); **C.** Hyperpigmented macular lesion seen in the interscapular area; **D.** Magnetic resonance imaging of the sellar region (T1W) showing heterogeneous mass in the sella with variable enhancement post-contrast administration, compressing the optic chiasma superiorly, encasing the right carotid artery and extending inferiorly into the sphenoid sinus, suggestive of macroadenoma

Rycina 1A. Brązowa zmiana plamkowa o silnej pigmentacji o średnicy 3–5 mm, widziana po obu stronach ramion i przedramion (białe strzałki); **B.** Podobnie zmiany o silnej pigmentacji widziane na goleni z obu stron piszczeli (prawa większa) (białe strzałki); **C.** Zmiana plamkowa o silnej pigmentacji, widziana na obszarze między łopatkami; **D.** Rezonans magnetyczny siodła tureckiego (T1W) ukazujący heterogeniczną masę w siodle ze zmiennym uwidocznieniem po podaniu kontrastu, uciskającą skrzyżowanie wzrokowe od góry, unieruchamiającą prawą tętnicę szyjną i rozciągającą się od dołu na zatokę klinową, sugerując obecność makrogruczolaka

increased amyloid protein formation at a different site) or localised (amyloid protein formation as well as deposition is localised event involving a particular tissue or organ) [2]. The most common systemic amyloidoses include haematological malignancies, and conditions secondary to chronic inflammatory, like tuberculosis, bronchiectasis, osteomyelitis, and connective tissue disorders [3]. Common forms of localised amyloidosis include type 2 diabetes and Alzheimer's disease where amyloid fibrils are deposited in pancreas and neural cells, respectively [4].

Amyloid deposition in the sella and parasellar region has rarely been reported in patients with pituitary adenoma [5]. It has most commonly been observed in patients with prolactinoma, followed by growth hormone secreting adenoma and non-functioning pituitary adenoma [5]. Degradation of secretory granules in vesicles containing amyloid fibrils is believed to have some role in its pathogenesis [4]. This and age-related amyloid deposition are believed to be the two different forms of localised amyloidosis of pituitary, without involvement of any other tissues or organs [4, 5]. Macular amyloidosis (also known as frictional amyloidosis), characterised by pruritic greyish-brown macules commonly involving the inter-scapular area, upper arms, chest, and thighs, is a form of cutaneous amyloidosis of obscure aetiology [6]. This report intends to highlight the novel association of macular amyloidosis in a patient with macroprolactinoma, which improved with cabergoline therapy.

Case report

A 35-year-old man with progressively worsening chronic headache of six years duration, accompanied

by progressive blurring of vision for the preceding three years with rapid deterioration in the last six months, was evaluated in the endocrinology clinic, following referral from the ophthalmology department after detection of bitemporal haemianopia. He complained of hyperpigmented skin lesions predominantly involving the upper arms, forearm, shin of tibia, and interscapular region of two-year duration associated with pruritus, predominantly in the night. The physical examination was significant for body mass index of 33.44 kg/m², hyper-pigmented brownish 3–5 mm diameter macular lesions involving the above-mentioned areas with scratch marks, with some lesions having a rippled pattern (Fig. 1A–C). Systemic examination was normal except for bitemporal haemianopia. Biochemical investigations revealed elevated serum prolactin, accompanied by low basal and post ACTH stimulated serum cortisol (Table I). Pituitary magnetic resonance imaging (MRI) revealed 3.2 × 2.7 × 2.5 cm heterogeneously enhancing pituitary adenoma compressing the optic chiasma superiorly, eroding the floor of the sella inferiorly with extension into the sphenoid sinus and laterally involving the right cavernous sinus (Fig. 1D), leading to a diagnosis of macroprolactinoma with secondary hypocortisolism. Biopsy of skin from the right upper arm revealed thickened stratum corneum, mild acanthosis, and deposition of pale eosinophilic homogenous material in papillary dermis (Fig. 2A, B), which gave rose pink colour under methyl-violet and appeared congophilic with Congo red stain, which under polarised light showed green birefringence, leading to the diagnosis of macular amyloidosis

Table I. Biochemical investigations at baseline and post cabergoline therapy
Tabela I. Badania biochemiczne na początku badania i po terapii kabergoliną

Parameter	Baseline	Follow-up	
		3 months	6 months
Prolactin [ng/mL] (2.5–17)	8927	45	9
IGF-1 [ng/mL] (87–274)	208	–	–
1 Hour post 75 gram glucose GH [ng/mL] (<1)	0.46	–	–
fT ₄ [ng/dL] (0.63–1.98)	1.19	1.14	1.23
TSH [mU/L] (0.4–4.5)	1.20	1.8	2.1
9 a.m. cortisol [mcg/dL] (6.2–25)	4.2	–	–
1 hour post 250 mcg ACTH cortisol [mcg/dL] (> 18)	8.98	–	–
ACTH [pg/mL]	8	–	–
Luteinising hormone [mIU/mL] (1.14–5.75)	1.08	2.21	1.89
Follicle stimulating hormone [mIU/mL] (1.37–13.56)	1.92	2.43	2.47
9 a.m. testosterone [ng/dL] (280–1500)	298	379	463

Chemiluminescent microparticle immunoassay (VITROS® ECiQ Immunodiagnostic System, Johnson & Johnson, USA) was used for hormonal estimation; IGF — insulin like growth factor; T₄ — tetraiodothyronine; ACTH — adrenocorticotrophic hormone; GH — growth hormone; TSH — thyroid stimulating hormone

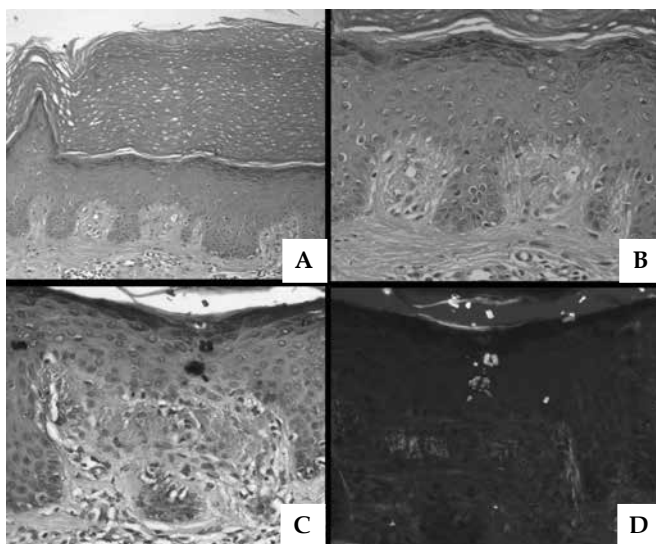


Figure 2A. Low-power photomicrograph showing thickened stratum corneum and mild acanthosis (H&E, 100×); **B.** High-power photomicrograph showing deposition of pale eosinophilic homogenous material in papillary dermis (H&E, 400×); **C.** Congo red stain revealed congophilic material (CR, 400×); **D.** Green birefringence seen under polarised light (CR, ×400)

Rycina 2A. Mikrofotografia zrobiona urządzeniem o niskiej mocy, ukazująca zgrubiałą warstwę rogówką naskórka i łagodną akantozę (H&E, 100×); **B.** Mikrofotografia zrobiona urządzeniem o wysokiej mocy, ukazująca złogi bladego materiału kwasochłonnego w warstwie brodawkowatej skóry właściwej (H&E, 400×); **C.** Wybarwienie czerwieni kongo ujawniło materiał kwasochłonny (CR, 400×); **D.** Zielona dwójłomność widziana w świetle spolaryzowanym (CR, ×400).

(Fig. 2C, D). Chest X-ray, ultrasonography of the abdomen, and serum and urine immunofixation protein electrophoresis were normal.

Headache and visual field defects improved with cabergoline therapy, which was initiated at 0.5 mg/week and rapidly titrated to 3 mg/week. Hydrocortisone replacement (15 mg/d) in divided doses (with counseling for stress dose escalation) was started to correct the hypocortisolism. When last evaluated, six months after the initial diagnosis, the patient was clinically asymptomatic with resolution of pruritus, decrease in hyperpigmented skin lesions (Fig. 3A–C), and significant reduction in the size of pituitary macroadenoma (Fig. 3D).

Discussion

Macular amyloidosis is a subtle form of cutaneous localised amyloidosis, believed to be more common in females, Asians, Middle-Easterners, and South Americans, most commonly in the third to fifth decade of life, with sun exposure, atopy, and friction being some of the postulated risk factors [6]. Macular amyloidosis has previously been reported in association with lupus, systemic sclerosis, primary biliary cirrhosis, and multiple endocrine neoplasia-2, suggestive of a possible autoimmune aetiology [4]. There is a single report of macular amyloidosis in a patient with primary hypothyroidism [7]. Macular amyloidosis is difficult to treat,

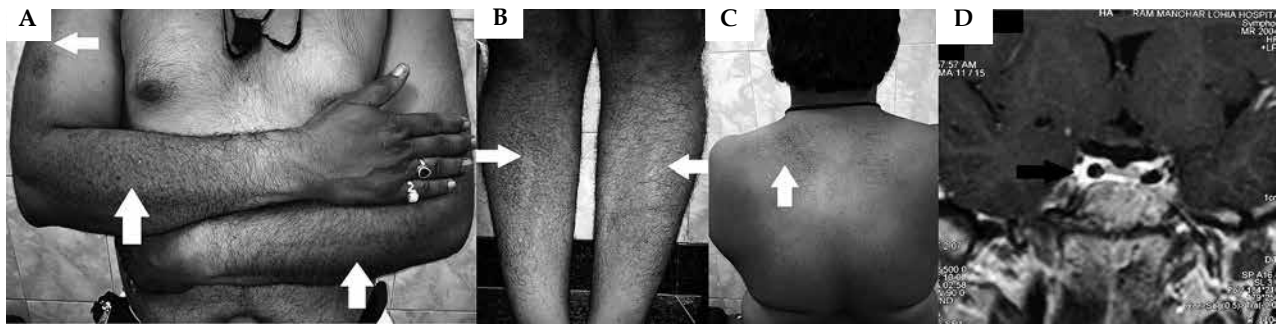


Figure 3A Significant reduction in skin lesions on both forearms and arms at six months of follow-up (white arrows) (compared to Figure 1A); **B.** Significant reduction in hyperpigmented skin lesions on bilateral shin of tibia, with almost complete disappearance of lesions on left side (white arrows) (compared to Figure 1B); **C.** Significant reduction in hyperpigmented macular lesions in the interscapular area (white arrow) (compared to Figure 1C); **D.** Magnetic resonance imaging of the sellar region (T1W) showing significant reduction in the size of macroadenoma. The tumour is now distant from the optic chiasma, and is seen predominantly encasing the carotid arteries on both sides.

Rycina 3A. Znaczna redukcja zmiany skórnej na obu przedramionach i ramionach po sześciu miesiącach obserwacji (białe strzałki) (w porównaniu z ryciną 1A); **B.** Znaczna redukcja silnie napigmentowanych zmian skórnych po obu stronach piszczeli z niemal całkowitym ustąpieniem zmian po lewej stronie (białe strzałki) (w porównaniu do Ryciny 1B); **C.** Znaczna redukcja zmian plamkowych na obszarze między łopatkami (biała strzałka) (w porównaniu z ryciną 1C); **D.** Rezonans magnetyczny siodła tureckiego (T1W), ukazujący znaczne zmniejszenie rozmiaru makrogruczolaka. Guz znajduje się teraz daleko od skrzyżowania wzrokowego i widać, że uciska tętnice szyjne z obu stron

with variable to poor response to topical corticosteroids, ultraviolet-B, etretinate, acitretin, cyclophosphamide, cyclosporine, and Nd-YAG laser therapy [6, 7].

Like macular amyloidosis, amyloidosis in prolactinoma is also a form of localised amyloidosis, with deposition of amyloid protein in the sellar and parasellar regions. Extensive spherical amyloid deposits in the pituitary have very rarely been reported with pituitary adenomas [8]. There are less than 20 such reports to date, almost exclusively with macroprolactinomas [8, 9]. These amyloid spheroids typically stain strongly for prolactin [8, 9]. Low to intermediate signal on T2-weighted imaging along with signal intensity similar to that of muscles on T1-weighted imaging is the characteristic feature of amyloid deposition in pituitary on MRI [9, 10]. Similar intensities on pituitary imaging in our patient may be suggestive of intra-pituitary amyloid deposition.

The precursor protein of most forms of localised amyloidosis has been determined. Type-2 diabetes, perhaps the most common form of localised amyloidosis, is characterised by deposition of amylin (islet amyloid polypeptide) in the pancreas [11]. However, it is important to realise that the precursor protein(s) of both macular amyloidosis and prolactinoma remain unknown [11]. The temporal profile of the disease characterised by symptoms suggestive of pituitary macroadenoma preceding the onset of macular amyloidosis with resolution of symptoms of macroprolactinoma, accompanied by reductions in circulating prolactin levels, and concomitant improvement in macular amyloidosis with cabergoline therapy, may suggest some link between macroprolactinoma and macular amyloidosis. Lack of histopathological evidence of amyloid deposition in the pituitary of our

patient, and comparison of its immunohistochemistry with skin biopsy prevents us from establishing a direct pathologic link. However, trans-sphenoidal resection of macroprolactinoma was not warranted in our patient, as cabergoline (dopamine agonists) is the first-line therapy and the treatment of choice in managing patients with all forms of prolactinoma, including invasive giant prolactinoma [12]. This report intends to highlight the novel association of macular amyloidosis and macroprolactinoma, the cause of which could not be determined. Keen watch out for similar such observation with further study is warranted.

References

- Merlini G, Bellotti V. Molecular mechanisms of amyloidosis. *N Engl J Med* 2003; 349: 583–596.
- Westermarck P, Benson MD, Buxbaum JN et al. A primer of amyloid nomenclature. *Amyloid*. 2007; 14: 179–183.
- Röcken C, Shakespeare A. Pathology, diagnosis and pathogenesis of AA amyloidosis. *Virchows Arch* 2002; 440: 111–122.
- Ozdemir D, Dagdelen S, Erbas T. Endocrine involvement in systemic amyloidosis. *Endocr Pract* 2010; 16: 1056–1063.
- Saitoh Y, Mori H, Matsumoto K et al. Accumulation of amyloid in pituitary adenomas. *Acta Neuropathol* 1985; 68: 87–92.
- Bandhlish A, Aggarwal A, Koranne RV. A ClinicoEpidemiological Study of Macular Amyloidosis from North India. *Indian J Dermatol* 2012; 57: 269–274.
- Chopra A, Pahuja K, Chopra D. Macular amyloidosis and hypothyroidism. *Indian J Dermatol Venereol Leprol* 1999; 65: 79–80.
- Sung CO, Suh YL, Lee da K. Extensive spherical amyloid deposition of pituitary adenoma presenting as pituitary apoplexy. *Clin Neurol Neurosurg* 2008; 110: 424–425.
- Wiesli P, Brändle M, Brandner S et al. Extensive spherical amyloid deposition presenting as a pituitary tumor. *J Endocrinol Invest* 2003; 26: 552–555.
- Kransdorf MJ, Murpey MD. In: *Imaging of soft tissue tumors*. WB. Saunders, Philadelphia, 1997; 385–387.
- Rocken C, Uhlig H, Saeger W et al. Amyloid Deposits in Pituitaries and Pituitary Adenomas: Immunohistochemistry and In Situ Hybridization. *Endocr Pathol* 1995; 6: 135–143.
- Dutta D, Ghosh S, Mukhopadhyay S et al. Rapid reduction with cystic transformation of invasive giant prolactinoma following short term low dose cabergoline. *Indian J Endocrinol Metab* 2012; 16: 1048–1055.