



# Unilateral laparoscopic adrenalectomy following partial transsphenoidal adenomectomy of pituitary macroadenoma – life-saving procedure in a patient with ACTH-dependent Cushing's syndrome

Jednostronna laparoskopowa adrenaektomia w połączeniu z częściowym przezklinowym usunięciem gruczolaka przysadki wydzielającego ACTH- operacją ratującą życie pacjentce z chorobą Cushinga

Urszula Ambroziak<sup>1</sup>, Grzegorz Zieliński<sup>2</sup>, Sadegh Toutouchi<sup>3</sup>, Ryszard Pogorzelski<sup>3</sup>, Maciej Skórski<sup>3</sup>, Andrzej Cieszanowski<sup>4</sup>, Piotr Miśkiewicz<sup>1</sup>, Michał Popow<sup>1</sup>, Tomasz Bednarczuk<sup>1</sup>

<sup>1</sup>Department of Internal Medicine and Endocrinology, Medical University of Warsaw, Poland

<sup>2</sup>Department of Neurosurgery, Military Institute of Medicine, Warsaw, Poland

<sup>3</sup>Department of General and Endocrine Surgery, Medical University of Warsaw, Poland

<sup>4</sup>II Department of Clinical Radiology, Medical University of Warsaw, Poland

## Abstract

**Introduction:** Cushing's disease is the most common cause of endogenous hypercortisolemia, in 90% of cases due to microadenoma. Macroadenoma can lead to atypical hormonal test results and complete removal of the tumour is unlikely.

**Case report:** A 77-year-old woman with diabetes and hypertension was admitted because of fatigue, proximal muscle weakness, lower extremities oedema, and worsening of glycaemic and hypertension control. Physical examination revealed central obesity, 'moon'-like face, supraclavicular pads, proximal muscle atrophy, and skin hyperpigmentation. Biochemical and hormonal results were as follows: K 2.3 mmol/L (3.6–5), cortisol 8.00 86 µg/dL (6.2–19.4) 23.00 76 µg/dL, ACTH 8.00 194 pg/mL (7.2–63.3) 23.00 200 pg/mL, DHEAS 330 µg/dL (12–154). CRH stimulation test showed lack of ACTH stimulation > 35%, overnight high dose DST revealed no suppression of cortisol. Chest and abdominal CT as well as somatostatin receptor scan didn't show ectopic tumour responsible for ACTH oversecretion. MRI revealed a pituitary macroadenoma (28 × 20 × 17 mm) extending towards the left cavernous sinus. After partial transsphenoidal adenomectomy, serum cortisol of 40 µg/dL was obtained. The patient's condition was still very poor, so unilateral adrenalectomy was performed. After surgery, serum morning cortisol level dropped to 20 µg/dL and the patient's condition improved significantly. 26 months after the operations, the patient remains in remission. Because her life expectancy exceeds the prognosed duration of remission with the presence of pituitary tumour remnants and intact left adrenal gland, the patient was qualified to radiosurgery with a Gamma Knife.

**Conclusion:** In selected cases, unilateral, laparoscopic adrenalectomy may serve as a life-saving procedure in a patient with ACTH-dependent Cushing's syndrome. (*Endokrynol Pol* 2015; 66 (1): 68–72)

**Key words:** Cushing's disease; adrenalectomy; transsphenoidal surgery

## Streszczenie

**Wstęp:** Choroba Cushinga stanowi najczęstszą przyczynę endogennej hiperkortyzolemii, w 90 % w przebiegu mikrogruczolaka przysadki. W przypadku makrogruczolaków rozpoznanie może być utrudnione z powodu nietypowych wyników testów hormonalnych a radykalne usunięcie guza często niemożliwe.

**Opis przypadku:** 77-letnia, otyła chora z cukrzycą i nadciśnieniem tętniczym została przyjęta z powodu postępującego osłabienia mięśni kończyn dolnych, obrzęków kończyn dolnych, pogorszenia kontroli glikemii i nadciśnienia tętniczego. W badaniu przedmiotowym stwierdzono otyłość centralną, zaokrąglenie twarzy, nadobojczykowe tłuszczowe poduszeczki, hiperpigmentację skóry. W badaniach biochemicznych: K 2,3 mmol/l (3,6–5), kortyzol 8.00 86 µg/dl (6,2–19,4) 23.00 76 µg/dl, ACTH 8.00 194 pg/ml (7,2–63,3) 23.00 200 pg/ml, DHEAS 330 µg/dl (12–154). W teście z CRH nie uzyskano stymulacji ACTH > 35 % a w teście z 8 mg deksametazonu nie uzyskano supresji kortyzolu > 50 %. Wykonano badanie CT klatki piersiowej i jamy brzusznej oraz scyntyografię receptorów somatostatynowych nie znajdując ekotopowego źródła nadmiernej produkcji ACTH. W MRI przysadki stwierdzono makrogruczolak 28 × 20 × 17 mm. Chora została zakwalifikowana do przezklinowej resekcji guza. Po częściowej adenomektomii stężenie kortyzolu wynosiło 40 µg/dl ale z uwagi na utrzymujące się objawy ciężkiej hiperkortyzolemii zdecydowano o jednostronnej adrenaektomii ze wskazań życiowych. Po operacji stężenie kortyzolu wynosiło 20 µg/dl i stan chorej ulegał stopniowej poprawie. Po 26 miesiącach od operacji chora pozostaje w remisji. Z uwagi na przewidywany okres przeżycia przekraczający prognozowaną długość remisji, wobec obecności resztki guza przysadki i lewego nadnercza Chora została zakwalifikowana do leczenia radiochirurgicznego z użyciem Gamma Knife.

**Wniosek:** W wybranych przypadkach jednostronna laparoskopowa adrenaektomia może być operacją ratującą życie u chorych z ciężkim ACTH-zależnym zespołem Cushinga. (*Endokrynol Pol* 2015; 66 (1): 68–72)

**Słowa kluczowe:** choroba Cushinga; adrenaektomia; operacja przezklinowa



Urszula Ambroziak M.D., Katedra i Klinika Chorób Wewnętrznych i Endokrynologii WUM. Banacha St. 1a, 02-097 Warszawa, tel.: +48 22 599 2877, fax: +48 22 599 1975, e-mail: uambroziak@wum.edu.pl

## Introduction

Endogenous Cushing's syndrome (CS) remains a diagnostic and therapeutic dilemma, especially in a patient with a macroadenoma secreting adrenocorticotropin (ACTH) [1, 2]. In such patients, the clinical picture may be more dramatic, suggesting ectopic ACTH secretion [3]. Moreover, many laboratory tests which are used to distinguish between Cushing's disease (CD) and ectopic ACTH secretion (*e.g.* corticotropin releasing hormone (CRH) stimulation test, high dose dexamethasone suppression test (HDDST)), give false results [4]. Transsphenoidal surgery (TSS) in an ACTH-producing macroadenoma is not curative in many patients, so additional therapy is needed [5]. Despite improved radiotherapy and a variety of pharmacological treatment options (ketoconazole, metyrapone, mitotane, mifepristone, pasireotide), in patients with life-threatening CS, adrenalectomy needs to be considered. Usually bilateral adrenalectomy is regarded as the operation of choice in such cases. However, we here describe for the first time the beneficial effects of unilateral adrenalectomy following partial transsphenoidal adenomectomy of a pituitary macroadenoma in a patient with life-threatening CS due to a macroadenoma secreting ACTH.

## Case report

A 77-year-old woman with a three year history of hypertension and proximal muscle weakness of unknown origin, and a few months history of diabetes mellitus, was admitted to the Department of Endocrinology with a suspicion of CS. She had started to experience

prominent fatigue, muscle weakness (so she was unable to walk), lower extremities and facial oedema, depression, and worsening of glycaemic and hypertension control three weeks previously. Severe hypokalemia (serum potassium 2.3 mmol/L) was the key abnormality that prompted the determination of serum cortisol. On admission, the patient was in a very poor condition. She presented with central obesity, a 'moon'-like face, supraclavicular pads, proximal muscle atrophy, skin hyperpigmentation, easy bruising, and prominent lower extremities oedema (Table I).

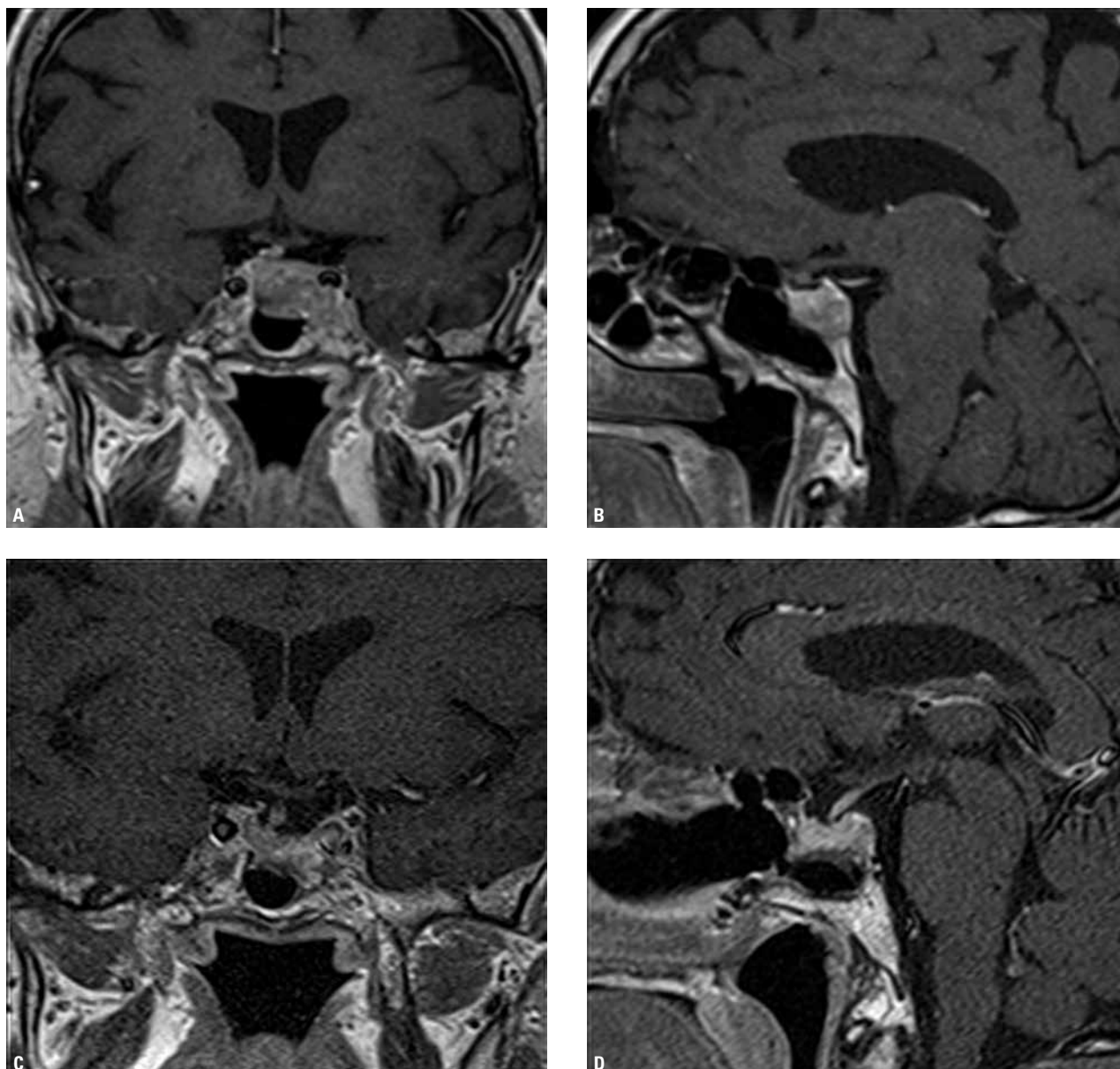
Once the diagnosis of ACTH-dependent CS had been established, a CRH stimulation test and an overnight high dose dexamethasone (8 mg) suppression test were done; both were consistent with the diagnosis of ectopic ACTH production. Because the chest computed tomography and somatostatin receptor PET/CT (using  $^{68}\text{Ga}$ -DOTA-TATE) didn't reveal the source of ACTH overproduction, pituitary MRI was performed and showed a pituitary macroadenoma invading the left cavernous sinus (Fig. 1 A, B). After two weeks of preparation with ketoconazole and spironolactone, the patient was qualified to partial transsphenoidal adenomectomy of the pituitary tumour. Treatment with ketoconazole was complicated by nausea, vomiting and marked elevation of aminotransferases. Although significant debulking of the tumour was achieved, ACTH and cortisol levels remained markedly elevated and the general condition of the patient was still poor (Fig. 1 C, D). Histopathological investigation confirmed a densely granulated corticotroph pituitary adenoma with MIB-1 < 1%. The patient was not qualified to prolonged pharmacologic treatment for several rea-

**Table I. Hormonal tests on admission and during follow up**

**Tabela I. Wyniki badań hormonalnych przy przyjęciu i w czasie obserwacji**

Parameters	On admission	After pituitary surgery	2 months after operations	26 months after operations	Normal ranges
Serum cortisol 08:00	86.53	46.26	13.93	7.67, 0.84	6.20–19.40 $\mu\text{g/dL}$
Serum cortisol 23:00	76.16	46.01	3.22	4.72	
Saliva cortisol 23:00	18.06	Nd	0.30	0.33	< 0.43 $\mu\text{g/dL}$
ACTH 08:00	194.30	91.58	42.31	36.00	7.30–63.30 $\text{pg/mL}$
ACTH 23:00	200.80	94.98	15.12	Nd	
DHEAS	330.20	Nd	14.59	44.60	12.00–154.00 $\mu\text{g/dL}$
Testosterone	3.35	Nd	< 0.09	0.13	0.10–1.40 $\text{nmol/L}$
DST 1 mg	61.95	Nd	Nd	1.98	< 1.80 $\mu\text{g/dL}$
Urine free cortisol	1618	Nd	Nd	17.00	15–108 $\mu\text{g/24h}$

ACTH — adrenocorticotropin hormone; DHEAS — dehydroepiandrosterone sulfate; DST — dexamethasone suppression test; Nd — not done



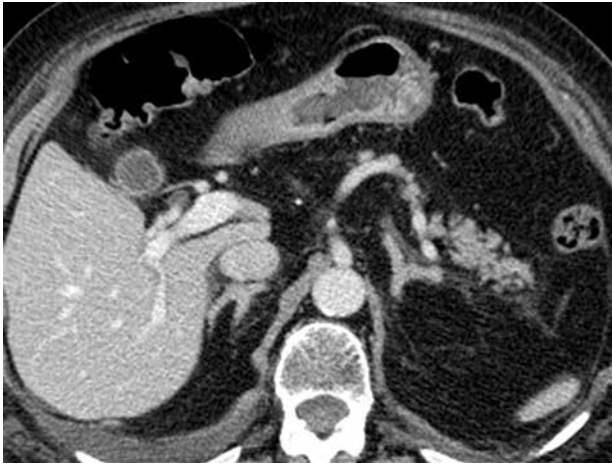**Figure 1.** MRI of pituitary gland performed before surgery revealed a pituitary tumour measuring  $28 \times 12 \times 17$  mm, penetrating to posterior part of the left cavernous sinus with a small tumour appendix in the right cavernous sinus and associated displacement of pituitary stalk. No compression of the optic chiasm was noted (A, B). Post TSS MRI showed decrease of the tumour volume, tumour remnants in left cavernous sinus, and small tumour appendix in the right cavernous sinus (C, D)

**Rycina 1.** Rezonans magnetyczny przed operacją: guz przysadki o wymiarach  $28 \times 20 \times 17$  mm penetrujący do tylnej części lewej zatoki jamistej. Niewielka wypustka guza w prawej zatoce jamistej. Lejek przysadki nieco przemieszczony w części dolnej na stronę prawą, skrzyżowanie nerwów wzrokowych bez zmian (A, B) i po operacji guza przysadki: zmniejszenie objętości zmiany, ale guz nadal dochodzi do lewej zatoki jamistej, mniejsza wypustka dochodzi do prawej zatoki jamistej, skrzyżowanie nerwów wzrokowych bez zmian (C, D)

sons: intolerance of ketoconazole; hypertension and profound hypokalemia spoke against metyrapon use; mifepristone is not available in Poland; delayed effect and off label use of mitotan; and no access to pasireotide (at that time the drug was not registered for CD) and aminoglutetimide. As a life-saving procedure, a decision on a right sided adrenalectomy was undertaken (on CT the adrenals were not enlarged — Fig. 2). Through right sided lateral transperitoneal access, the right adrenal

was removed by laparoscopy. Surgery was complicated by bradycardia, heart failure and respiratory failure, but a few days after the operation the condition of the patient started to improve and seven days later the patient was discharged from the hospital. The histopathological report revealed adrenocortical hyperplasia.

During following visits, the patient's condition was stable. Ten months after the operation, insulin was withdrawn and doses of antihypertensive drugs



**Figure 2.** CT image demonstrates normal adrenal glands  
**Rycina 2.** W badaniu CT uwidoczniono prawidłowe nadnercza

were reduced. The last assessment, 26 months after the operations, revealed fluctuating very low/Low/normal cortisol levels, low-normal UFC, borderline 1 mg DST, and normal late-night saliva cortisol. These results may indicate remission with cyclic ACTH/cortisol secretion (Table I). The patient is in good shape on stress doses of hydrocortisone. She has started to travel and leads a normal, active social life. Because her life expectancy exceeds however the time of prognosed duration of remission with the presence of pituitary tumour remnants and intact left adrenal gland, the patient was qualified to pituitary radiosurgery with a Gamma Knife.

## Discussion

To the best of our knowledge, we have presented for the first time a patient with life-threatening hypercortisolemia due to a pituitary macroadenoma that was treated with partial pituitary adenectomy followed by unilateral laparoscopic adrenalectomy as a life-saving procedure, who achieved remission after this approach.

TSS in a case of pituitary ACTH-producing macroadenoma is not curative in many patients, so additional therapy is needed. Such a procedure is however generally recommended even in tumours which cannot be totally resected [6].

We decided to perform transsphenoidal pituitary adenectomy as a primary treatment for several reasons: i) debulking of the tumour to decrease ACTH and cortisol level; ii) reduction of tumour size to limit the exposure of visual pathways and brainstem to further irradiation; and iii) access to the experienced pituitary neurosurgeon. After TSS, we have observed a decrease in ACTH and cortisol levels, but not suf-

ficient to improve the patient's condition. One must remember that the efficacy of TSS in ACTH-producing pituitary macroadenomas may be delayed. We can however speculate that delayed control of hypercortisolemia was possible to achieve but our patient's condition was so poor that further rescue treatment was necessary [7, 8].

In a case of persistent disease after pituitary surgery, repeat pituitary surgery, medical treatment, bilateral adrenalectomy or radiotherapy are established procedures [1, 2]. In our case however, reoperation was not possible because of tumour remnants localisation and medical treatment was not tolerated, contraindicated or not accessible. Radiotherapy achieves control of hypercortisolemia after 3–5 years, which spoke against this procedure as a urgent treatment [9–11]. Bilateral adrenalectomy provides immediate control of hypercortisolemia, and has been described as a life-saving procedure, but our patient's condition excluded synchronous bilateral simultaneous adrenalectomy, so the decision on laparoscopic unilateral, life-saving adrenalectomy was undertaken [14].

There is very little data concerning unilateral adrenalectomy in the treatment of ACTH-dependent Cushing's syndrome. Two case reports that report unilateral adrenalectomy in CD, describe in fact the recurrence of hypercortisolemia after TSS in patients with macronodular adrenal hyperplasia and autonomous cortisol production [15, 16]. Nagesser et al. summarised the results from Cushing's disease patients treated with unilateral adrenalectomy followed by pituitary irradiation compared to TSS. The remission and relapse rates were the same in both treatment modalities. External irradiation was however started after a median interval of one month after operation, so it is impossible to assess the prolonged effect of unilateral adrenalectomy on cortisol production [17].

The presented case may suggest that unilateral adrenalectomy can serve as an emergency procedure in a case of life-threatening hypercortisolemia and high risk of bilateral adrenalectomy.

Interestingly, unilateral adrenalectomy may be beneficial in patients with ACTH-independent CS due to macronodular adrenal hyperplasia (AIMAH) and primary pigmented nodular adrenal disease (PPNAD). The remission after this procedure lasts at least five years in 93% of patients [12, 13].

The indication for bilateral adrenalectomy in CD is the rapid cure of hypercortisolemia and persistent CD after unsuccessful TSS or radiotherapy and lack of control of hypercortisolemia on medical therapy/intolerance of medical treatment [1]. The cure rate for this procedure is high and reaches 90% [19]. Bilateral adrenalectomy performed by the endoscopic technique carries lower

intra- and postoperative complications compared to open bilateral adrenalectomy. Retrospective reviews found that the endoscopic approaches are associated with minimal blood loss, few intra-operative complications, and short hospital stays and recovery times. The risk of bilateral adrenalectomy is however higher than when using the unilateral approach [18, 19].

The main disadvantage associated with bilateral adrenalectomy is lifelong replacement therapy with gluco- and mineralocorticoids, the risk of life-threatening adrenal crisis, and the development of Nelson's syndrome [21, 22].

## Summary

Diagnosis and treatment of CS should be performed in referral centres which have a variety of treatment options. The best treatment option must be individualised for each patient. In selected cases of life-threatening Cushing's disease, a unilateral adrenalectomy can serve as a life-saving procedure.

## Acknowledgement

We wish to thank Prof. Lynnette Nieman from NIH/NICHD Bethesda, USA for consultation.

## References

1. Biller BM, Grossman AB, Stewart PM et al. Treatment of adrenocorticotropin dependent Cushing's: a consensus statement. *J Clin Endocrinol Metab* 2008; 93: 2454–2462.
2. Juszcak A, Grossman A. The management of Cushing's disease — from investigation to treatment. *Endokrynol Pol* 2013; 64: 166–174.
3. Nieman LK, Biller BMK, Findling JW et al. The diagnosis of Cushing's syndrome: an Endocrine Society Clinical Practice Guideline. *J Clin Endocrinol Metab* 2008; 93: 1526–1540.
4. Nieman LK. Cushing's disease: diagnosis, sampling and imaging. In: Lamberts SWJ (ed.). *Handbook of Cushing's disease*. Ed. BioScientifica, Bristol 2011; 17–33.
5. Cannavo S, Almoto B, Dall'Asta C et al. Long term results of treatment in patients with ACTH –secreting pituitary macroadenomas. *Eur J Endocrinol* 2003; 149: 195–200.
6. Buchfelder M, Schlafer S. Pituitary surgery for Cushing's disease. *Neuroendocrinology* 2010; 92: 102–106.
7. Valassi E, Biller BM, Swearingen B et al. Delayed remission after transphenoidal surgery in patients with Cushing's disease. *J Clin Endocrinol Metab* 2010; 95: 601–610.
8. Witek P, Zieliński G, Szamotulska K et al. Complications of Cushing's disease — prospective evaluation and clinical characteristics. Do they affect the efficacy of surgical treatment? *Endokrynol Pol* 2012; 63: 277–285.
9. Selvais P, Donckier J, Buysschaert M et al. Cushing's disease: a comparison of pituitary corticotroph microadenomas and macroadenomas. *Eur J Endocrinol* 1998; 138: 153–159.
10. Miller DL, Doppman JL, Peterman SB et al. Neurologic complications of petrosal sinus sampling. *Radiology* 1992; 185: 143–147.
11. Jagannathan J, Yen CP, Pouratian N et al. Stereotactic radiosurgery for pituitary adenomas: a comprehensive review of indications, techniques and long-term results using the Gamma Knife. *J Neurooncol* 2009; 92: 345–356.
12. Xu Y, Rui W, Qi Y et al. The Role of Unilateral Adrenalectomy in Corticotropin-Independent Bilateral Adrenocortical Hyperplasias. *W J Surg* 2013; 37: 1626–1632.
13. Kobayashi T, Miwa T, Kan K et al. Usefulness and limitations of unilateral adrenalectomy for ACTH-independent macronodular adrenal hyperplasia in a patient with a poor glycemic control. *Intern Med* 2012; 51: 1709–1713.
14. Han JY, Mirsadraei L, Yeh MW et al. Bilateral adrenalectomy: lifesaving procedure in severe Cushing syndrome. *Endocr Pract* 2012; 18: 85–90.
15. de la O Cabanillas M, Guzman C, Rodrogez P et al. Remission of hypercortisolism after unilateral adrenalectomy in a patient with persistent Cushing's disease and macronodular adrenal hyperplasia. *Endocrinol Nutr* 2009; 56: 381–383.
16. Timmers HJ, van Ginneken EM, Wesseling P et al. A patient with recurrent hypercortisolism after removal of an ACTH-secreting pituitary adenoma due to an adrenal macronodule. *J Endocrinol Invest* 2006; 29: 934–939.
17. Nagesser SK, van Seters AP, Kievit J et al. Treatment of pituitary — dependent Cushing's syndrome: long-term results of unilateral adrenalectomy followed by external pituitary irradiation compared to transphenoidal pituitary surgery. *Clin Endocrinol* 2000; 52: 427–435.
18. Jager E, Heintz A, Junginger T. Synchronous bilateral endoscopic adrenalectomy. *Surg Endosc* 2004; 18: 314–318.
19. Smith PW, Turza KC, Carter CO et al. Bilateral adrenalectomy for refractory Cushing's disease: a safe and definitive therapy. *J Am Coll Surg* 2009; 208: 1059.
20. Kelly WF, MacFarlane IA, Longson D et al. Cushing's disease treated by total adrenalectomy: long-term observations of 43 patients. *Q J Med* 1983; 52: 224.
21. Kasperlik-Zaluska AA, Bonicki W, Jeske W et al. Nelson's syndrome — 46 years later: clinical experience with 37 patients. *Zentralbl Neurochir* 2006; 67: 14–20.
22. Thompson Sarah K, Hayman AV, Ludlam WH et al. Improved Quality of Life After Bilateral Laparoscopic Adrenalectomy for Cushing's Disease: A 10-Year Experience. *Annals of Surgery* 2007; 245: 790–794.