



## Rozlany chłoniak złośliwy typu B przebiegający z naciekiem skrzyżowania wzrokowego, zaburzeniami widzenia, niedoczynnością przysadki, hiperprolaktynemią i moczówką prostą. Opis przypadku i przegląd literatury

Marek Bolanowski<sup>1</sup>, Małgorzata Kulisziewicz-Janus<sup>2</sup>, Violetta Sokolska<sup>3</sup>

<sup>1</sup>Katedra i Klinika Endokrynologii, Diabetologii i Leczenia Izotopami, Akademia Medyczna, Wrocław

<sup>2</sup>Katedra i Klinika Hematologii, Nowotworów Krwi i Transplantacji Szpiku, Akademia Medyczna, Wrocław

<sup>3</sup>Zakład Neuroradiologii Katedry Radiologii, Akademia Medyczna, Wrocław

### Streszczenie

Przedstawiono opis przypadku 55-letniego mężczyzny chorującego na rozlanego chłoniaka złośliwego typu B z towarzyszącym przemijającym naciekiem skrzyżowania wzrokowego i zaburzeniami widzenia oraz przetrwałą niedoczynnością przysadki, hiperprolaktynemią i moczówką prostą. Chorego leczono chemio- i radioterapią. Powtarzane badania za pomocą jądrowego rezonansu magnetycznego (NMR, *nuclear magnetic resonance*) i tomografii komputerowej (TK) wykazywały nacieki skrzyżowania nerwów wzrokowych, który ustępował w wyniku chemioterapii i znowu nawracał, zmieniał swój charakter i w końcu wycofał się. Równocześnie pojawiły się zaburzenia widzenia, które również ustąpiły w czasie leczenia. Stwierdzono wymagające substytucji niedoczynność przysadki i moczówkę prostą, a także hiperprolaktynemię. W późniejszym czasie dołączyły się objawy brzuszne i w badaniu TK stwierdzono obustronne zmiany w nerkach i powiększenie pozaozronowych węzłów chłonnych. W badaniu histopatologicznym potwierdzono rozpoznanie rozlanego chłoniaka złośliwego i miejscowe zapalenie węzłów chłonnych. Następnie wy-

kazano obecność płynu w jamie opłucnej i przestrzeni pozaozronowej, a pacjent zmarł z powodu powikłań choroby zasadniczej. W opisywanym przypadku udokumentowano długie przeżycie od czasu rozpoznania nacieku okolicy podwzgórza i skrzyżowania wzrokowego w przebiegu chłoniaka, co jest rzadkością w chłoniakach ośrodkowego układu nerwowego. Z praktycznego punktu widzenia ważne są zaburzenia hormonalne towarzyszące nacieczeniu okolicy nadsiodłowej.

(*Endokrynol Pol* 2006; 6 (57): 642–647)

**Słowa kluczowe:** chłoniak, niedoczynność przysadki, hiperprolaktynemia, moczówka prosta, zaburzenia widzenia



Dr hab. med. Marek Bolanowski  
Katedra i Klinika Endokrynologii, Diabetologii  
i Leczenia Izotopami, Akademia Medyczna, Wrocław  
ul. Pasteura 4, 50-367 Wrocław  
tel.: 071 784 27 40, faks: 071 327 09 57  
e-mail: bolan@endo.am.wroc.pl



## Diffuse malignant lymphoma type B with optic chiasm infiltration, visual disturbances, hypopituitarism, hyperprolactinaemia and diabetes insipidus. Case report and literature review

Marek Bolanowski<sup>1</sup>, Małgorzata Kuliszkiewicz-Janus<sup>2</sup>, Violetta Sokolska<sup>3</sup>

<sup>1</sup>Department of Endocrinology, Diabetology and Isotope Therapy, Wrocław Medical University, Wrocław

<sup>2</sup>Department of Hematology, Oncology and Bone Marrow Transplantation, Wrocław Medical University, Wrocław

<sup>3</sup>Department of Radiology, Wrocław Medical University, Wrocław

### Abstract

The case is reported of a 55-year-old man with diffuse malignant lymphoma type B associated with transient optic chiasm infiltration and visual disturbances but with persistent hypopituitarism, hyperprolactinaemia and diabetes insipidus. The patient was administered chemotherapy and radiotherapy. Repeated MR and CT scans showed optic chiasm infiltration, which disappeared in the course of the chemotherapy but then recurred, changed its appearance and finally disappeared again. In the meantime visual disturbances occurred and disappeared during the therapy. Hypopituitarism, diabetes insipidus and hyperprolactinaemia were diagnosed and replacement therapy was administered. Later on abdominal pain occurred, and a CT scan revealed bilateral kidney masses and enlarged retroperitoneal lymph nodes. These were diffuse malignant lymphoma with regional lymphonodulitis in histology. Finally, hydrothorax and hydroretroperitoneum were diagnosed. The patient died as a result of systemic complications of the

disease. The length of survival time documented following the hypothalamochiasmatic infiltration and diagnosis of lymphoma makes the case an unusual one for patients with CNS lymphoma. Hormonal disturbances accompanying the suprasellar region infiltration are very important from the practical point of view.

(*Pol J Endocrinol* 2006; 6 (57): 642–647)

**Key words:** lymphoma, hypopituitarism, hyperprolactinaemia, diabetes insipidus, visual disturbances



Marek Bolanowski, M.D., Ph.D.,

Dept. of Endocrinology, Diabetology and Isotope Therapy  
Wrocław Medical University  
Pasteura 4, 50-367 Wrocław  
phone: 071 784 27 40, fax: 071 327 09 57  
e-mail: bolan@endo.am.wroc.pl

### Introduction

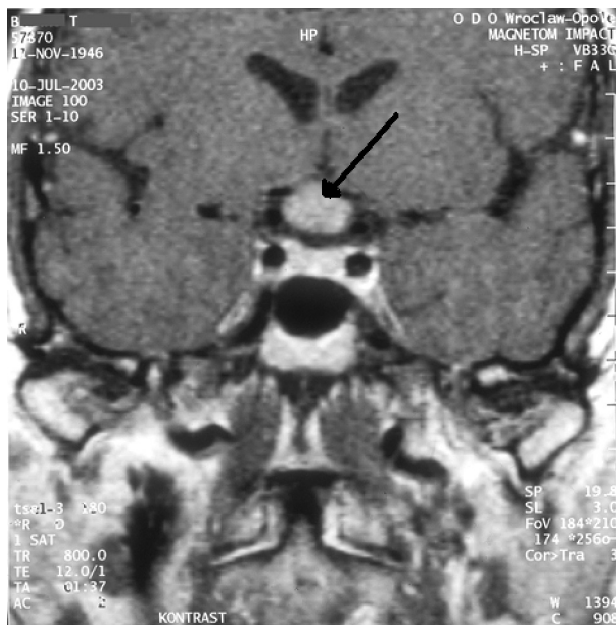
Malignant lymphoma is a generalised disorder with an ability to involve various organs. Lymphoma or leukaemia of the central nervous system (CNS) is most frequently meningeal and extradural, with intraparenchymal deposit being extremely rare. Histologically, lymphomas of the CNS are almost always non-Hodgkin's lymphomas with a diffuse rather than a follicular pattern, and the majority of them are B-cell tumours [1, 2]. Primary CNS lymphomas are not frequent and a pituitary localisation may be followed by hypopituitarism and other failures of the CNS. Several cases of primary pituitary lymphoma have been reported to date [3–5]. Pituitary lymphoma can also be a part of widespread systemic disease [6]. Optic chiasm infiltration by the lymphoma leads to various forms of visual disturbance. However, the reports of lymphomas located within the optic chiasm are limited in number [7, 8]. Primary

hypothalamic lymphomas are quite unusual; they can be followed by various symptoms including hypopituitarism and diabetes insipidus. Hypothalamic lymphomas can mimic in their symptomatology the pituitary ones, giving a clinical picture of pituitary hormone insufficiency [9, 10].

We present a case of diffuse malignant lymphoma associated with transient optic chiasm infiltration and transient visual disturbances, but combined with persistent hypopituitarism, hyperprolactinaemia and diabetes insipidus.

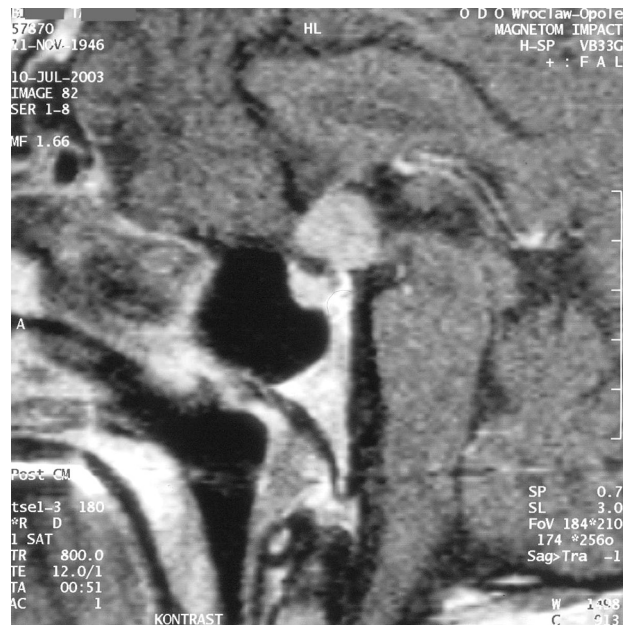### Case report

The onset of the disease in a 55-year-old man was in March 2001 with the enlargement of the left-side inguinal lymph nodes. Histological evaluation revealed *Lymphoma malignum lymphocyticum diffusum* type B II A, [CD 20 (+), CD 45 RO (+), Bcl-2 (-), Ki-67 (-)]. Between



**Figure 1a.** (MR 10.07.2003) Coronal contrast-enhanced T1-weighted MR image shows optic chiasm infiltration  $1.7 \times 1.3$  cm (arrow). Pituitary gland is normal

**Rycina 1a.** Obraz T1-zależny w projekcji czołowej wykonany po dożylnym podaniu kontrastu wykazuje nacieki skrzyżowania wzrokowego o wymiarach:  $1,7 \times 1,3$  cm (strzałka); przysadka mózgowa jest prawidłowa



**Figure 1b.** (MR 10.07.2003) The same examination: sagittal contrast-enhanced T1-weighted image; hyperintense mass in the suprasellar region

**Rycina 1b.** To samo badanie — obraz T1-zależny w projekcji strzałkowej po wzmocnieniu kontrastowym — w okolicy nadsiodłowej jest widoczna hiperintensywna masa

March 2001 and November 2002 he was administered seven cycles of COP (Cyclophosphamide, Vincristine, Prednisone), which was followed by remission of the disease. Some time later an enlargement of the inguinal and parotid lymph nodes occurred again, and a subsequent three cycles of chemotherapy, Cyclophosphamide, Vinblastine and Prednisone (CVP), were necessary. Neither signs nor symptoms of hypopituitarism or diabetes insipidus were present at this time.

In August 2003 visual disturbances (bitemporal hemianopsia) occurred suddenly. The magnetic resonance (MR) scan performed shortly before their occurrence (July 10<sup>th</sup> 2003) had already revealed optic chiasm infiltration with third ventricle compression. The pituitary gland was normal on the MR scan (Fig. 1a, b). Radiotherapy was discussed, but finally four cycles of CHOP (Cyclophosphamide, Epirubicine, Vincristine, Prednisone) were administered. This treatment was tolerated very badly; it caused weakness, electrolyte disturbances, nausea, vomiting, polydipsia and polyuria. The visual field defects disappeared gradually within this period and a subsequent MRI scan (September 1<sup>st</sup> 2003) showed complete regression of the lesion described previously (not shown). However, the signs and symptoms mentioned above (diabetes insipidus) intensified and were combined with those of hypopituitarism (weakness, hypotension, dry skin, constipation and impotence).

The computed tomography (CT) scan (November 6<sup>th</sup> 2003) again showed a suprasellar hyperdense focus 1.8 cm in size with contrast enhancement present (not shown). At that time no peripheral, mediastinal or retroperitoneal lymph nodes or neurological symptoms were observed. There was only pleocytosis of 6 cells/ml in the cerebrospinal fluid of 6 cells/ml, including 6 lymphoblasts. An additional intraspinal 12 cycles of chemotherapy (Cytarabine, Methotrexate, Prednisone) were administered between November 2003 and March 2004. The next MRI scan (November 28<sup>th</sup> 2003) confirmed the regression of infiltration (not shown), but the hormonal disturbances remained. The patient was then referred for positron emission tomography (PET) imaging of the whole body, which revealed no expansive changes within the skull, neck, chest, abdomen or pelvis (December 10<sup>th</sup> 2003, not shown). Hormonal and biochemical analyses confirmed secondary hypothyroidism, secondary adrenal insufficiency, hypogonadism, hyperprolactinaemia and central diabetes insipidus. The hormonal data of the patient are shown in Table I. Hormonal substitution was administered (L-Thyroxin, Hydrocortisone, Testosterone, Vasopressin) with very good clinical effect.

A subsequent MRI scan showed a 6 mm hypointensive lesion of the optic chiasm (March 17<sup>th</sup> 2004) (not shown), which was interpreted as a recrudescence of the disease, and radiotherapy using photons 6 MeV in a total dose of 36 Gy/20 was administered.

Table I

Results of hormonal and osmolal analyses in the patient with optic chiasm lymphoma infiltration before the hormonal replacement

Tabela I

Wyniki badań hormonalnych i osmolalności u chorego pacjenta z chłoniakiem naciekającym skrzyżowanie wzrokowe przed wdrożeniem substytucji hormonalnej

Test	Value	Normal range
TSH [mIU/l]	0.265	(0.4–4)
fT <sub>4</sub> [pmol/l]	5.57	(9–20)
ACTH [pg/ml]	5.0	(0–46)
Cortisol 08.00 [ng/ml]	11.6	(94–260)
Cortisol 20.00 [ng/ml]	12.8	(18–127)
LH [mU/ml]	1.53	(2–10)
FSH [mU/ml]	4.58	(2–15)
Testosterone [ng/ml]	< 0.5	(1.8–7.5)
GH [ng/ml]	0.39	(< 4)
Prolactin [ng/ml]	45.3	(3–15)
Urine osmolality [mOsm/kg]	211	(300–400)
Serum osmolality [mOsm/kg]	316	(284–293)

Complete remission of haematological disease continued until September 2004, and no chemotherapy was necessary. The last MRI scan (August 18<sup>th</sup> 2004) showed no pathological changes within the suprasellar region (Fig 2a and 2b) and reflected a complete withdrawal of the infiltration seen before.

In the meantime (October 2004) abdominal pain occurred, and the CT scan revealed bilateral kidney masses (right: 5 × 3.5 cm, left: 2 × 1.5 cm in diameter, respectively) and enlarged retroperitoneal lymph nodes (3 cm). The patient underwent right nephrectomy and left kidney tumour excision. There were diffuse malignant lymphomas with regional lymphonodulitis in histology. Later the patient received Vepesid, DHAD, Fludrabin and Dexavene. In February 2005 hydrothorax and hydroretroperitoneum were diagnosed, and DHAD was applied intrapleurally. CDA was then given twice without success. From April 2005 the patient did not continue follow-up and finally died in September 2005 as a result of systemic complications of the disease. Until April 2005 the patient's visual field and acuity had shown no further impairment and he had received continuous hormonal replacement.

Our patient, showing signs of transitory visual deficits and permanent hypopituitarism, diabetes insipidus and mild hyperprolactinaemia, is not typical, since his pituitary was intact in all MR or CT images, and the hypopituitarism observed was secondary to the

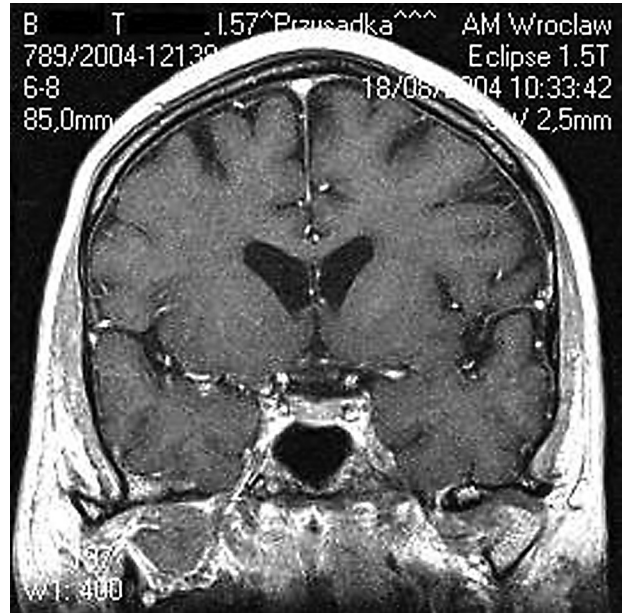


Figure 2a. (MR 18.08.2004) Coronal contrast-enhanced T1-weighted MR image shows no pathological changes within the suprasellar region. Optic chiasm is still normal; regression of the lesion

Rycina 2a. Obraz T1-zależny w projekcji czołowej wykonany po dożylnym podaniu kontrastu nie wykazuje zmian w okolicy nadsiodłowej; skrzyżowanie wzrokowe jest prawidłowe; regresja nacieku

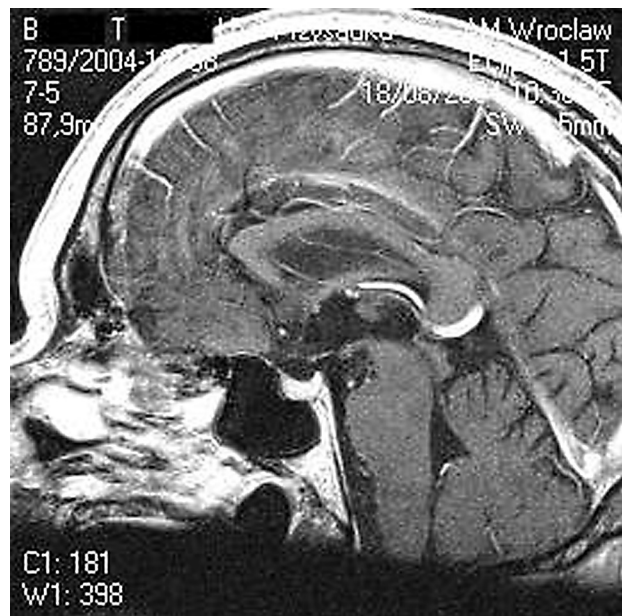


Figure 2b. (MR 18.08.2004) The same examination: sagittal contrast-enhanced T1-weighted image. Complete regression of the lesion within the optic chiasm

Rycina 2b. To samo badanie — obraz T1-zależny w projekcji strzałkowej po wzmocnieniu kontrastowym; całkowita regresja nacieku skrzyżowania wzrokowego

hypothalamic infiltration. The visual disturbances were parallel to pathological changes in the optic chiasm region described on scans, but the hormonal deficiencies remained persistent during the follow-up time owing to hypothalamus failure.

The follow-up of the lesion images in our case is very interesting. The infiltration disappeared in the course of the chemotherapy, but recurred, then changed its appearance (from hyperdense with contrast enhancement into hypodense without contrast enhancement) and finally disappeared again. This patient survived for over two years after hypothalamochiasmatic infiltration was documented (July 2003–September 2005) and for four years after lymphoma had been diagnosed (March 2001), which is quite unusual for patients with CNS lymphoma. Hormonal disturbances accompanying the suprasellar region infiltration are very important from the practical point of view.

## Discussion

Pituitary lesions secondary to other disorders are not common. They may reveal tumours metastatic to the pituitary gland, pituitary infiltration, or lymphoma. Neoplasms from almost every origin have been reported to metastasise to the pituitary. These tumours reflect most commonly breast and lung cancers in women and men respectively. The remaining metastases are of gastrointestinal, prostate, kidney, skin, thyroid and other origin. All pituitary metastases are less than 1% of tumorous pituitary lesions subjected to pituitary tumour surgery. They can diminish together with successful chemotherapy of the primary focus. Pituitary involvement can exert both mass effect and induce hormonal disturbances. The former is reflected in visual field defects and vision loss, while the latter leads to pituitary deficiencies with concomitant hyperprolactinaemia and diabetes insipidus when hypothalamic function is disturbed [11–13].

In a review of the location of metastasis to the pituitary gland in 201 cases an involvement of the posterior lobe either alone or in combination with the anterior lobe was found in 84.6%, whereas only the anterior lobe was affected in 15.4% [13]. The most common symptom seems to be diabetes insipidus, reflecting a predominance of metastasis to the posterior lobe [12]. In a review of 40 symptomatic cases diabetes insipidus was noted in 70%, whereas only 15% had one or more anterior pituitary hormone deficiencies [13]. However, recent studies show a higher rate of anterior pituitary involvement (23.6%) [12]. Ntyonga-Pono et al., reviewing 72 patients from the literature, found that only 10% of patients survived more than one year after diagnosis, the longest survival being three years. Patients with

a single pituitary metastasis may have a better outcome (2.5 years) [14].

A large series reported of carcinoma metastatic to the pituitary gland does not mention lymphoma, although it does report 4 of 220 (1.9%) cases of leukaemia metastatic to the pituitary [13]. A haematological origin of a primary tumour metastatic to the pituitary in 380 cases included: leukaemia — 5 cases (1.3%), multiple myeloma — 3 (0.8%), lymphoma — 2 (0.5%) and lymphosarcoma — 1 (0.3%) [12]. On the other hand, lymphomas or other haematological malignancies involving the CNS were found in 8 out of 119 patients (6.7%) aged 75 and older undergoing neurosurgical interventions [15]. The number of CNS lymphomas has increased recently owing to the increasing number of patients suffering from AIDS and immunosuppression [9]. In an autopsy series carried out on 165 patients who had died because of haematological malignancies 38 cases (23%) of pituitary lymphoma were found [16].

Lymphomas of the pituitary and suprasellar region can be of primary origin or reflect the whole-body dissemination of the general disease [6, 17]. Primary pituitary lymphomas are not frequent; they present with mass effects, transient or permanent endocrinopathies, headache, cranial nerve abnormalities and also fever [18]. Several cases of primary pituitary lymphoma have been reported to date. They are sometimes diagnosed after trans-sphenoidal biopsy, neurosurgery or postmortem [2, 19–21] and the majority of them represent B-cell non-Hodgkin's lymphoma [17, 18]. For example, a diffuse pleomorphic B-cell lymphoma with diabetes insipidus was diagnosed primarily in the pterygopalatine fossa on both sides with infiltration of the clivus, cavernous sinus and neurohypophysis. Diabetes insipidus disappeared following chemotherapy [22]. Non-Hodgkin's lymphoma can involve both hypophysis, with symptoms of anterior pituitary failure, and the adrenals [23]. Several cases of active acromegaly associated with intrasellar lymphoma and also CNS lymphoma in the course of GH therapy have been described, suggesting the role of IGF-1 in the tumorigenesis [24, 25].

Other pituitary lesions include infiltrative ones, and these can involve lymphocytic hypophysitis, sarcoidosis, tuberculosis, histiocytosis X and pituitary abscesses. These lesions require specific and targeted treatment [12, 26, 27].

Optic nerve and chiasm involvement by the lymphoma is unusual, and generally occurs late in the course of the disease. There are a few cases reported in the literature of both non-Hodgkin's and Hodgkin's lymphoma in this location, often with visual loss. Other symptoms could be headaches or decreased hearing [7, 8, 28]. These lesions can develop without any endocrinological disturbances. The proper diagnosis was usually

given following mass surgery, biopsy or postmortem evaluation. Some of these lesions respond well to steroid therapy [7, 29, 30].

Primary hypothalamic lymphomas are considered quite exceptional. There are reports of lesions of either the third ventricle region and adjacent hypothalamic area, with progressive visual deterioration, diabetes insipidus and mental confusion [10], or the hypothalamic/chiasmal mass with visual loss, hypopituitarism and the stiff-man syndrome [31]. Our case is very similar to these, sharing the localisation and clinical picture of both the above-mentioned reports. In contrast, however, it does not represent primary hypothalamic lymphoma but the hypothalamo/chiasmatic spread of the diffuse disease.

Hyperprolactinaemia has been reported to accompany metastases to the posterior pituitary and infundibulum as a result of stalk compression, and the degree of hyperprolactinaemia may be helpful in distinguishing the above-mentioned disturbances from a true prolactinoma [12]. On the other hand, hyperprolactinaemia has been observed in patients with advanced multiple myeloma as an atypical marker of the disease [32].

## References

- Paulus W. Classification, pathogenesis and molecular pathology of primary CNS lymphomas. *J Neurooncol* 1999; 43: 203–208.
- Mathiasen RA, Jarrahy R, Cha ST et al. Pituitary lymphoma: a case report and literature review. *Pituitary* 2000; 4: 283–287.
- Campeau RJ, David O, Dowling AM. Pituitary adenoma detected on FDG positron emission tomography in a patient with mucosa-associated lymphoid tissue lymphoma. *Clin Nucl Med* 2003; 28: 296–298.
- Gottfredsson M, Oury TD, Bernstein C et al. Lymphoma of the pituitary gland: an unusual presentation of central nervous system lymphoma in AIDS. *Am J Med* 1996; 101: 563–564.
- Singh VP, Mahapatra AK, Dinde AK. Sellar-suprasellar primary malignant lymphoma: case report. *Indian J Cancer* 1993; 30: 88–91.
- Delpirou C, Heroum C, Milhaud D et al. Pituitary tumour as a presenting symptom of a systemic lymphoma. *Rev Neurol* 2003; 159: 790–792.
- McFadzean RM, McIlwaine GG, McLellan D. Hodgkin's disease at the optic chiasm. *J Clin Neuroophthalmol* 1990; 10: 248–254.
- Zaman AG, Graham EM, Sanders MD. Anterior visual system involvement in non-Hodgkin's lymphoma. *Br J Ophthalmol* 1993; 77: 184–187.
- Lee AG, Tang RA, Roberts D et al. Primary central nervous system lymphoma involving the optic chiasm in AIDS. *J Neuroophthalmol* 2001; 21: 95–98.
- Pascual JM, Gonzales-Llanos F, Roda JM. Primary hypothalamic-third ventricle lymphoma. Case report and the review of the literature. *Neurocirurgia (Astur)* 2002; 13: 305–310.
- Freda PU, Wardlaw SL, Post KD. Unusual causes of sellar/parasellar masses in a large transsphenoidal surgical series. *J Clin Endocrinol Metab* 1996; 81: 3455–3459.
- Komninos J, Vlassopoulou V, Protopapa D et al. Tumors metastatic to the pituitary gland: case report and literature review. *J Clin Endocrinol Metab* 2004; 89: 574–580.
- McCormick PC, Post KD, Kandji AD et al. Metastatic carcinoma to the pituitary gland. *Br J Neurosurg* 1989; 3: 71–79.
- Ntyonga-Pono MP, Thomopoulos P, Luton JP. Pituitary metastases. Three cases. *Presse Med* 1999; 28: 1567–1571.
- Kleinschmidt-DeMasters BK, Lillehei KO, Breeze RE. Neoplasms involving the central nervous system in the older old. *Hum Pathol* 2003; 34: 1137–1147.
- Buchmann E, Schwesinger G. The hypophysis and hemoblastoses. *Zentralbl Neurochir*, 1979; 40: 35–42.
- Giustina A, Gola M, Doga M et al. Primary lymphoma of the pituitary: an emerging clinical entity. *J Clin Endocrinol Metab* 2001; 86: 4567–4575.
- Landman RE, Wardlaw SL, McConnell RJ et al. Pituitary lymphoma presenting as fever of unknown origin. *J Clin Endocrinol Metab* 2001; 86: 1470–1476.
- Katz BJ, Jones RE, Digre KB et al. Panhypopituitarism as an initial manifestation of primary central nervous system non-Hodgkin's lymphoma. *Endocr Pract* 2003; 9: 296–300.
- Onda K, Wakabayashi K, Tanaka R et al. Intracranial malignant lymphomas: clinicopathological study of 26 autopsy cases. *Brain Tumor Pathol* 1999; 16: 29–35.
- Samaratunga H, Perry-Keene D, Apel RL. Primary lymphoma of the pituitary gland: a neoplasm of acquired MALT? *Endocr Pathol* 1997; 8: 335–341.
- Breidert M, Schimmelpfennig C, Kittner T et al. Diabetes insipidus in a patient with a highly malignant B-cell lymphoma and stomatitis. *Exp Clin Endocrinol Diabetes* 2000; 108: 54–58.
- Li JK, Chow CC, Yeung VT et al. Adrenal and hypophyseal non-Hodgkin's lymphoma presenting with panhypopituitarism. *Int J Clin Pract* 1998; 52: 513–514.
- Alves RH, Vaisman M, Brasil RR et al. Acromegaly and non-Hodgkin's lymphoma. *Endocr Pract* 1998; 4: 279–281.
- Capra M, Wherrett D, Weitzman S et al. Pituitary stalk thickening and primary central nervous system lymphoma. *J Neurooncol* 2004; 67: 227–231.
- Burt MG, Morey AL, Turner JJ et al. Xanthomatous pituitary lesions: a report of two cases and review of the literature. *Pituitary* 2003; 6: 161–168.
- Kanou Y, Arita K, Kurisu K et al. Infundibuloneurohypophysitis presenting a large sellar-juxtaseellar mass: case report. *Surg Neurol* 2004; 61: 278–281.
- Cantore GP, Raco A, Artico M et al. Primary chiasmatic lymphoma. *Clin Neurol Neurosurg* 1989; 91: 71–74.
- Gray RS, Abrahams JJ, Hufnagel TJ et al. Ghost-cell tumor of the optic chiasm. Primary CNS lymphoma. *J Clin Neuroophthalmol* 1989; 9: 98–104.
- Miller NR, Iliff WJ. Visual loss as the initial symptom in Hodgkin disease. *Arch Ophthalmol* 1975; 93: 1158–1161.
- Lee MT, Lee TI, Won JG et al. Primary hypothalamic lymphoma with panhypopituitarism presenting as stiff-man syndrome. *Am J Med Sci* 2004; 328: 124–128.
- Gado K, Rimanoczi E, Hasitz A et al. Elevated levels of serum prolactin in patients with advanced multiple myeloma. *Neuroimmunomodulation* 2001; 9: 231–236.