



# Acromegaly in a patient with normal pituitary gland and somatotrophic adenoma located in the sphenoid sinus

Akromegalia u chorego z prawidłową przysadką i gruczolakiem somatotropowym położonym w zatoce klinowej

**Maria Kurowska<sup>1</sup>, Jerzy S. Tarach<sup>1</sup>, Wojciech Zgliczyński<sup>2</sup>, Joanna Malicka<sup>1</sup>, Grzegorz Zieliński<sup>3</sup>, Marzena Janczarek<sup>4</sup>**

<sup>1</sup>Department of Endocrinology, Medical University, Lublin, Poland

<sup>2</sup>Department of Endocrinology, Centre for Postgraduate Medical Education, Warsaw, Poland

<sup>3</sup>Department of Neurosurgery, Medical Military Institute, Warsaw, Poland

<sup>4</sup>Department of Neuroradiology, Medical University, Lublin, Poland

## Abstract

Ectopic acromegaly is a very rare clinical entity occurring in less than 1% of acromegalic patients. In most cases it is caused by GHRH or rarely GH-secreting neoplasms. Even rarer are ectopic pituitary adenomas located in the sphenoid sinus or nasopharynx that originate from pituitary remnants in the craniopharyngeal duct. This dissertation presents the difficulties in visualizing GH-secreting adenoma located in the sphenoid sinus.

A 55-year-old man had somatic features of acromegaly for several years. MRI imaging revealed a slightly asymmetric pituitary gland (14 × 4 mm) without focal lesions. Simultaneously, a spherical mass, 10 mm in diameter, corresponding with ectopic microadenoma was demonstrated on the upper wall of the sphenoid sinus. The serum GH level was 4.3 μg/l, IGF-1 = 615 μg/l, and a lack of GH suppression with oral glucose was proven. After preliminary treatment with a long-acting somatostatin analogue, transsphenoidal pituitary tumour removal was performed. Histopathological, electron microscopical and immunohistochemical analysis revealed densely granulated somatotrophic pituitary adenoma: GH(+), PRL(-), ACTH(-), TSH(-), FSH(-), LH(-), MIB1 < 1%, SSTR3(+) and SSTR5(+). Post-surgical evaluation showed normal pituitary MRI scans, GH and IGF-1 levels 0.18 μg/l and 140 μg/l, respectively, as well as normal GH suppression with oral glucose.

The careful analysis of possible pituitary embryonic malformations points out their significance for proper localization of extrapituitary adenomas. (*Pol J Endocrinol* 2008; 59 (4): 348–351)

**Key words:** acromegaly, ectopic somatotrophic adenoma, sphenoid sinus

## Streszczenie

Ektopowa postać akromegalii występuje u mniej niż 1% chorych. W większości przypadków jest ona spowodowana wydzielaniem GHRH lub sporadycznie GH przez guz nowotworowy. Jeszcze rzadsze są ektopowo położone gruczolaki przysadki. Zlokalizowane najczęściej w zatoce klinowej lub nosogardzieli, rozwijają się z fragmentu przysadki pozostałego w przewodzie czaszkowo-gardłowym. Prezentowana praca ukazuje trudności w wizualizacji gruczolaka somatotropowego położonego w zatoce klinowej.

Mężczyzna w wieku 55 lat z somatycznymi cechami akromegalii od kilkunastu lat. W MRI przysadka nieco asymetryczna, 14 × 4 mm, bez zmian ogniskowych. Na górnej ścianie zatoki klinowej obecny kulisty obszar o średnicy 10 mm odpowiadający mikrogruczolakowi. Stężenie GH = 4,3 μg/l, IGF-1 = 615 μg/l, brak hamowania GH glukozą. Po przygotowaniu długodziałającym analogiem somatostatynny guz usunięto z dostępu przez zatokę klinową. Badania histopatologiczne, elektronomikroskopowe oraz immunohistochemiczne wykazały obecność bogatoziarnistego somatotropowego gruczolaka przysadki: GH(+), PRL(-), ACTH(-), TSH(-), FSH(-), LH(-), MIB1 < 1%, SSTR3(+), SSTR5(+). W ocenie pooperacyjnej: prawidłowy obraz przysadki w MRI, GH = 0,18 μg/l; IGF-1 = 140 μg/l, obecne hamowanie GH glukozą.

Staranna analiza możliwych zaburzeń rozwoju embrionalnego przysadki potwierdza ich znaczenie dla prawidłowej lokalizacji pozaprzysadkowo położonych gruczolaków. (*Endokrynol Pol* 2008; 59 (4): 348–351)

**Słowa kluczowe:** akromegalia, ektopowy gruczolak somatotropowy, zatoka klinowa



Maria Kurowska, M.D., Ph.D., Department of Endocrinology, Medical University, ul. Jaczewskiego 8, 20-952 Lublin, tel.: +48 (081) 724 46 68, faks: +48 (081) 724 46 69, e-mail: mariakurowska@op.pl

## Introduction

Ectopic acromegaly is recognized in less than 1% of acromegalic patients. Most cases are caused by extrapituitary tumours, mainly bronchial or pancreatic carcinoids, secreting GHRH or, very rarely, GH [1]. In exceptionally rare instances, acromegaly is caused by extrasellar intracranial adenomas located at the skull base, the hypothalamic region, pituitary stalk and suprasellar space, which originate from cell remnants of the sellar pituitary gland (intracranial ectopy), as well as by adenomas outside the cranial cavity, developing from the pharyngeal pituitary or residual pituitary tissue in the craniopharyngeal duct (extracranial ectopy). Extracranial adenomas are most often situated in the sphenoid sinus and the sphenoid bone, and less often in the soft tissues of the dorsal pharynx and in the sphenoid bone clivus [2, 3]. From the first description by Erdheim et al. in 1909 until 2003, 74 cases of extrasellar pituitary tumour were reported in literature. These tumours were located mainly in the sphenoid sinus and the suprasellar region. The majority of them did not show hormonal activity or secreted ACTH. There were only five somatotrophic adenomas among them: two situated in the sphenoid sinus, two in the suprasellar region and one within the nasopharynx [4]. Moreover, the downward expansion of the intrasellar adenoma throughout the damaged sellar floor may be another reason for the presence of the tumour in the sphenoid sinus. The adenoma "falls" into the sphenoid sinus due to the pulsations of intracranial cerebrospinal fluid pressure [5, 6].

The aim of the study was to present a patient with a normal pituitary gland and acromegaly in the course of a somatotrophic adenoma located in the sphenoid sinus, to discuss the difficulties with its identification and to recall the basic knowledge related to the embryonic development of the pituitary in order to emphasize its significance for the establishment of a correct diagnosis.

## Case report

We describe the case of a 55-year-old man who had increased somatic symptoms of acromegaly for 15 years: the coarsening of facial features, enlargement of the hands, feet, nose, lips, tongue, jaw and forehead. He complained of fatigue, effort intolerance, hyperhidrosis and sleep apnea syndrome and had been treated for arterial hypertension for several years. He also suffered from general joint pain, carpal tunnel syndrome and gradual lowering of the voice. Acromegaly was diagnosed two years ago based on the clinical picture. MRI imaging revealed a slightly asymmetric pituitary gland (14 × 4 mm) without focal lesions, and the spherical mass, 10 mm in diameter, revealed on the upper wall of

the sphenoid sinus was described as a "polypus of the sphenoid sinus". At that time, the source of excessive hormone production was not determined. In March 2005 the patient, suspected of ectopic acromegaly, was admitted to the Department of Endocrinology. Physical examination confirmed somatic symptoms of acromegaly; a nodular goitre was also found. Ultrasound scanning of the thyroid gland revealed a heterogeneous nodule with fluid spaces and calcifications in the central and lower parts of the left lobe. The nodule was "cold" during scintigraphy and considered benign according to FNAB classification. Euthyroidism was confirmed. OGTT excluded carbohydrate metabolism disorders. Serum testosterone, LH, FSH and PRL levels were normal. GH concentration remained at a high-normal level. However, a paradoxical GH increase in the OGTT, as well as a double excess of IGF-1 above the age- and sex-appropriate limits, was found and confirmed the diagnosis of acromegaly.

Once again, no abnormalities of the pituitary size or any focal lesions were shown in MR imaging. Somatostatin receptor scintigraphy (SPECT) revealed radioactive tracer uptake only by the anterior pituitary. Therefore, suspicion of an ectopic source of GH production was excluded, and the low-normal size of the pituitary did not indicate excessive GHRH secretion. The abnormal mass in the sphenoid sinus, which had been described earlier, was once more defined as a "polypus". The local neurosurgeon accepted the neuroradiologist's diagnosis and decided not to operate on the patient. Finally, based on another consultation and MRI imaging, pituitary microadenoma was recognized and the patient was qualified for transsphenoidal adenectomy. After pretreatment with long-acting somatostatin analogue, the operation was performed. Histopathological, electron microscopical and immuno-histochemical analysis revealed a somatotrophic pituitary adenoma: GH(+), PRL(-), ACTH(-), TSH(-), FSH(-), LH(-), MIB1 < 1%, SSTR3(+), SSTR5(+). The normal pituitary image, the normalization of GH and IGF-1 levels, and the restoration of GH glucose suppression were confirmed six months later. The patient was considered cured of acromegaly, with the pituitary function preserved. The pre- and post-surgical results of diagnostic procedures are presented in Table I and Figure 1, respectively.

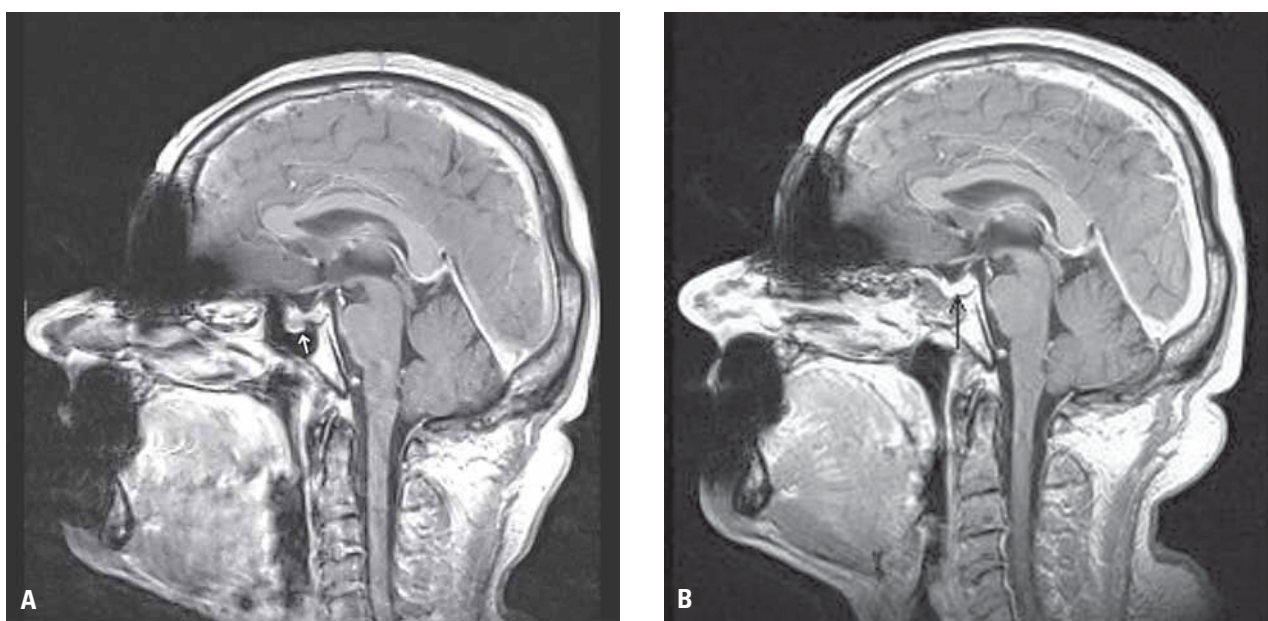
## Discussion

Developmental disorders of the glandular pituitary are a common phenomenon [4, 7]. The primordium of the pituitary gland appears in the fourth week of gestation [3]. The glandular part develops between the sixth and the twelfth week of the foetal life from the ectodermal

Table I. Pre- and post-surgical results of the hormonal and imaging tests

Tabela I. Wyniki badań hormonalnych i obrazowych przed i po zabiegu chirurgicznym

Parameter	Pre-surgical study	Post-surgical study
GH [ $\mu\text{g/l}$ ] (n. 0.06–5.0)	4.3	0.18
IGF-1 [ $\mu\text{g/l}$ ] (n. 87–238)	615	140
GH [ $\mu\text{g/l}$ ] OGTT	4.3 $\rightarrow$ 7.1	0.66 $\rightarrow$ 0.08
Pituitary MRI imaging	I. Slightly heterogeneous and asymmetric pituitary gland (14 $\times$ 4 mm) without focal lesions. Pituitary stalk located symmetrically. A spherical mass on the upper wall of the sphenoid sinus, 10 mm in diameter, not gadolinium enhanced, described first as a "polypus" II. Pituitary adenoma confined to the sphenoid sinus	Normal sized (14 $\times$ 4 mm) symmetrical pituitary gland without stalk deviation. Uniformly enhanced signal intensity.



**Figure 1A.** Sagittal gadolinium — enhanced MRI images of the pituitary gland and a spherical mass corresponding with ectopic microadenoma on the upper wall of the sphenoid sinus. **B.** Post-surgery sagittal MR images of the pituitary gland

**Rycina 1A.** W badaniu MRI ze wzmocnieniem kontrastowym (gadolin) widoczna przysadka mózgowa oraz kulista masa na górnej ścianie zatoki klinowej odpowiadająca ektopowemu mikrogruczolakowi. **B.** Obraz przysadki mózgowej w MRI wykonanym po zabiegu chirurgicznym

diverticulum of the oral cavity fornix. This process is connected with the migration of the ectodermal layer towards the neuroectodermal lamina, the remnant of which composes the craniopharyngeal duct. In the eighth week of gestation the primary pituitary separates into the sellar and pharyngeal parts. Developmental disorders of the glandular part include a double pituitary gland, lack of primary pituitary separation (pharyngosellar pituitary) and migration of the pituitary cells to the subarachnoid space. Life-long existence of the pharyngeal pituitary, causing no pathological symptoms, occurs in many healthy people [3]. The ectopic pituitary adenoma is defined as originating from outside the sellar pituitary and as having no connection with

its glandular part [1, 4, 7, 8]. MRI helps to prove the absence of the connection between the tumour and the sellar pituitary and to differentiate invasive and ectopic pituitary adenomas based on the presence of intact dura mater of the sellar floor. Differential diagnosis should also take into account: mucous cysts of the sphenoid sinus, chordoma, chondroma, chondrosarcoma, melanoma, lymphoma, tumour metastasis and tumours of the nasopharynx [7, 8]. Acromegaly due to somatotrophic adenoma located in the sphenoid sinus, regardless of its nature (invasive or ectopic), in a patient with a normal sellar pituitary, constitutes a very rare clinical entity [5, 8, 9]. The normal size of the pituitary made it possible to exclude stimulation by ectopic GHRH. The

MRI visible tissue stria connecting the tumour with the pituitary indicated that it could have originated from the glandular part of the sellar pituitary and migrated ("fallen") through the damaged sella floor into the sphenoid sinus, as suggested Hori et al. [5] in the case of their patient. Downward pulling by the tumour may have caused the indentation on the upper surface of the pituitary present in our patient. The empty sella, which could provide a different explanation for this symptom and which has been described in only six acromegalic patients with an ectopic sphenoid sinus adenoma [5, 8-10], was not found in our patient. Simultaneously, it cannot be definitively excluded that the adenoma developed from the residual pharyngeal pituitary fragment which was not completely separated from the sellar part during foetal life. The reasons for the misdiagnosis of the tumour during the radiological study may have been not only its atypical location but also its spherical shape and the presence of a tissue "peduncle". These features suggested the "sphenoid sinus polypus", which is most frequent in initial diagnosis in such patients [11]. The sphenoid sinus mucose polyps are also recognized in acromegaly quite often [12]. The tumour was characterized by a relatively low density on the T1 and T2 MRI images, and did not undergo considerable contrast enhancement. Similar features related to both parts of the tumour and an entire tumour located in the sphenoid sinus were observed by Ishi et al. [13]. An abundant fibrosis found in the samples from the tumour or its parts penetrating into the sphenoid sinus and not demonstrated by the intra- and suprasellar parts of the adenoma was responsible for such an image [13]. The adenoma did not show tracer uptake in somatostatin-receptor scintigraphy SPECT, making its identification even more difficult. Positive results of Sandostatin LAR treatment have proven the presence of somatostatin receptors within the tumour, which in turn confirms the fact that a negative scintigraphy result does

not exclude the susceptibility of the adenoma to such treatment [4, 14]. Ignoring the possibility of its ectopic location caused the incorrect preliminary qualification of the sphenoid sinus lesion and the difficulties with the proper adenoma location.

## Conclusions

The careful analysis of possible pituitary embryonic malformations pointed out their significance for proper localization of atypically placed adenomas.

## References

1. Faglia G, Arosio M, Bazzoni N. Ectopic acromegaly. *Endocrinol Metab Clin North Am* 1992; 21: 575-595.
2. Hori A, Schmidt D, Rickels E. Pharyngeal pituitary: development, malformation, and tumorigenesis. *Acta Neuropathol (Berlin)* 1999; 98: 262-272.
3. Hori A, Schmidt D, Kuebber S. Immunohistochemical survey of migration of human anterior pituitary cells in developmental, pathological, and clinical aspects: a review. *Microsc Res Tech* 1999; 46: 59-68.
4. Pugnale N, Waridel F, Bouzourène H et al. Pharyngeal pituitary non-functioning adenoma with normal intra-sellar gland: massive tumor shrinkage on octreotide therapy. *Eur J Endocrinol* 2003; 148: 357-364.
5. Hori E, Akai T, Kurimoto M et al. Growth hormone-secreting pituitary adenoma confined to the sphenoid sinus associated with a normal-sized empty sella. *J Clin Neurosci* 2002; 9: 196-199.
6. Langford L, Batsakis JG. Pituitary gland involvement of the sinonasal tract. *Ann Otol Rhinol Laryngol* 1995; 104: 167-169.
7. Warczyńska A, Zieliński G, Koziarski SA et al. Ectopic pituitary adenoma. Case report and review of literature. *Neurol Neurochir Pol.* 2002; 36: 1185-1196.
8. Gondim JA, Schops M, Ferreira E et al. Acromegaly due to an ectopic pituitary adenoma in the sphenoid sinus. *Acta Radiol* 2004; 45: 689-691.
9. Matsuno A, Katayama H, Okazaki R et al. Ectopic pituitary adenoma in the sphenoid sinus causing acromegaly associated with empty sella. *ANZ J Surg* 2001; 71: 495-498.
10. Chan MR, Ziebert M, Maas DL et al. "My rings won't fit anymore". Ectopic growth hormone-secreting tumor. *Am Fam Physician* 2005; 71: 1766-1767.
11. Sethi DS, Lau DP, Chee LW et al. Isolated sphenoid recess polyps. *J Laryngol Otol* 1998; 112: 660-663.
12. Skinner DW, Richards SH. Acromegaly — the mucosal changes within the nose and para-nasal sinuses. *J Laryngol Otol* 1988; 102: 1107-1110.
13. Ishii K, Ikeda H, Takahashi S et al. MR imaging of pituitary adenomas with sphenoid sinus invasion: characteristic MR findings indicating fibrosis. *Radiat Med* 1996; 14: 173-178.
14. Plöckinger U, Bäder M, Hopfenmüller W et al. Results of somatostatin receptor scintigraphy do not predict pituitary tumor volume — and hormone-response to octreotide therapy and do not correlate with tumor histology. *Eur J Endocrinol* 1997; 136: 369-376.