



Normal bone turnover markers in a patient with active Paget's disease of bone: response to treatment with zoledronic acid

Prawidłowe stężenia markerów obrotu kostnego u pacjenta z aktywną chorobą kości Pageta — odpowiedź na leczenie kwasem zoledronowym

Stergios A. Polyzos^{1,2}, Athanasios D. Anastasilakis³, Panagiotis Anagnostis², Marina Kita², Georgios Arsos⁴, Efstathios Moralidis⁴, Athanasios Papatheodorou⁵, Evangelos Terpos⁶

¹Second Medical Clinic, Medical School, Aristotle University of Thessaloniki, Ippokraton Hospital, Thessaloniki, Greece

²Department of Endocrinology, Ippokraton General Hospital, Thessaloniki, Greece

³Department of Endocrinology, 424 General Military Hospital, Thessaloniki, Greece

⁴Department of Nuclear Medicine, Aristotle University, Ippokraton General Hospital, Thessaloniki, Greece

⁵Department of Medical Research, 251 General Airforce Hospital, Athens, Greece

⁶Department of Clinical Therapeutics, University of Athens School of Medicine, Athens, Greece

Abstract

The treatment of Paget's disease of bone (PDB) aims at the suppression of abnormal bone turnover; bisphosphonates are currently the treatment of choice. Indications for antiresorptive treatment in symptomatic patients with PDB include bone or joint pain, neurological complications, surgery planned at an active pagetic site and hypercalcaemia from immobilisation. The goals of antiresorptive treatment are clinical improvement and biochemical remission, as assessed by the normalisation of bone turnover markers. Clinical deterioration, especially bone pain, should be considered before deciding to treat patients with late sclerotic ('burned-out') PDB. Bone scintigraphy may be of importance in these patients, because it depicts increased osteoblastic activity, when bone markers may not. We present a case of late sclerotic PDB with clinical deterioration but normal bone turnover markers, who experienced significant clinical improvement after treatment with zoledronic acid. (*Endokrynol Pol* 2012; 63 (4): 312–315)

Key words: bisphosphonate, bone scintigraphy, bone-specific alkaline phosphatase, C-terminal telopeptide of type I collagen, Paget's disease of bone, zoledronic acid

Streszczenie

Celem leczenia choroby kości Pageta (PDB) jest zahamowanie zwiększonego obrotu kostnego. Obecnie lekami z wyboru są bisfosfoniary. Do wskazań do stosowania leków antyresorpcyjnych u pacjentów z objawową postacią PDB należą: bóle kostne i stawowe, powikłania neurologiczne, planowany zabieg chirurgiczny w rejonie aktywnych zmian chorobowych i hiperkalcemia spowodowana unieruchomieniem. Celem terapii antyresorpcyjnej jest uzyskanie poprawy stanu klinicznego i remisji biochemicznej, ocenianej na podstawie normalizacji stężeń biomarkerów obrotu kostnego. Przed podjęciem decyzji o wdrożeniu terapii u chorych w późnej, sklerotycznej fazie choroby (*burned out*) należy wziąć pod uwagę pogorszenie stanu klinicznego, a zwłaszcza występowanie bólów kostnych. U tych chorych duże znaczenie ma badanie scyntygraficzne kości, ponieważ może ono uwidocznić zwiększoną aktywność osteoblastyczną, której mogą nie wykazać markery obrotu kostnego. W niniejszej pracy przedstawiono przypadek chorego w późnym, sklerotycznym stadium PDB, u którego występowały nasilone objawy kliniczne, lecz stężenia markerów obrotu kostnego były prawidłowe. Po leczeniu kwasem zoledronowym nastąpiła istotna poprawa kliniczna. (*Endokrynol Pol* 2012; 63 (4): 312–315)

Słowa kluczowe: bisfosfoniary, scyntygrafia kości, izoenzym kostny fosfatazy alkalicznej, C-końcowy telopeptyd kolagenu typu I, choroba Pageta kości, kwas zoledronowy

Introduction

Paget's disease of bone (PDB) is the second commonest metabolic bone disease, after osteoporosis. PDB is a chronic disorder characterised by focally high bone remodelling, with abnormalities in all the phases of the remodelling cycle, although the primary abnormality

is believed to lie in the regulation of osteoclasts, which are increased in both number and size [1–3]. The treatment of PDB aims at the suppression of abnormal bone turnover, and bisphosphonates (BPs) are currently the treatment of choice [1, 4, 5]. Zoledronic acid (ZOL) leads to quicker and more sustained therapeutic response compared to other BPs such as risedronate [6, 7] or



Stergios A. Polyzos, 13 Simou Lianidi, 551 34 Thessaloniki, Greece, tel/fax: +30 231 042 47 10; e-mail: stergios@endo.gr

pamidronate [8]. Besides clinical improvement and biochemical remission, a favourable scintigraphic response evident as early as three months after treatment with ZOL has been reported in patients with PDB [9].

Indications for antiresorptive treatment in symptomatic patients with PDB include bone or joint pain, neurological complications, surgery planned at an active pagetic site and hypercalcaemia from immobilisation [4, 5]. The goals of antiresorptive treatment are clinical improvement and biochemical remission, as assessed by the normalisation of bone turnover markers [10]. The increased levels of bone markers are generally believed to reflect the rate of bone remodelling and correlate directly with the extent of the skeletal involvement [11]. Total serum alkaline phosphatase (ALP) is the most used marker in clinical practice, because it reflects the disease activity and treatment efficacy and, additionally, it is cheap, widely available, and has a low inter-assay variability [4].

We hereby present a case of late sclerotic ('burned-out') PDB with clinical deterioration but normal bone turnover markers, who experienced significant clinical improvement after treatment with ZOL.

Case description

A Caucasian woman, born in 1923, was diagnosed with symptomatic polyostotic PDB in 1980, (ALP 501, normal range 30–130 IU/L). She initially received courses of calcitonin for 16 years (until 1996) with only partial decreases in bone pain and ALP. Subsequently, when ALP was increased, she had been receiving courses of alendronate (1997 and 2001) and risedronate (2003 and 2005) treatment, which led to transient biochemical and clinical remissions. The last course of risedronate treatment was completed in March 2005. Since then, the patient experienced progressively deteriorating bone and articular pain, rendering her unable to walk without the help of a stick from March 2006. Because of clinical deterioration and the suspicion of malignancy, she was subjected to bone scintigraphy (September 2006), which confirmed polyostotic PDB with enhanced tracer uptake mainly in the skull, pelvis and spine, and diffuse degenerative articular lesions (Figure 1A). Characteristically, plain radiographs were suggestive of late sclerotic PDB (Figure 1B). Given that the low patient's ALP (129 IU/L) was incompatible with clinical deterioration, serum bone-specific alkaline phosphatase (BALP) and C-terminal cross-linking telopeptide of type I collagen (CTX) were measured by established methods, as elsewhere reported [12]; however, they were also within normal range (BALP: 39.4 IU/L, normal range 14–43 IU/L; CTX: 0.66 ng/mL, normal range 0.12–0.75 ng/mL). Serum calcium, phosphate, albumin, parathy-

roid hormone, and kidney and liver function tests were within normal range.

In an attempt to deal with her clinical deterioration, the patient was administered a single 5 mg ZOL infusion (October 2006), after a 10-day administration of calcium and cholecalciferol supplements, as previously reported [9]. She did not experience an acute phase reaction. She reported bone and articular pain improvement, which started ten days after ZOL and sustained for approximately 12 months. Notably, she was able to walk without a stick from November 2006. As it has been elsewhere defined [4, 10], the patient had an acceptable (> 25–30% decrease in ALP) biochemical response to treatment at 6 months, being a 33% decrease in ALP and a 36% decrease in BALP, which lasted for at least 12 months and tended to relapse at 18 months after ZOL (ALP: 86 IU/L at 6 months, 85 IU/L at 12 months, 113 IU/L at 18 months; BALP: 25.2 IU/L, 27.9 IU/L, 44.5 IU/L, respectively). However, serum CTX remained essentially unchanged (0.75 ng/mL, 0.66 ng/mL and 0.63 ng/mL, respectively). The patient deceased from sudden cardiac arrest in September 2008, being 85 years old.

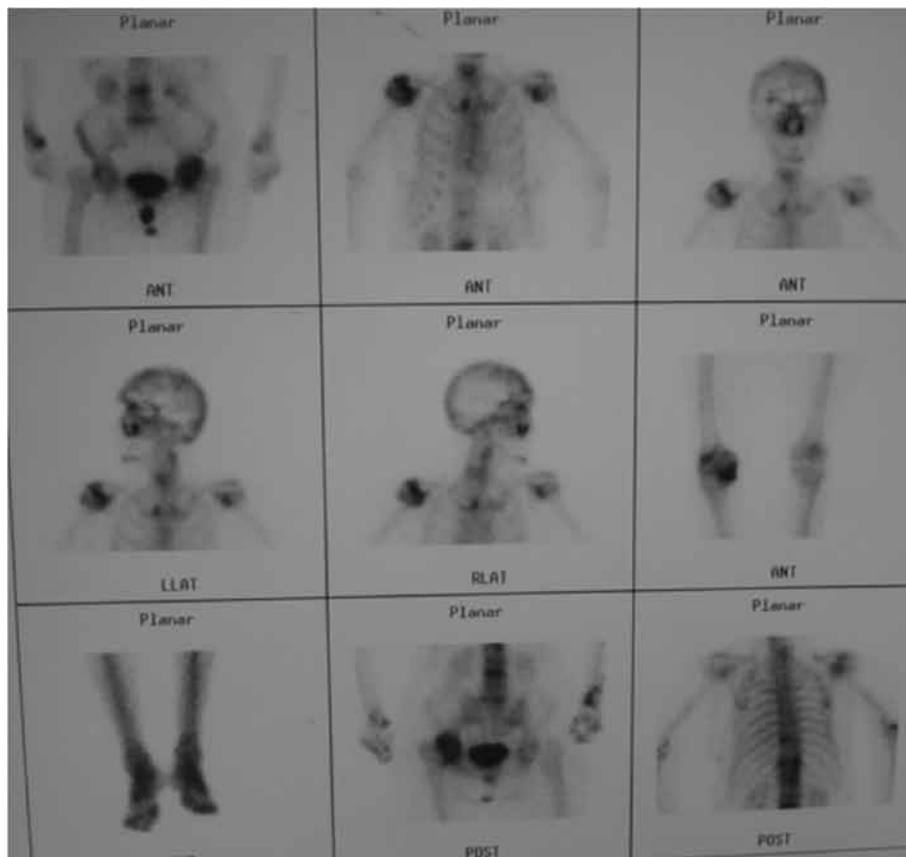
Discussion

A woman with symptomatic, late sclerotic, polyostotic PDB, who experienced significant clinical improvement after treatment with ZOL, despite normal bone turnover markers, is hereby presented.

There are limited similar cases in the literature. Ang et al. described three patients with symptomatic active PDB and normal ALP levels [13]. All three patients had radiographic findings of PDB, increased uptake of radiotracer on bone scintigraphy, but normal ALP; however, they all had elevated levels of urinary markers of bone resorption. The patients were administered pamidronate intravenously (60 mg once weekly for 2–3 consecutive weeks), after which bone pain and scintigraphy were improved, urinary markers of bone resorption were normalised, and ALP was decreased by 19–36% [13], approximately as in our case.

Gkouva et al. described a patient with symptomatic monostotic PDB, but normal ALP and urinary hydroxyproline [14]. She had been treated for osteoporosis with alendronate for the previous four years, which could partly account for normal bone markers. Furthermore, she had repeatedly received anti-inflammatory medication for tibia pain without significant relief. PDB was confirmed by tibia plain radiograph, bone scintigraphy and biopsy of the lesion. She was administered ZOL intravenously (5 mg once), resulting in improvement of bone pain and scintigraphy and a 45% decrease of ALP [14].

A



B

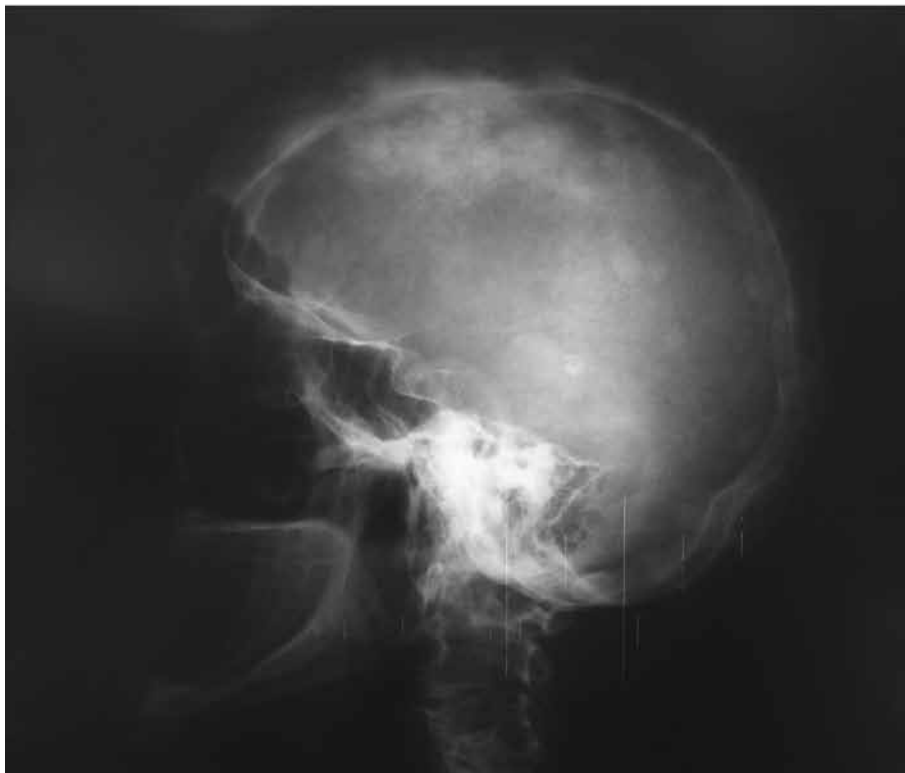

Figure 1A. Bone scintigraphy showing polyostotic Paget's disease of bone with enhanced tracer uptake more prominently on skull, pelvis and spine, and dispersed degenerative articular lesions before zoledronic acid infusion; **B.** Radiograph of the skull showing a 'cotton-wool' appearance indicative of the sclerotic phase of Paget's disease of bone

Rycina 1A. Scyntygrafia kości przed podaniem we wlewie kwasu zoledronowego: cechy polioostotycznej choroby Pageta ze zwiększonym wychwytem znacznika, zwłaszcza w kościach czaszki, miednicy i kręgosłupa, oraz rozsiane degeneracyjne zmiany stawowe; **B.** RTG czaszki: zmiany typu „kłębków waty” sugerujące sklerotyczną fazę choroby kości Pageta

Unlike the Ang et al. cases [13], in our and Gkouva's patients [14], all measured markers were within normal ranges. However, more sensitive bone formation and resorption markers (BALP and CTX) were measured in our case, which, in accordance to ALP, confirmed the disease's biochemical inactivity. Unlike the Gkouva case, our patient had a long-established diagnosis of PDB, which is consistent with her late sclerotic phase of PDB. The decision for treatment was based on clinical and scintigraphic criteria in all the above cases; the subsequent clinical and biochemical improvement supports the necessity of treatment in these patients.

Although ALP is the bone marker of choice for the diagnosis and follow-up of PDB patients [1, 4], BALP is considered to be the most sensitive marker in the evaluation of monostotic disease or in a case of limited bone involvement, as it can be increased in up to 60% of patients with normal ALP [1, 15]. However, even BALP can be normal in very limited bone involvement [11]. ALP and BALP levels result from the increased number of osteoblasts in the pagetic lesions. Their increased levels reflect the rate of bone formation and correlate directly with the extent of skeletal involvement [11]. During the natural course of PDB, ALP activity may increase for many years, reflecting both expansion of disease through affected bones and increased metabolic activity [2]. After reaching its maximal extent and activity, the disease remains more or less stable for many years, with relatively small fluctuations in ALP levels [2].

In accordance with this observation, it seems that even the most sensitive markers, including BALP and CTX, can be within normal ranges when PDB progresses in the 'burned-out' phase, despite clinical deterioration. Furthermore, given the unexpectedly distinct response to ZOL of bone formation compared to bone resorption markers, we speculate that CTX may not be a sensitive marker for osteoclastic activity in cases of 'burned-out' PDB. The acceptable decrease in ALP, whose methods are better standardised than CTX, is directly indicative of a decrease in osteoblastic activity, and indirectly indicative of both a decrease in osteoclastic activity and integrity of the coupling mechanism (between osteoclastic and osteoblastic activity) in our patient. The clinical improvement of our patient could be attributed to this response to treatment, but also to a possible effect of ZOL on cartilage, given that ZOL has been reported to decrease CTX-II, thereby diminishing cartilage collagen degradation [16].

In conclusion, active PDB may be present not only with normal ALP levels, but also with normal BALP and CTX. Clinical deterioration, especially bone pain, should be considered before deciding to treat patients with late sclerotic PDB. Bone scintigraphy may be of importance in these patients, because it depicts increased osteoblastic activity, when bone markers may not. BPs treatment in these patients can lead to clinical improvement.

Conflict of interest

There is no conflict of interest by any author pertinent to this manuscript.

References

1. Polyzos SA, Anastasilakis AD, Terpos E. Paget's disease of bone: emphasis on treatment with zoledronic acid. *Expert Rev Endocrinol Metab* 2009; 4: 424–434.
2. Cundy T, Bolland M. Paget disease of bone. *Trends Endocrinol Metab* 2008; 19: 246–253.
3. Sheane BJ, Delaney H, Doran ME, Cunnane G. A classical presentation of Paget disease of bone. *J Clin Rheumatol* 2008; 14: 373–373.
4. Devogelaer JP, Bergmann P, Body JJ et al. Management of patients with Paget's disease: a consensus document of the Belgian Bone Club. *Osteoporos Int* 2008; 19: 1109–1117.
5. Silverman SL. Paget disease of bone: therapeutic options. *J Clin Rheumatol* 2008; 14: 299–305.
6. Reid IR, Miller P, Lyles K et al. Comparison of a single infusion of zoledronic acid with risedronate for Paget's disease. *N Engl J Med* 2005; 353: 898–908.
7. Hosking D, Lyles K, Brown JP et al. Long-term control of bone turnover in Paget's disease with zoledronic acid and risedronate. *J Bone Miner Res* 2007; 22: 142–148.
8. Merlotti D, Gennari L, Martini G et al. Comparison of Different Intravenous Bisphosphonate Regimens for Paget's Disease of Bone. *J Bone Miner Res* 2007; 22: 1510–1517.
9. Avramidis A, Polyzos SA, Moralidis E et al. Scintigraphic, biochemical, and clinical response to zoledronic acid treatment in patients with Paget's disease of bone. *J Bone Miner Metab* 2008; 26: 635–641.
10. Khan SA, McCloskey EV, Eyres KS et al. Comparison of three intravenous regimens of clodronate in Paget disease of bone. *J Bone Miner Res* 1996; 11: 178–182.
11. Falchetti A, Masi L, Brandi ML. Paget's disease of bone: there's more than the affected skeletal—a clinical review and suggestions for the clinical practice. *Curr Opin Rheumatol* 2010; 22: 410–423.
12. Polyzos SA, Anastasilakis AD, Litsas I et al. Profound hypocalcemia following effective response to zoledronic acid treatment in a patient with juvenile Paget's disease. *J Bone Miner Metab* 2010; 28: 706–712.
13. Ang G, Feiglin D, Moses AM. Symptomatic and scintigraphic improvement after intravenous pamidronate treatment of Paget's disease of bone in patients with normal serum alkaline phosphatase levels. *Endocr Pract* 2003; 9: 280–283.
14. Gkouva L, Andrikoula M, Kontogeorgakos V, Papachristou DJ, Tsatsoulis A. Active Paget's disease of bone with normal biomarkers of bone metabolism: a case report and review of the literature. *Clin Rheumatol* 2011; 30: 139–144.
15. Shankar S, Hosking DJ. Biochemical assessment of Paget's disease of bone. *J Bone Miner Res* 2006; 21 (Suppl 2): 22–27.
16. Garnero P, Christgau S, Delmas PD. The bisphosphonate zoledronate decreases type II collagen breakdown in patients with Paget's disease of bone. *Bone* 2001; 28: 461–464.