



Immunohistochemical detection of follicle stimulating hormone receptor (FSHR) in neuroendocrine tumours

Immunohistochemiczna detekcja receptorów folitropiny (FSHR) w guzach neuroendokrynnych

Marek Pawlikowski¹, Katarzyna Winczyk², Henryk Stępień¹

¹Department of Immunoendocrinology, Chair of Endocrinology, Medical University of Lodz, Poland

²Department of Neuroendocrinology, Chair of Laboratory Medicine, Medical University of Lodz, Poland

Abstract

Introduction: Follicle stimulating hormone receptors (FSHR) are well known to be expressed in gonads and in gonadal tumours. Recently, their incidence has also been revealed in endocrine non-gonadal tumours such as adrenal and pituitary tumours. Moreover, FSHR immunostaining has also been reported in endothelium of intra- and peritumoral blood vessels of a large series of cancers. The present paper reports on the incidence of FSHR in both tumoral cells and some intratumoral blood vessels of neuroendocrine tumours (NETs).

Material and methods: Sixteen NETs samples were taken from 14 patients. The tumour samples were immunostained using the antibody raised against 1-190 amino acid sequence from the human FSH-R and anti-Ki67 antibody.

Results: In all the samples examined, the majority of tumoral cells were immunostained with anti-FSHR antibody. Positive immunostaining concerned also the intratumoral blood vessels endothelia in a half of the examined samples. Immunopositive blood vessels were found more often in tumours with higher Ki-67 index.

Conclusion: FSHR expressed in NETs, if they are functional, may mediate the signals which can enhance further tumour growth. (Endokrynol Pol 2013; 64 (4): 268–271)

Key words: FSH receptors, neuroendocrine tumours, vascular endothelium

Streszczenie

Wstęp: Wiadomo, że ekspresja receptorów folitropiny (FSHR) występuje w gonadach i wywodzących się z gonad nowotworach. Ostatnio wykazano ich obecność także w innych nowotworach endokrynnych, takich jak guzy nadnerczy i gruczolaki przysadki. Ponadto stwierdzono immunopozytywność dla FSHR w śródbłokach około- i wewnątrzguzowych naczyń krwionośnych różnych nowotworów złośliwych. W obecnej pracy wykazano obecność FSHR zarówno w komórkach nowotworowych, jak i niektórych wewnątrz-guzowych naczyniach krwionośnych guzów neuroendokrynnych (NETs).

Materiał i metody: Zbadano 16 wycinków pobranych od 14 pacjentów z NETs. Odczyny immunohistochemiczne wykonano z użyciem przeciwciała skierowanego przeciw fragmentowi 1-190 ludzkiego FSHR oraz przeciwciała dla Ki-67.

Wyniki: Dodatni odczyn z przeciwciałem anti-FSHR stwierdzono w cytoplazmie większości komórek badanych guzów. W połowie badanych NETs odnotowano także immunopozytywność dla FSHR w śródbłokach wewnątrzguzowych naczyń krwionośnych. Dodatni odczyn dla FSHR obserwowano częściej w naczyniach krwionośnych nowotworów z wyższym indeksem Ki-67.

Wnioski: Ektopowe FSHR, jeśli są one aktywne, mogą przekazywać sygnały nasilające dalszy wzrost NETs. (Endokrynol Pol 2013; 64 (4): 268–271)

Słowa kluczowe: receptory FSH, guzy neuroendokrynnie, śródbłonek naczyniowy

Introduction

Follicle stimulating hormone receptors (FSHR) are well known to be expressed in gonads and in gonadal tumours [1]. However, their incidence was also recently revealed in numerous non-gonadal tumours. Radu et al. [2] found the expression of FSHR in endothelia of intra- and peritumoral blood vessels in a large series of non-gonadal cancers (prostate, breast, colon, pancreas, bladder, kidney, lung, liver and stomach). The quoted authors claim that FSHR incidence is specific for tumoral and peritumoral blood vessels since they found them neither in endothelia of

non-tumoral vessels nor in tumoral cells. In our earlier study, we showed that FSHR could be detected immunohistochemically in both endothelia and tumoral cells in non-gonadal endocrine tumours: pituitary adenomas, adrenocortical tumours and pheochromocytomas [3]. Recently the presence of FSHR has been also reported in pancreatic neuroendocrine tumours [4]. Simultaneously, a similar preliminary observation concerning NETs of different origin, was done by us [5].

The present paper reports on the incidence of FSHR in both tumoral cells and some intratumoral blood vessels of neuroendocrine tumours.



Marek Pawlikowski M.D., Ph.D., Department of Immunoendocrinology, Chair of Endocrinology, Medical University of Lodz, Sterlinga St. 3, 91-425 Łódź, Polska, tel. +48 42 664 43 89, e-mail: marek.pawlikowski@umed.lodz.pl

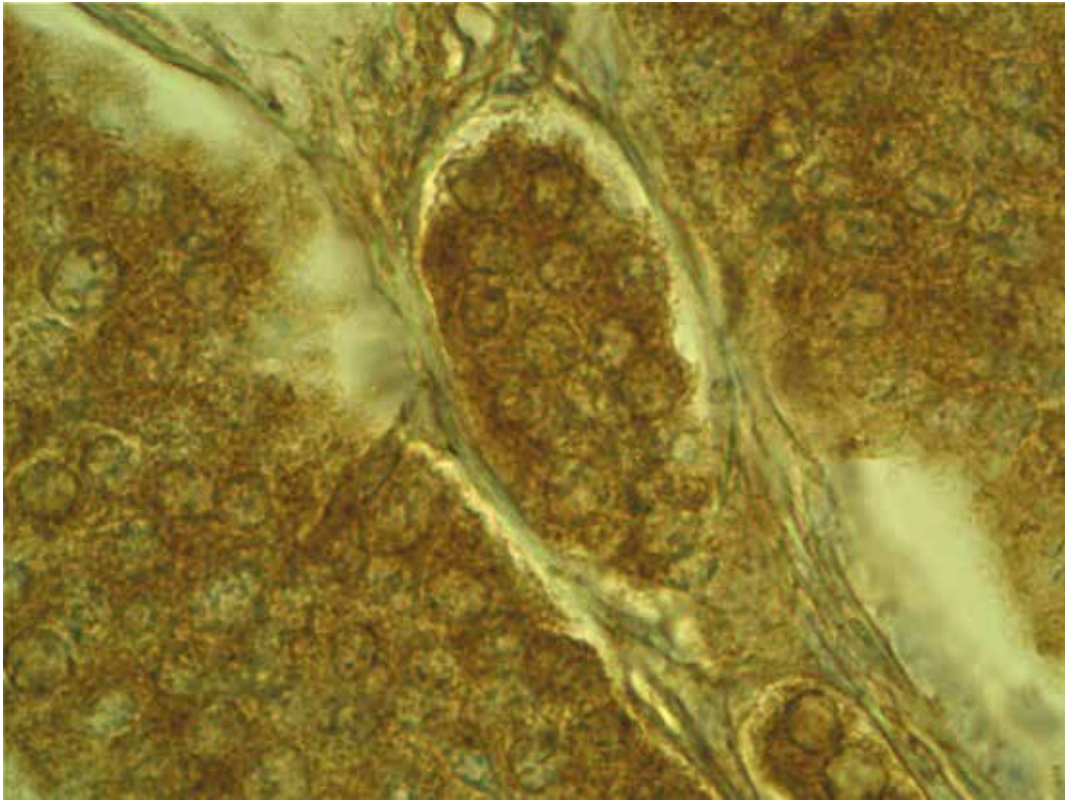


Figure 1. Intestinal 'carcinoid' in 32 year-old woman immunostained with anti-FSHR antibody. Positive immunostaining of tumoral cells can be seen. Original magnification 400 ×

Rycina 1. Jelitowy „carcinoid” u 32-letniej kobiety barwiony z użyciem przeciwciała anty-FSHR. Widoczny pozytywny odczyn w komórkach guza. Powiększenie oryginalne 400 ×

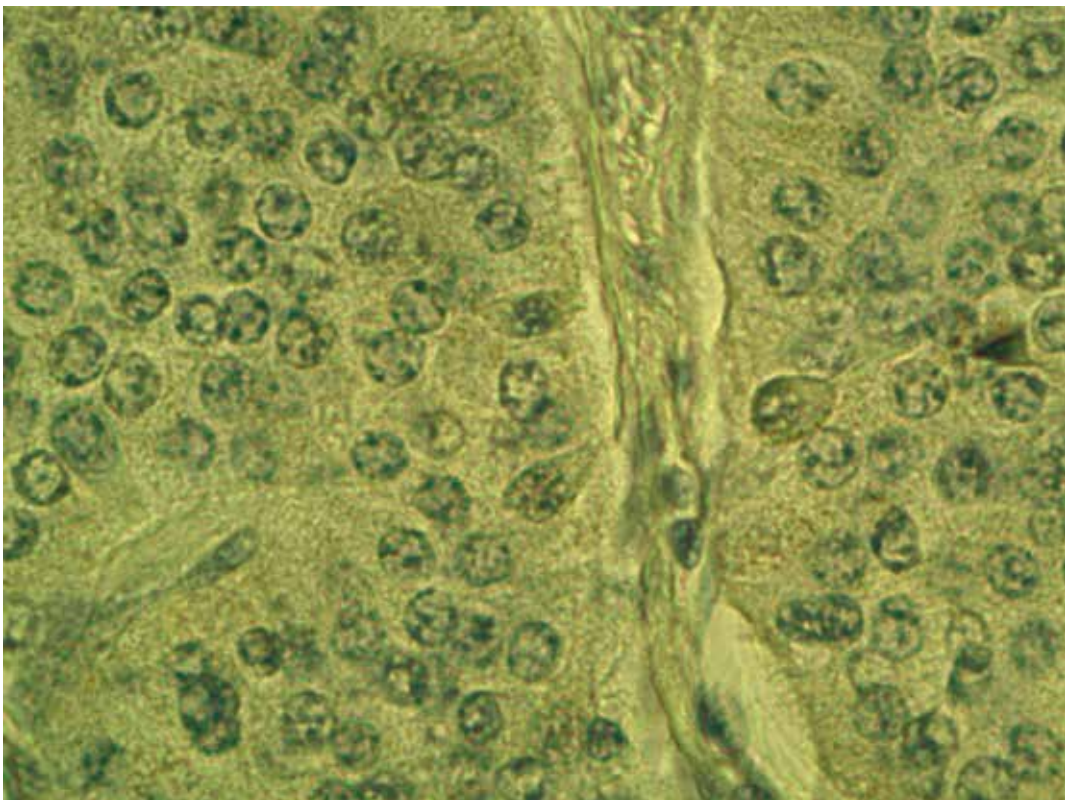


Figure 2. The same tumour as in Figure 1 stained without anti-FSHR antibody. Original magnification 400 ×

Rycina 2. Ten sam guz co na rycinie 1 barwiony z pominięciem przeciwciała anty-FSHR. Powiększenie oryginalne 400 ×

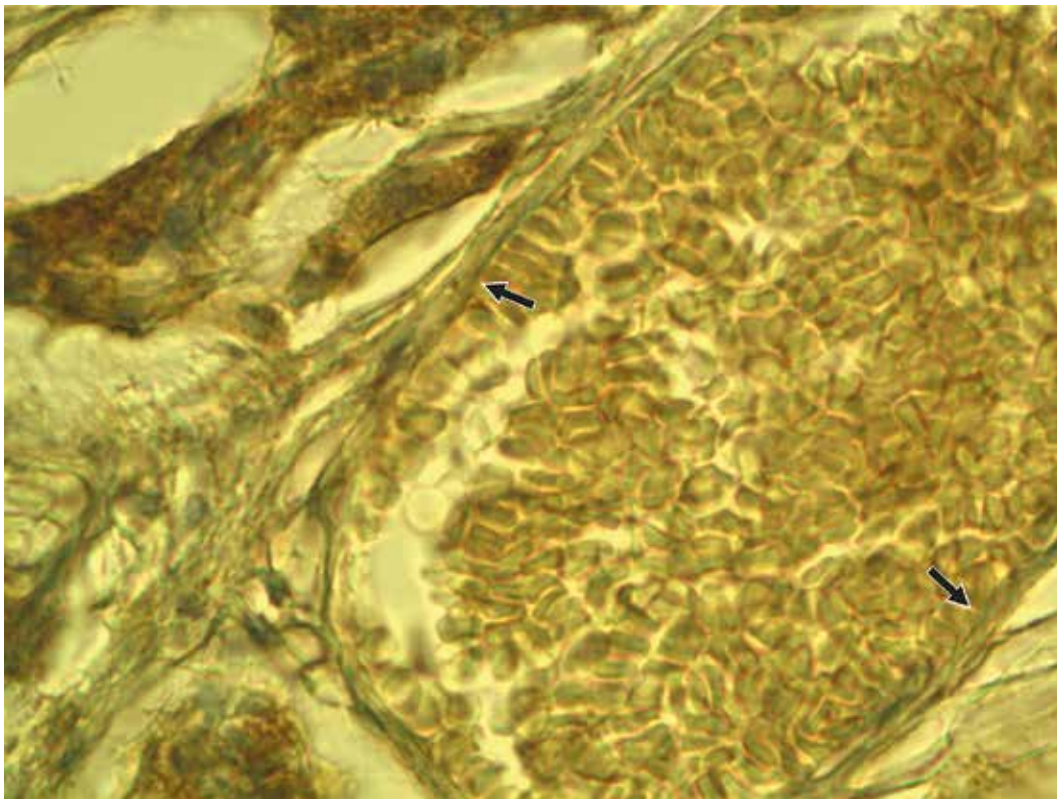


Figure 3. The same tumour as in Figure 1. Negative immunostaining of a blood vessel wall (arrows). Original magnification 400 ×

Rycina 3. Ten sam guz co na rycinie1. Negatywny odczyn w ścianie naczynia krwionośnego (strzałki). Powiększenie oryginalne 400 ×

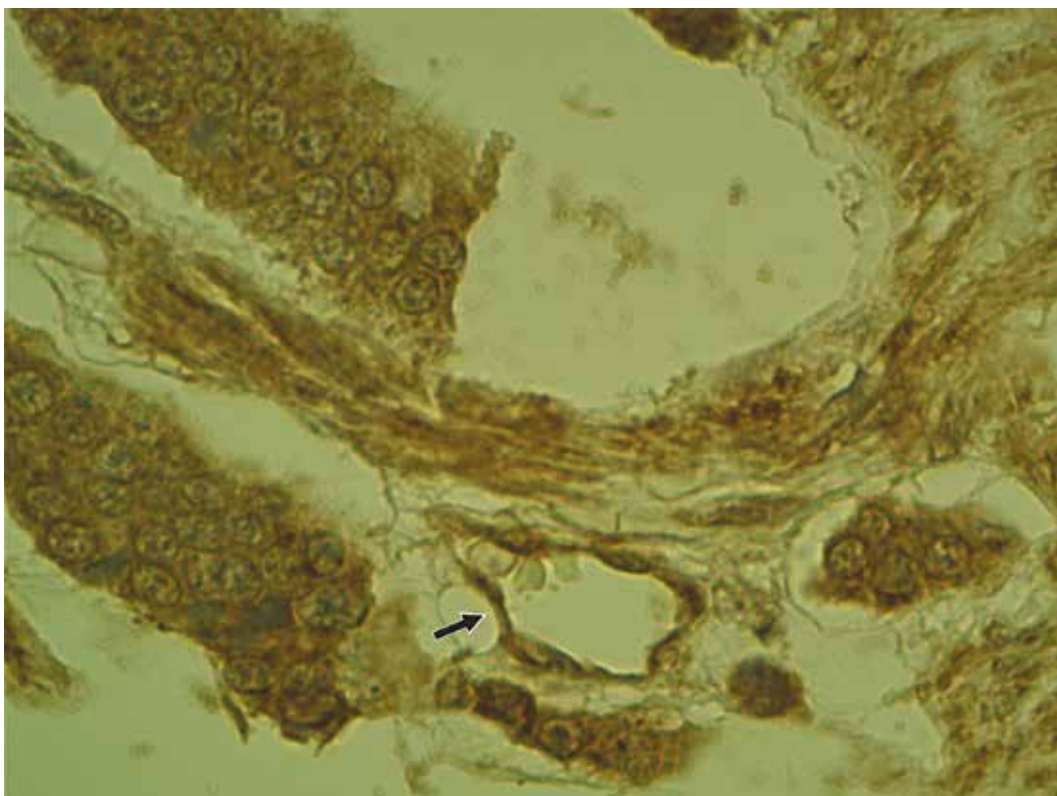


Figure 4. Intestinal 'carcinoid' in 62 year-old man. Positive immunostaining with anti-FSHR antibody in both tumoral cells and blood vessel (arrow) can be seen. Original magnification 400 ×

Rycina 4. Jelitowy „carcinoid” u 62-letniego mężczyzny barwiony z użyciem przeciwciała anty-FSHR. Widoczny pozytywny odczyn zarówno w komórkach guza, jak i w naczyniu krwionośnym (strzałka). Powiększenie oryginalne 400 ×

Material and methods

Sixteen NETs samples were taken from 14 patients. The samples concerned five bronchial 'carcinoids', seven intestinal 'carcinoids', three metastases to the liver and one neuroendocrine pancreatic cancer. Paraffin sections of the tumour samples were immunostained using the rabbit polyclonal antibody raised against 1-190 amino acid sequence from the human FSH-R (sc-13935) purchased from Santa Cruz Biotechnology Inc. (Santa Cruz Biotechnology, CA, USA), applied in a working dilution of 1:100. Additionally, the sections were immunostained with anti-Ki-67 (MIB-1) monoclonal antibody (Dako Cytomation, Glostrup, Denmark). The visualisation of the primary antibodies was done by means either of the REAL EnVision Detection System (FSHR) or the StreptABComplex/HRP Duet (Ki 67), both purchased from Dako Cytomation. The intensity of immunostaining in the tumoral cell cytoplasm was scored semiquantitatively using a descriptive scale: negative staining (score = 0), weak staining (score = 1), moderate staining (score = 2) and strong staining (score = 3). For a negative control, the primary antibody was omitted in the immunostaining procedure. For a positive control, a sample of the human testis was used.

This study was approved by the Local Bioethical Committee, decision number RNN/537/11/KB dated 14 June, 2011.

Results

In all the samples examined, the majority of tumoral cells were immunostained with anti-FSHR antibody (Fig. 1 and 2). Positive immunostaining concerned also the intratumoral blood vessels endothelia in 8/16 examined samples (Fig. 3 and 4). When we compared NETs samples according to Ki-67 values, there was no evident difference in FSHR immunostaining scores in tumoral cells. The mean score calculated in NET samples with Ki-67 index $\geq 2\%$ was 1.8 ± 0.2 (means \pm SEM) and in the samples with Ki-67 $< 2\%$ it was 1.5 ± 0.3 (means \pm SEM). On the other hand, immunopositive blood vessels were found more often in the tumours with higher Ki-67 index (5/6 with Ki-67 $\geq 2\%$ and 2/9 with Ki-67 $< 2\%$).

Discussion

The observations presented above corroborate the data of Sardella et al. [4] showing that FSHR are expressed in tumoral cells of NETs. The quoted authors showed that FSHR co-localise with chromogranin A, a marker of tumoral cells, but not with von Willebrand's factor, which is a marker of vascular endothelia. However,

in contrast to the cited data, our finding shows that FSHR were localised not only in the tumoral cells, but in some cases in blood vessels as well. This observation, in turn, is in agreement with the earlier data of Radu et al. [2] who demonstrated the FSHR immunopositivity of vascular endothelia in the intra- and peritumoral blood vessels of different cancers. However, it must be underlined that the endothelial immunostaining in NETs in our study occurred only in a half of the samples examined by us, and is rather rare in tumours with lower grade of differentiation. We did not observe the differences depending on the origin of NETs, however, our material was too small to allow a definitive conclusion.

The question arises whether the ectopic expression of FSHR in NETs have any consequences for the clinical outcome of the tumour. The functionality of these receptors remains unknown and needs further study. It is known that the ovary stimulation of FSHR by FSH leads to the enhanced proliferation of granulosa cells, increased secretion of vascular endothelial growth factor (VEGF), and increased angiogenesis [6]. A similar observation was made with ovarian cancer cells SK-OV-3 [6]. FSH also inhibits ovarian cancer cell apoptosis by up-regulating survivin and downregulating programmed cell death gene 6 (PDCD6) and death receptor 5 (DR5) [7, 8].

Summing up, FSHR, if they are functional, may mediate the signals which can enhance further tumour growth.

Acknowledgements

This paper was supported financially by the Medical University of Łódź. The skilful technical assistance of Mrs Maria Jaranowska and Mrs Anna Oplątowska is greatly appreciated.

References

- Huhtaniemi I. Are gonadotropins tumorigenic — a critical review of clinical and experimental data. *Mol Cell Endocrinol* 2010; 329: 56–61.
- Radu A, Pichon C, Camparo P et al. Expression of follicle stimulating hormone receptor in tumor blood vessels. *New England J Med.* 2010; 363: 1621–1630.
- Pawlikowski M, Pisarek H, Kubiak R et al. Immunohistochemical detection of FSH receptors in pituitary adenomas and adrenal tumors. *Folia Histochem Cytobiol* 2012; 50: 325–330.
- Sardella C, Russo D, Raggi F et al. Ectopic expression of FSH receptor isoforms in neoplastic but not in endothelial cells from pancreatic neuroendocrine tumours. *J Endocrinol Invest* 2013; 36: 174–179.
- Pawlikowski M, Pisarek H, Kubiak R et al. Immunohistochemical detection of FSH receptors in endocrine tumors 15th International & 14th European Congress of Endocrinology, 5–9 May 2012, Florence, Italy. *Endocrine Abstracts* 2012, 29, P842.
- Kuo SW, Ke FC, Chang GD et al. Potential role of follicle stimulating hormone (FSH) and transforming growth factor (TGF β) in the regulation of ovarian angiogenesis. *J Cell Physiol* 2011; 226: 1608–1619.
- Park YH, Kim SJ, Jeong BH et al. Follicular stimulating hormone enhances Notch1 expression in SK-OV-3 ovarian cancer cells. *J Gynecol Oncol* 2010; 21: 119–124.
- Huang Y, Jin H, Liou I et al. FSH inhibits ovarian cancer cell apoptosis by up-regulating survivin and down regulating PDCD6 and DR5. *Endocr Relat Cancer* 2010; 18: 13–26.