



Adrenal gland injury secondary to blunt traumatic mechanisms: a marker of overall injury severity

Uszkodzenie nadnerczy w następstwie tępych urazów:
wskaźnik ciężkości doznanych obrażeń

S. Peter Stawicki^{1, 2, 3}, Mark J. Seamon^{3, 4}, Carla M. Carvalho⁴, Nilesh Bhoot^{3, 5}, Rohit Sharma^{3, 6},
Sherwin P. Schrag^{3, 7}, Steven M. Steinberg^{2, 3}

¹Department of Surgery, St Luke's Hospital and Health Network, Bethlehem, PA

²Department of Surgery, Division of Critical Care, Trauma, and Burn, the Ohio State University Medical Center, Columbus, OH

³OPUS 12 Foundation, Columbus, OH

⁴Department of Surgery, Section of Trauma/Critical Care, Temple University School of Medicine, Philadelphia, PA

⁵Department of Surgery, Bronx-Lebanon Hospital Center, Bronx, NY

⁶Roswell Park Cancer Institute, University of Buffalo (SUNY), Buffalo, NY

⁷Department of Surgery, Jersey City Medical Center, Jersey City, NJ

Abstract

Introduction: Adrenal gland injuries (AGI) are seen increasingly frequently owing to advances in modern imaging techniques. This study describes a series of patients with blunt AGI, with the emphasis on AGI as a marker of injury severity, CT-radiographic classification of AGI and associated injury patterns.

Material and methods: A retrospective review of blunt trauma patients with AGI was performed. Variables examined included demographics, mechanism of injury, length of hospital and ICU stay, clinical status on admission, AGI characteristics, associated injuries, complications, procedures, mortality and discharge disposition.

Results: There were 29 AGI patients with a mean injury severity score of 25. The most common injury mechanisms were motor-vehicular collisions (15/29) and falls (5/29). Right-sided AGI (16/29) outnumbered left-sided (12/29) injuries. The most common CT-radiographic types of AGI were adrenal gland contusions and lacerations with limited "blush". While patterns of injuries differed between right and left-sided AGI, the mean number of injuries did not. The most common associated injuries included extremity (21/29), rib (20/29) and spinal fractures (18/29). Common procedures included orthopaedic fixation (10/29), vena cava filter (8/29) and tracheostomy (5/29). A median of two complications per patient was reported, including adrenal insufficiency in two patients. Mortality was 17%. The median hospital and ICU length of stay were 15 and 12 days, respectively.

Conclusions: Adrenal gland injury is associated with significant morbidity and mortality. With modern imaging modalities capable of reliably detecting adrenal injury, the presence of AGI should be considered a marker of overall injury severity. The authors provide a CT-radiographic classification of adrenal injuries. (*Pol J Endocrinol* 2009; 60 (1): 2-8)

Key words: adrenal gland injury, computed tomographic radiographic classification, injury severity and mortality, injury patterns, associated injuries, trauma

Streszczenie

Wstęp: W związku z postępowaniem w zakresie nowoczesnych metod obrazowania coraz częściej stwierdza się uszkodzenia nadnerczy (AGI, adrenal gland injuries). W tym badaniu opisano grupę chorych, którzy doznali uszkodzenia nadnerczy w wyniku tępego urazu. Zwrócono szczególną uwagę na AGI jako wskaźnik ciężkości odniesionych obrażeń, klasyfikację AGI na podstawie tomografii komputerowej i charakter współistniejących obrażeń.

Materiał i metody: Przeprowadzono retrospektywną analizę danych pacjentów, którzy doznali AGI w wyniku tępego urazu. W badaniu uwzględniono dane demograficzne, mechanizm powstania urazu, czas hospitalizacji oraz pobytu na oddziale intensywnej opieki medycznej, stan kliniczny w chwili przyjęcia do szpitala, cechy AGI, doznane obrażenia, powikłania, zastosowane procedury medyczne, odsetek zgonów i dalsze postępowanie.

Wyniki: Do badania włączono 29 osób z AGI, u których średnia ocena ciężkości obrażeń wynosiła 25. Najczęstszymi przyczynami urazu były wypadki motocyklowe (15/29) i upadki (5/29). Liczba prawostronnych AGI (16/29) była wyższa niż liczba uszkodzeń lewostronnych (12/29). Najczęściej stwierdzanym rodzajem uszkodzeń AGI w badaniu tomograficznym było stłuczenie i rozdarcie narządu z niewielkim krwawieniem. Chociaż charakter uszkodzeń różnił się w zależności od prawo- lub lewostronnej lokalizacji AGI, średnia liczba uszkodzeń była taka sama. Najczęstszymi współwystępującymi obrażeniami były złamania kończyn (21/29), żeber (20/29) i kręgow (18/29). Do najczęściej wykonywanych procedur należały: unieruchomienie ortopedyczne (10/29), wszczepienie filtra do żyły głównej (8/29) i tracheostomia (5/29). Mediana liczby powikłań u poszczególnych chorych wynosiła 2 (włączając niewydolność nadnerczy u 2 osób). Odsetek zgonów wynosił 17%. Mediana okresu hospitalizacji i pobytu na oddziale intensywnej opieki medycznej wynosiła odpowiednio 15 i 12 dni.



Wnioski: Uszkodzenie nadnerczy wiąże się ze znaczną chorobowością i śmiertelnością. Dostępne obecnie nowoczesne metody obrazowania umożliwiają wykrycie uszkodzeń nadnerczy. Należałoby rozważyć przyjęcie obecności AGI jako markera ciężkości doznanych obrażeń. Autorzy przedstawili klasyfikację uszkodzeń nadnerczy na podstawie badań tomograficznych.

(*Endokrynol Pol* 2009; 60 (1): 2–8)

Słowa kluczowe: uszkodzenie nadnerczy, klasyfikacja tomograficzna, ciężkość obrażeń i śmiertelność, rodzaje obrażeń, współistniejące obrażenia, uraz

Introduction

Advances in modern diagnostic imaging have contributed to the increased frequency of adrenal gland injury (AGI) diagnosis. The protected anatomical position of the adrenals implies that significant amounts of energy are required to cause AGI. This type of injury was previously found to be associated with significant injury severity and mortality, but not sufficiently so to be considered a marker of overall injury severity [1–3].

Despite previous reports on various aspects of AGI, detailed knowledge of the mechanisms and injury patterns associated with AGI is still poor. Existing studies are limited either by small sample size, inadequate “resolution” of database-derived information or lack of specific details regarding AGI and AGI-associated findings [2–7]. The primary goal of this study was to present a detailed description of radiographic types of AGI and injury patterns associated with blunt traumatic adrenal injuries, focusing on practical clinical aspects and highlighting AGI as a marker of overall injury severity in the era of advanced diagnostic imaging methods.

Material and methods

A retrospective audit of blunt trauma patients who had sustained adrenal gland injury at two Level I trauma centres was performed for the period between 1st January 1998 and 30th December 2006. Inclusion criteria included a trauma diagnosis (ICD9 codes 800.00–950.00) with additional definitive radiographic/clinical record confirmation of AGI and a patient age greater than 18 years. Patients < 18 years of age, pregnant patients and prison inmates were excluded.

Variables examined included the following: (a) patient demographics; (b) mechanism of injury; (c) injury severity score (ISS); (d) patient clinical status on presentation — vital signs, intubation status, and Glasgow Coma Score (GCS); (e) AGI related characteristics — laterality and lesion type as determined by computed tomographic (CT) radiographic appearance; (f) details of associated injury characteristics and patterns; (g) complications; (h) invasive procedures performed; (i) discharge disposition; (j) length of hospital stay; (k) length of stay in intensive care unit (ICU); (l) mortality. Adrenal insufficiency was defined as a low random serum cortisol level (< 15 micrograms/dL).

The following radiographic CT-based classification of adrenal gland trauma was utilized by the authors: (a) least severe — localized haematoma and/or adrenal gland contusion; (b) moderately severe — presence of active adrenal gland haemorrhage (*i.e.* “blush” indicative of intravenous contrast extravasation) or gland laceration; (c) high severity — presence of a large associated retroperitoneal peri-adrenal haematoma and evidence of active bleeding (*i.e.* radiographic “blush”) from the adrenal gland. See Figure 1 for a detailed description of the above classification.

Descriptive statistics represented in tabular and graphical form were used to portray the basic study findings. Fisher’s exact test was used to analyze categorical data, and Student’s t-test was used to analyze continuous variables. Statistical significance was set at alpha = 0.05 (two-tailed). Study data were analyzed using the SPSS statistical software package (SPSS, Inc., Chicago, IL). Institutional approval was obtained prior to the conduct of this study.

Results

A group of 29 patients with AGI treated during the study period were identified from institutional trauma registries, radiographic records, and medical record review (approximate incidence of AGI = 0.30%). There were significantly more men (23) than women (6) in the study group ($p < 0.028$) and mean patient age was 38.8 ± 16.9 years. Demographic details of the study sample are listed in Table I.

From the trauma mechanism point of view, most patients had been involved in motor vehicular collisions (MVC, 15/29) and falls (5/29). The mean ISS was 25.2, with a median ISS of 24.5 (in a range from 9 to 50). Details of patient injury characteristics can be seen in Table I.

A significant proportion of patients in this study presented to the trauma resuscitation area with hypotension (14/29, or 48%). Ten patients (34%) either arrived at the hospital intubated or required intubation within one hour of arrival. In addition, the mean GCS for the study sample was 9, with 5 patients (17%) presenting with a GCS of 3 or 3T. Details regarding patient presentation are shown in Tables I and II.

In terms of laterality, there was a predominance of right-sided AGI, with 16/29 (55%) of adrenal injuries being right-sided, 12/29 (41%) being left-sided and only one being bilateral (Table III). With regard to the classi-

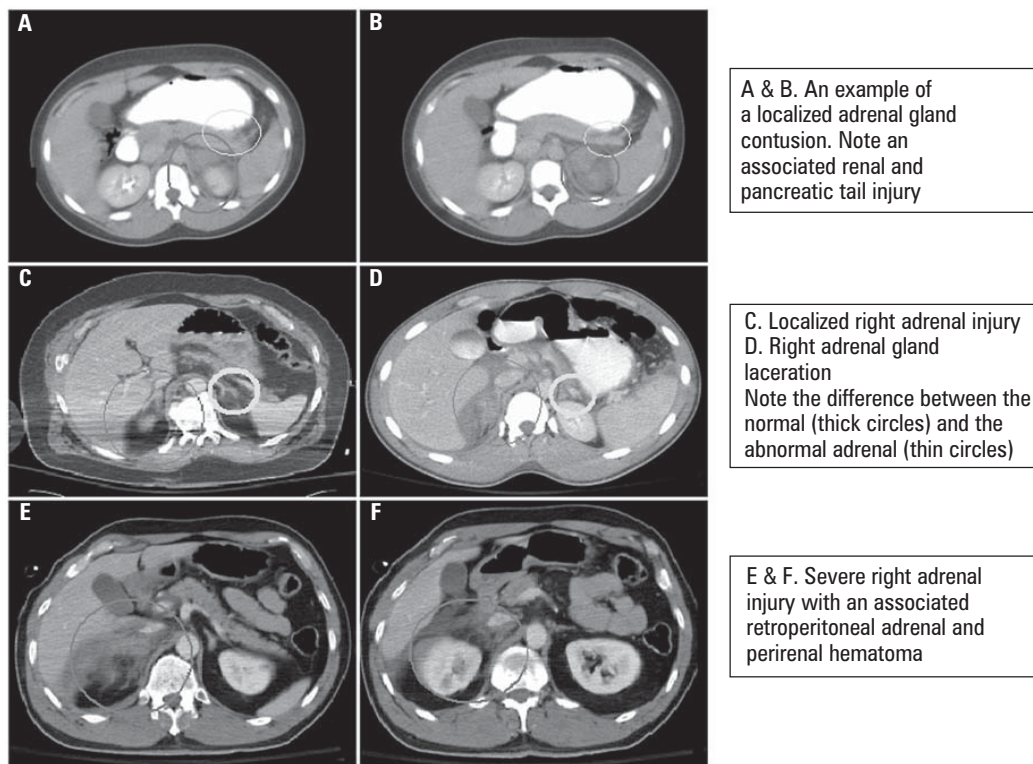


Figure 1. Examples of three different types of adrenal gland injuries (AGI) classified by computed tomographic (CT) appearance: (A–C) Adrenal gland contusion; (D) Adrenal gland laceration; and (E–F) Adrenal gland injury associated with large retroperitoneal hematoma

Rycina 1. Trzy rodzaje uszkodzeń nadnerczy sklasyfikowane na podstawie obrazu uzyskanego w badaniu metodą tomografii komputerowej: (A–C) stłuczenie nadnercza; (D) rozerwanie nadnercza; (E–F) uszkodzenie nadnercza z dużym krwiakiem zaotrzewnowym

Table I. Patient and injury characteristics in the study group

Tabela I. Charakterystyka osób objętych badaniem i doznanych przez nie urazów

Age	Mean 38.8 ± 16.9	Median 42 years
Gender	Male 23	Female 6 (p < 0.028)*
Mechanism		
MVC related		15
Fall from height		5
Motorcycle related		3
Sports injuries		3
Pedestrian struck		2
Bicycle related		1
ISS^a	Mean 25.2 ± 8.73	Median 24.5 (9–50)
GCS^b	Median GCS score	9
Associated injuries	Mean 5.72 ± 3.35	Median 5 (1–16)
LOS^c	Mean 16.1 ± 26.3	Median 15 (2–142)
ICU^d Patient Characteristics	Mean ICU LOS 14.3 ± 35.9	Median ICU LOS 12 (0–142)
	Mean vent days 12.8	Median vent days 5 (0–142)

*Denotes statistically significant difference; ^aGCS — Glasgow Coma Score; ^bISS — injury severity score; ^cLOS — length of stay; ^dICU — intensive care unit

Table II. Details of patient presentation

Tabela II. Stan kliniczny pacjentów w momencie przyjęcia do szpitala

Characteristics at presentation	
Hypotension	14 (48%)
Intubated before or upon arrival	10 (34%)
Number of patients with GCS 3T	5 (17%)
Recorded symptoms/clinical complaints	
Abdominal/flank pain	13 (45%)
Back pain	6 (21%)
Symptoms/complaints not available or not attributable to AGI	10 (34%)

*Denotes statistically significant difference; ^aGCS — Glasgow Coma Score; ^bAGI — adrenal gland injury

fication of adrenal lesions on the basis of radiographic appearance (Fig. 1), the most common types for both left- and right-sided lesions were localized adrenal contusion/haematoma (56% on right; 50% on left) followed by adrenal laceration/haemorrhagic “blush” (38% on right; 33% on left). Details of specific lesion types grouped by injury laterality can be found in Table III.

Patients with AGI had a mean of 5.7 associated injuries (a median of 5 injuries). The most common associa-

Table III. Adrenal gland injury: Types by injury laterality

Tabela III. Uszkodzenie nadnerczy: rodzaj uszkodzenia w zależności od lokalizacji prawo-, lewo- lub obustronnej

Right	16
Localized haematoma/contusion	9
Haemorrhage/laceration	6
Large retroperitoneal haematoma	1
Left	12
Localized haematoma/contusion	6
Haemorrhage/laceration	4
Large retroperitoneal haematoma	2
Bilateral	1
Haemorrhage/laceration	1
Presence of tumour/mass	2
AGI following motor vehicular crash	1 ^a
Delayed adrenal bleed after minor fall (day 12)	1

^aAGI — adrenal gland injury

ted injuries were rib fractures (20/29), spinal fractures (18/29) extremity fractures (21) (Table IV). Patterns of injuries, although not differing statistically between right- and left-sided injuries, tended to vary in distribution according to the laterality of the AGI. Right-sided injuries tended to be associated with severe head injuries, spinal fractures, and liver injuries (Fig. 2). With left-sided AGI, proportionately more pancreatic and splenic injuries were seen (Fig. 2).

After the study group had been examined for the presence of pre-traumatic adrenal gland lesions, two patients with pre-existing adrenal masses were identified. In the setting of such lesions, one patient experienced a large retroperitoneal haematoma following a motor vehicular crash and another patient experienced delayed haemorrhage 12 days after a relatively minor traumatic fall with impact ipsilateral to the lesion (Table III).

Patients in the study group underwent a mean of two operative procedures (Table V and Fig. 3) and had over 1.5 complications (a median of two complications) per patient (Table V and Fig. 4). The most common complications included respiratory failure/pneumonia, deep venous thrombosis (DVT)/pulmonary embolism, ileus and pancreatitis. The presence of adrenal insufficiency was identified in two (6.9%) patients, neither of whom had bilateral lesions or a pre-existing history of corticosteroid use. The most commonly performed types of surgical procedure included extremity fixation/washout, placement of inferior vena cava filter and tracheostomy placement (Fig. 3).

Patients with documented AGI demonstrated a significant need for healthcare resources, with a mean hospital stay of 16 days, a median ICU stay of 12 days and a median of 5 days on mechanical ventilation (Table I). Mortality was 5/29 patients (17.2%). Of the surviving 24 patients, 13 patients were discharged home and 11 to

Table IV. Types of associated injuries by anatomical region and frequency

Tabela IV. Rodzaje obrażeń doznanych przez chorych z wyszczególnieniem rejonu anatomicznego i częstości występowania w badanej grupie

Injury	Total# Injuries
Head & Neck	19
Facial fractures	7
Severe traumatic brain injury	6
Concussion	3
Blunt carotid/vertebral injury	2
Orbital fracture	1
Chest	45
Rib fractures	20
Pulmonary contusion	9
Pneumothorax	6
Haemothorax	4
Blunt cardiac injury	2
Sternal fracture	2
Diaphragm injury	1
Mediastinal haematoma	1
Abdomen, Pelvis & Retroperitoneum	34
Spleen injury	11
Hepatic injury	7
Haemoperitoneum	4
Renal injury	4
Retroperitoneal haematoma	4
Pancreatic injury	2
Mesenteric arterial/venous injury	1
Pneumoperitoneum	1
Spine-related	21
Cervical spine	3
Thoracic spine	7
Lumbar spine	7
Sacral spine	1
Spinal cord injury	2
Cervical spine ligamentous injury	1
Long bone fractures	21
Femur fracture	7
Tibia/fibula fracture	6
Clavicle fracture	5
Radius/ulna fracture	2
Humerus fracture	1
Other Extremity Orthopaedic & Vascular	18
Pelvic fracture	6
Calcaneus fracture	3
Scapula fracture	3
Peripheral vascular injury	2
Foot fracture	1
Hip dislocation	1
Ligamentous injury of the knee	1
Patella fracture	1
Skin & Soft tissue	8
Severe skin/soft tissue injury	8

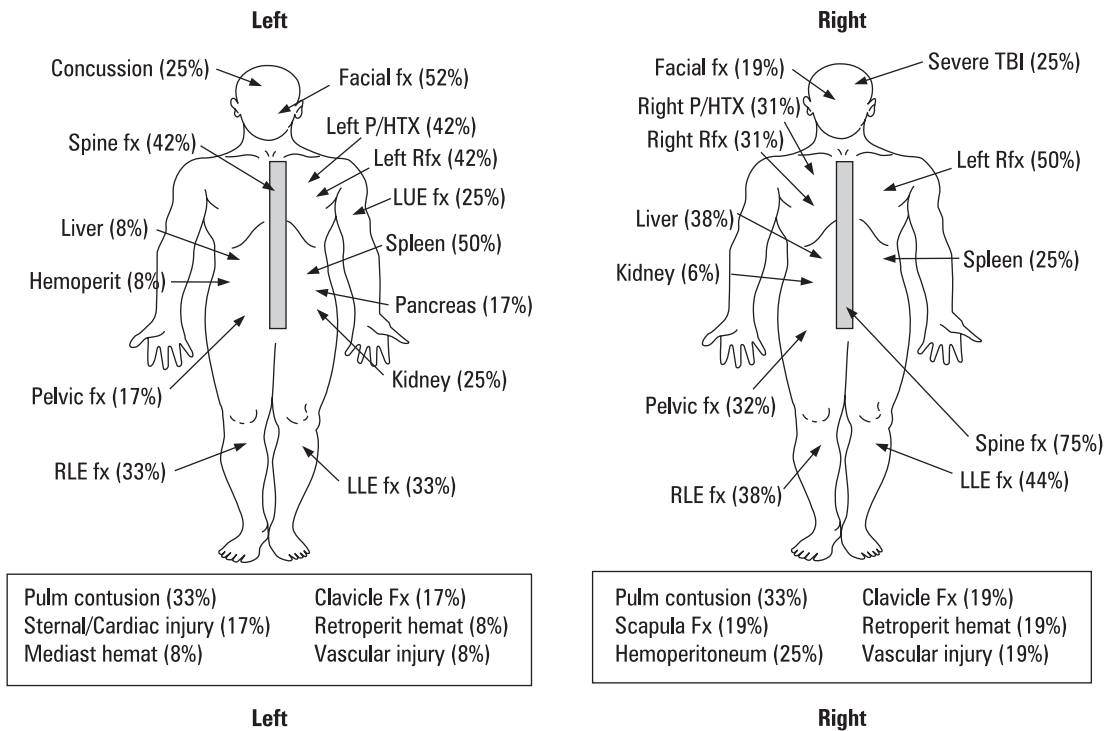


Figure 2. Associated injury patterns based on adrenal gland injury laterality

Rycina 2. Współistnienie obrażeń innych narządów i uszkodzenia prawego lub lewego nadnercza

Table V. Adrenal gland injury: Complications, procedures, disposition, and mortality

Table V. Uszkodzenia nadnerczy: powikłania, procedury medyczne, miejsce dalszego leczenia, odsetek zgonów

Complications	
Mean	1.55 ± 1.59
Median	2 (range, 0–5)
Procedures	
Mean	2.03 ± 2.23
Median	2 (range, 0–9)
Disposition	
Home	13
Rehabilitation/skilled nursing/long-term acute care	11
Mortality	
	5 of 29 (17.2%)

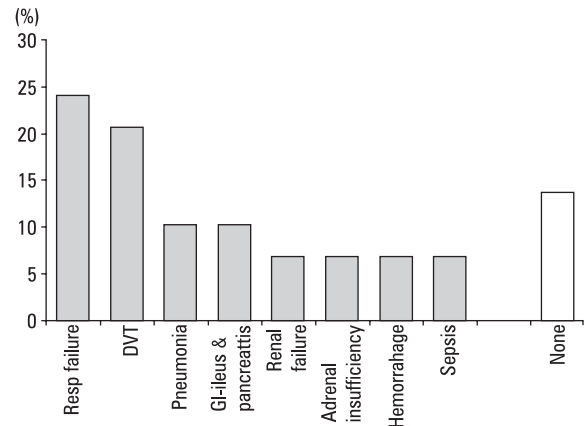


Figure 3. Complications associated with adrenal gland injuries in this study

Rycina 3. Powikłania związane z uszkodzeniem nadnerczy zaobserwowane podczas badania

a rehabilitation facility, skilled nursing facility or long-term acute care hospital (Table V).

Discussion

Adrenal gland injuries (AGI) are diagnosed with increasing frequency, mostly owing to continued advances in diagnostic imaging over the last two decades [3, 7]. Although the number of reports and series describing AGI has increased over the years, the amount of new infor-

mation about AGI has not expanded substantially [3–6]. This is partly because many of the large studies describing AGI are based on administrative databases as a source of clinical information, thus producing clinical data of limited ‘resolution’ [2–3, 5]. Other studies are characterized by small sample sizes and limited clinical applicability [1, 4, 7]. The goal of the current study is to provide a detailed audit of AGI-associated injuries and radiographic characteristics of AGI, stressing the significance of adrenal trauma as a marker of overall injury

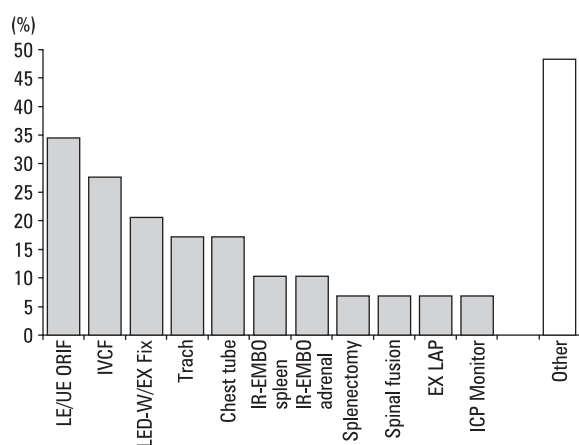


Figure 4. Procedure utilization in the current study. Legend: LE — lower extremity; UE — upper extremity; ORIF — open reduction and internal fixation; IVCF — inferior vena cava filter; D-W — debridement and washout; EX FIX — external fixation; IR — interventional radiology; EX LAP — exploratory laparotomy; ICP — intracranial pressure; EMBO — embolization

Rycina 4. Procedury medyczne wykonane u osób objętych badaniem. Legenda: LE — kończyna dolna; UE — kończyna górna; ORIF — otarte nastawienie złamania z wewnętrzną stabilizacją; IVCF — wszczepienie filtra do żyły głównej dolnej; D-W — oczyszczenie i wypłukanie; EX FIX — zewnętrzna stabilizacja; IR — radiologia interwencyjna; EX LAP — laparotomia zwiadowcza; ICP — ciśnienie wewnątrzczaszkowe; EMBO — emboliza

severity in the age of continuously evolving imaging modalities and improved adrenal injury detection.

Demographic and general injury-related data in this study confirm observations from other studies [2–3, 5]. Specifically, the study group was characterized by a significant predominance of male patients (79%), an observation consistent with previously published large AGI studies (63% to 76%) [2–3]. The mean patient age of 39 years is also similar to that reported in other studies [2, 5]. In terms of the mechanism of injury, motor vehicular accidents and falls were the most commonly reported mechanisms of blunt injury in this and other studies [2–3, 7].

The significant injury severity associated with AGI is well exemplified by the high mean injury severity score of 25.2 in this study, a figure in good agreement with previously published data [2, 5]. Nearly half of all patients in this study were hypotensive upon arrival in the trauma bay, and over one third of patients were either intubated or required intubation shortly upon arrival in the trauma resuscitation area. In addition, the observation of median GCS of 9 in this study, as well as the fact that 17% of patients had GCS of 3 on initial presentation, further corroborates the significant injury severity associated with AGI.

Significantly more right-sided adrenal traumatic lesions were seen in this study than left-sided lesions. This

distribution is in general agreement with other studies of AGI [2–3, 7]. The current study provides a wealth of information regarding non-AGI injuries associated with adrenal gland trauma. Details of associated injury patterns grouped by AGI laterality can be seen in Figure 2. The average patient in this series had 5 associated injuries, the most common anatomical injury sites being the chest, the abdomen-pelvis-retroperitoneum, the spine and the extremities (Table IV). Injury patterns differed between the left- and right-sided AGI groups. Severe traumatic brain injuries, rib fractures, spinal fractures, hepatic injuries, and extremity fractures were more commonly associated with right-sided AGI. Facial fractures and splenic, renal and pancreatic injuries were more commonly associated with left-sided AGI. Although general patterns of associated injuries are consistent with previous reports, no studies to date discuss these patterns in the amount of detail provided in this study (Table IV) or with the focus on AGI laterality (Fig. 2) [2, 3].

The authors categorized traumatic adrenal gland injuries according to the CT-radiographic appearance of these lesions. Not unexpectedly, the most common type of AGI was localized haematoma/contusion, followed by adrenal haemorrhage/laceration, and by large retroperitoneal haematoma (Table III and Fig. 1). It has been suggested that AGI can result from two basic pathological mechanisms that are not mutually exclusive [3]. The first proposed mechanism occurs in adrenal contusions and involves the build-up of intra-glandular pressure with subsequent ischaemic necrosis [8]. The second proposed mechanism involves direct disruption of the adrenal gland, (i.e. laceration or fragmentation) with subsequent haemorrhagic sequelae [4]. The authors believe that the classification of AGI types presented in Figure 1 reflects the frequent simultaneous presence of both of these mechanisms of injury.

The authors were especially interested in determining whether the presence of a pre-existing adrenal mass (i.e. adenoma) can predispose to post-traumatic adrenal gland sequelae. Two patients with pre-existing adrenal lesions were identified in this series. In one case delayed bleeding occurred within a pre-existing pheochromocytoma, resulting in a large retroperitoneal haematoma that required angiographic embolization. The tumour was surgically removed several months later. In another case, an adrenal adenoma was associated with a self-limited ipsilateral adrenal contusion/haemorrhage. In this case no specific intervention was required. According to Burks et al. the possibility of post-traumatic haemorrhage into a pre-existing adrenal lesion should always be considered in the appropriate clinical context [9].

In this study the presence of AGI was associated with a significant number of operative procedures. The most

common types of procedures included orthopaedic fixations and washouts, vena cava filter placement and tracheostomy creation (Fig. 4). Overall, patients in this series underwent a mean of two operative procedures. This figure is much higher than previously published data on procedure utilization in the setting of AGI, including the 86% operative rate reported by Gomez et al. [4] and the 21% rate previously reported by Stawicki et al. [3].

Patients with adrenal gland injuries in this study had a median of two complications per patient. The most common complications included respiratory failure/pneumonia, deep venous thrombosis/pulmonary embolism and gastrointestinal complications (ileus and pancreatitis) (Fig. 3). Although previous studies report on complications associated with AGI, they lack the detail provided in the current series [3]. This study confirms the dominant presence of pulmonary complications (respiratory failure and pneumonia) following AGI, likely a reflection of the high frequency of associated thoracic injuries [2, 3]. The incidence of deep venous thrombosis (over 20%), gastrointestinal complications (over 10%) and renal failure (over 5%) is much higher than previously reported [3]. The surprisingly high frequency of deep venous thrombosis in this study is consistent with published data showing that the incidence of deep venous thrombosis and overall injury severity tend to increase in parallel [10].

Adrenal insufficiency was noted in two (6.9%) patients in this study, both diagnosed on the basis of low random serum cortisol levels (< 15 micrograms/dL). Neither of these patients had bilateral AGI or a pre-existing history of adrenal insufficiency or corticosteroid use. Several cases of endocrinopathies associated with AGI have previously been described [3, 11–13]. Adrenal insufficiency following bilateral adrenal haemorrhage was reported by Baccot et al. and Udobi et al. [13, 14]. A recent study by Castaldo et al. demonstrated increasing injury severity and age, but not AGI, to be independent predictors of adrenal insufficiency following blunt traumatic adrenal injury [5]. At the other end of the spectrum, an association between a post-traumatic adrenal mass/haematoma and a clinical syndrome of severe hypertension and increased urine normetaneprine levels has also been described [12]. Surgical drainage of the adrenal haematoma resulted in complete resolution of this post-traumatic pheochromocytoma-like clinical state [12]. A similar post-AGI hypertensive syndrome was also reported by Brueckner et al. [11].

Patients in this series required utilization of significant healthcare resources during their post-injury acute care phase. The prolonged hospital and ICU lengths of stay, as well as the 5-day median requirement for ventilatory support, all corroborate previously published clinical data [3]. The overall mortality in this study

was 17.2%, which is similar to the 17.7% mortality figure reported by Castaldo et al. [5] and is an intermediate figure between the 5.4% and 23% AGI-associated mortality rates previously reported by other investigators [2, 3]. Of the surviving patients, over 45% required discharge to a rehabilitation facility, skilled nursing facility or long-term acute care hospital.

The limitations of this study include its retrospective nature, the relatively small sample size, the lack of a comparison group and the inability to demonstrate cause-and-effect relationships between clinical variables. The strengths of this study include the detailed survey of associated injury patterns and the meticulous information regarding operative procedures and complications. An additional strength of this study is the categorization of adrenal lesions by their computed tomographic appearance and laterality.

Conclusions

This study demonstrated an association between the presence of AGI and significant morbidity and mortality. The authors presented a CT-based radiographic classification of AGI types as well as a detailed audit of injury patterns associated with AGI, including injury pattern variations based on the laterality of adrenal gland injury. With modern imaging modalities able to detect adrenal gland injuries reliably, the presence of AGI should be considered a marker of overall injury severity.

References

- Igwilo OC, Sulkowski RJ, Shah MR et al. Embolization of traumatic adrenal hemorrhage. *J Trauma* 1999; 47: 1153–1155.
- Mehrazin R, Derweesh IH, Kincade MC et al. Adrenal trauma: Elvis Presley Memorial Trauma Center experience. *Urology* 2007; 70: 851–855.
- Stawicki SP, Hoey BA, Grossman MD et al. Adrenal gland trauma is associated with high injury severity and mortality. *Curr Surg* 2003; 60: 431–436.
- Gómez RG, McAninch JW, Carroll PR. Adrenal gland trauma: diagnosis and management. *J Trauma* 1993; 35: 870–874.
- Castaldo ET, Guillaumondegui OD, Greco JA 3rd et al. Are adrenal injuries predictive of adrenal insufficiency in patients sustaining blunt trauma? *Am Surg* 2008; 74: 262–266.
- Chen KT, Lin TY, Foo NP et al. Traumatic adrenal haematoma: A condition rarely recognised in the emergency department. *Injury* 2007; 38: 584–587.
- Rana AI, Kenney PJ, Lockhart ME et al. Adrenal gland hematomas in trauma patients. *Radiology* 2004; 230: 669–675.
- Siu SC, Kitzman DW, Sheedy PF et al. Adrenal insufficiency from bilateral adrenal hemorrhage. *Mayo Clin Proc* 1990; 65: 664–670.
- Burks DW, Mirvis SE, Shanmuganathan K. Acute adrenal injury after blunt abdominal trauma: CT findings. *AJR Am J Roentgenol* 1992; 158: 503–507.
- Stawicki SP, Grossman MD, Cipolla J et al. Deep venous thrombosis and pulmonary embolism in trauma patients: an overstatement of the problem? *Am Surg* 2005; 71: 387–391.
- Brueckner M, Durig M. Traumatic hematoma of adrenal gland simulating pheochromocytoma. A case report. *Unfallchirurgie* 1992; 18: 311–314.
- Schmidt J, Mohr VD, Metzger P et al. Posttraumatic hypertension secondary to adrenal hemorrhage mimicking pheochromocytoma: case report. *J Trauma* 1999; 46: 973–975.
- Udobi KF, Childs EW. Adrenal crisis after traumatic bilateral adrenal hemorrhage. *J Trauma* 2001; 51: 597–600.
- Baccot S, Tiffet O, Bonnot P et al. Bilateral posttraumatic adrenal hemorrhage: case report of a patient with acute adrenal insufficiency. *Ann Chir* 2000; 125: 273–275.