



Real-time ultrasound elastography — a new tool for diagnosing thyroid nodules

Ultrasonograficzna elastografia czasu rzeczywistego — nowe narzędzie w diagnostyce zmian ogniskowych tarczycy

Małgorzata Gietka-Czernel¹, Magdalena Kochman¹, Karolina Bujalska¹,
Elżbieta Stachlewska-Nasfeter², Wojciech Zgliczyński¹

¹Department of Endocrinology, The Medical Centre of Postgraduate Education, Warsaw, Poland

²Head and Neck Cancer Department, Maria Skłodowska-Curie Memorial Cancer Centre and Institute of Oncology, Warsaw, Poland

Abstract

Introduction: Real-time elastography (RTE) is a non-invasive ultrasound method of estimation of tissue stiffness by measuring the degree of local tissue displacements after a small compression. Recent data has shown its ability to differentiate benign from malignant tumours. The aim of this study was to evaluate the accuracy of RTE in the diagnosis of malignant and benign thyroid nodules.

Material and methods: 71 thyroid nodules in 52 patients: 42 females and 10 males aged 28–77 were examined using conventional ultrasonography (US), fine-flow CD imaging and RTE. All nodules previously underwent fine-needle aspiration biopsy (FNAB), and patients with malignant and suspicious cytological results were referred for surgery. The final diagnosis was based on FNAB results in patients with benign cytology and on the histopathology reading in those who underwent surgery. An elasticity score (ES) from 1 to 5 was determined for each nodule according to the Ueno classification.

Results: An elasticity score (ES) of 4 or 5 was found in 19 out of 22 (86.5%) thyroid cancers and in only 1 out of 31 (3%) benign nodules. This was strongly indicative for malignancy ($p < 0.0001$) with sensitivity 86%, specificity 97%, positive predictive value (PPV) 95% and negative predictive value (NPV) 91%.

Conclusions: RTE is a highly sensitive and specific method of diagnosing thyroid nodules. This technique can be employed in selecting thyroid nodules for fine-needle aspiration biopsy. (*Pol J Endocrinol* 2010; 61 (6): 652–657)

Key words: thyroid nodule, elastography, ultrasonography

Streszczenie

Wstęp: Elastografia czasu rzeczywistego (RTE, *real-time elastography*) jest nieinwazyjną metodą oceny twardości tkanki poprzez pomiar stopnia lokalnych przemieszczeń tkankowych pod wpływem słabego ucisku. Ostatnie dane wskazują na jej zdolność do różnicowania guzów łagodnych i złośliwych. Celem pracy była ocena dokładności diagnostycznej RTE w rozpoznawaniu złośliwych i łagodnych guzów tarczycy.

Materiał i metody: Siedemdziesiąt jeden zmian ogniskowych tarczycy u 52 pacjentów: 42 kobiet i 10 mężczyzn w wieku 28–77 lat poddano badaniu ultrasonograficznemu w skali szarości, ocenie przepływów metodą *fine-flow* CD i RTE. Wszystkie zmiany były uprzednio poddane biopsji aspiracyjnej cienkoigłowej (BAC), a pacjenci z cytologicznym rozpoznaniem zmiany złośliwej lub podejrzananej byli kierowani do leczenia operacyjnego. Rozpoznanie ostateczne u pacjentów z cytologicznie stwierdzoną zmianą łagodną ustalono na podstawie wyniku BACC, zaś u poddanych operacji na podstawie wyniku badania histopatologicznego. Dla każdej zmiany oceniano wskaźnik elastyczności (ES) w skali od 1 do 5 zgodnie z klasyfikacją Ueno.

Wyniki: Wskaźnik elastyczności 4 lub 5 stwierdzono w 19/22 (86,5%) raków tarczycy i tylko w 1/31 (3%) łagodnej zmianie ogniskowej. Wskazywał on silnie na złośliwość zmiany ($p < 0,0001$) z czułością 86%, swoistością 97%, dodatnią wartością predykcyjną 95% i ujemną wartością predykcyjną 91%.

Wnioski: Elastografia czasu rzeczywistego jest wysoce czułą i swoistą metodą w diagnostyce zmian ogniskowych tarczycy. Technika ta może być stosowana do typowania zmian ogniskowych tarczycy wymagających biopsji aspiracyjnej cienkoigłowej.

(*Endokrynol Pol* 2010; 61 (6): 652–657)

Słowa kluczowe: guz tarczycy, elastografia, ultrasonografia



Magdalena Kochman MD, PhD, Department of Endocrinology, The Medical Centre of Postgraduate Education, 01-809 Warszawa, Ceglowska St. 80, tel.: +48 22 569 01 05, fax: +48 22 834 31 31, e-mail: mkochman@cmkp.edu.pl

Introduction

One of the key features of thyroid cancer evaluated at palpation is stiffness [1]. However, this clinical parameter is subjective and depends on the experience of the examiner, the nodule size and the location within the thyroid gland [2].

Elastography, sometimes called 'electronic palpation', is a non-invasive US technique, introduced in 1990, that estimates tissue stiffness by measuring the degree of local tissue displacement after a small compression [3]. It has been shown to be useful in diagnosing breast and prostate cancer, and in determining the area of liver fibrosis in chronic viral hepatitis and post infarct myocardial fibrosis [4–7]. Previously published data has also proved its potential in the assessment of thyroid nodules. To evaluate the stiffness of thyroid nodules, external compression using a freehand technique, as well as internal compression employing carotid artery pulsation, have been used [8–12]. According to this data, ES predicts thyroid gland malignancy with 82–97% sensitivity and 96–100% specificity.

The aim of the present study was to evaluate the diagnostic accuracy of RTE in differentiating between malignant and benign thyroid nodules.

Material and methods

Seventy one thyroid nodules in 52 patients (42 females, 10 males aged 45 ± 15.6 yrs, mean \pm SD, range 28–77) were examined by grey-scale US, fine-flow CD imaging and RTE. All nodules had previously undergone FNAB and had been diagnosed as follows: benign $n = 31$ (44%), malignant $n = 25$ (35%) and suspicious $n = 15$ (21%). All patients with malignant and suspicious cytological results were referred to the surgery unit and the final diagnosis was based on the histopathology reading. In patients with benign cytological results, the final diagnosis was based on the clinical course of the disease, US and RTE results and the cytological reading. None of them needed surgery as none was thyrotoxic, nor had compressive symptoms.

Thyroid US and RTE were performed by three examiners using a real-time Hitachi Hivision Preirus machine with linear transducer of 5–12 MHz.

The following parameters of the nodule were assessed by conventional US and fine-flow CD:

- echogenicity: hyperechoic, isoechoic, hypoechoic;
- margins: hypoechoic halo, regular margins, irregular margins, infiltrative growth;
- microcalcifications: presence or absence of hyperechoic spots of 2–3 mm without acoustic shadow.

- fine flow CD: I type — absent blood flow, II type — peripheral blood flow, IIIa — central blood flow, IIIb — central and peripheral blood flow [13].

Real-time elastography measurements were performed after US and fine-flow CD examination using the same probe. Patients were lying in the same position as for conventional US. A light external compression with the US probe was applied to the anterior neck above the nodule to fix its position and to avoid lateral movement. The 5-grade scale of the strength of pressure was displayed in real time on the screen (Fig. 1) and a pressure between grades 2 and 4 was maintained. Then compression was released and applied again in the pulsative manner (compression-relaxation). The ROI was set to include the evaluated nodule and the surrounding thyroid and subcutaneous tissue, as this technique of elastography measures relative stiffness. US elastogram was superimposed over the B-mode image and the stiffness of the tissue was colour-coded from red to blue: red was assigned to the softest tissue, blue to the hardest elements, and green expressed an intermediate degree of stiffness.

The ES images were classified according to the Ueno & Ito [14] elasticity score which was also used by Rago et al. [11]:

- ES 1 — elasticity in the whole nodule. The nodule is light green with small amounts of red;
 - ES 2 — elasticity in the majority of the nodule. The nodule is green with small amounts of red and blue;
 - ES 3 — elasticity in the minor part of nodule. The nodule is predominantly blue with small amounts of red and green;
 - ES 4 — no elasticity in the nodule. The whole nodule is blue;
 - ES 5 — no elasticity in the nodule nor in its surrounding. The whole nodule and its circumference are blue.
- Examples of ES 1–5 are shown in Figure 1.

Statistical analysis

The χ^2 test was used to compare distribution of non-parametric values and the Wald-Wolfowitz test was used to compare distribution of non-parametric values between small groups. $P < 0.05$ was considered significant.

Results

Of the 40 patients referred to the surgical unit, 27 had surgery: 19 with FNAB results of malignancy and eight with FNAB results of suspicious nodules. In 22 patients, histopathological confirmation of malignancy was obtained: in all 19 of the patients with FNAB positive results and in three patients with FNAB suspicious results.

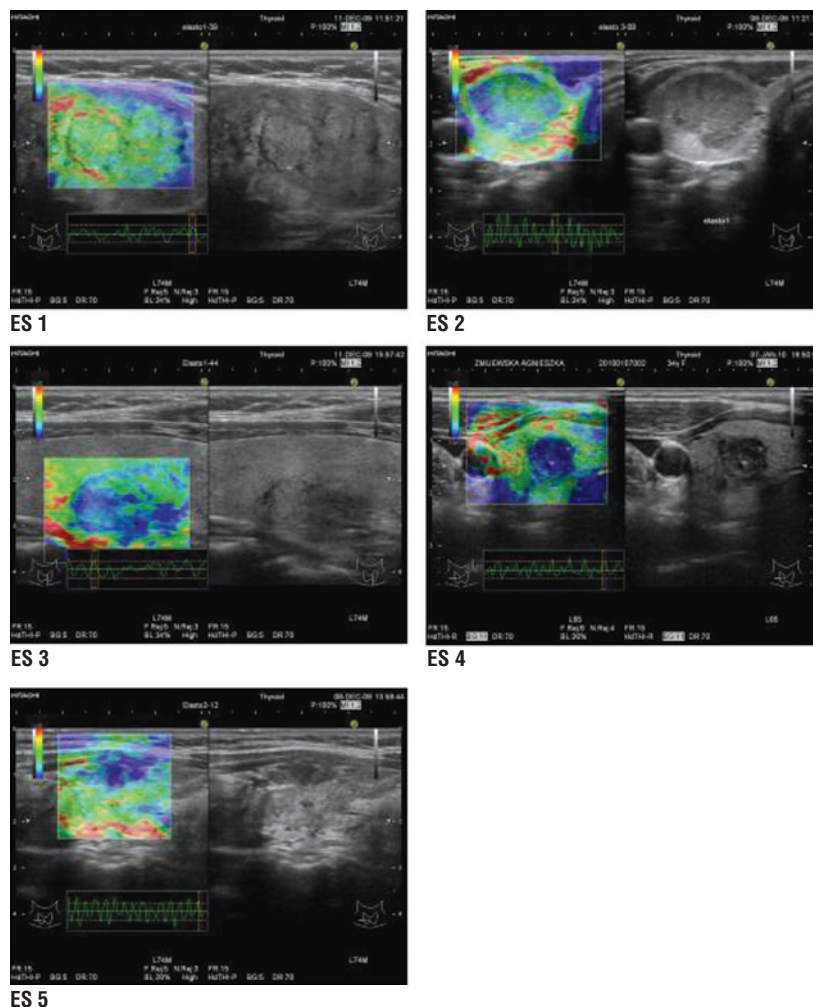


Figure 1. Examples of 1 to 5 elasticity scores (ES)

Rycina 1. Przykłady wskaźników elastyczności (ES) od 1 do 5

There were 18 cases of papillary carcinoma, one case of oxyphilic carcinoma and three cases of medullary carcinoma.

Clinical and US characteristics of histopathologically confirmed malignant nodules are presented in Table I.

The value of a single feature and the value of the combination of two features indicative of malignancy in conventional US and fine-flow CD are presented in Tables II and III.

RTE results for malignant and benign nodules are demonstrated in Table IV and Figure 2.

ES 4 and 5 were strongly indicative for malignant nodules ($p < 0.0001$) with sensitivity 86%, specificity 97%, PPV 95% and NPV 91%. Preliminary data from the group with cytologically suspicious results is presented in Table V.

Discussion

The prevalence of palpable thyroid nodules is reported to be 5.3–6.4% in females and 0.8–1.5% in males [15, 16].

US has greatly improved the sensitivity of detection of thyroid nodules, which can be found in 72% of women and 41% of men [17]. The vast majority of these represent benign hyperplastic nodules or adenomas and only approximately 5–15% of nodules are malignant [18]. The number of thyroid nodules increases in iodine-deficient areas and after irradiation.

According to recent guidelines, US is the first-choice imaging method and ultrasound-guided FNAB remains a mainstay in the differential diagnosis of thyroid nodules [18–21].

There are several US features associated with malignancy, such as microcalcifications, hypoechogenicity, irregular margins or absent 'halo' sign, solid composition, intranodular vascularisation and height greater than width at the transverse imaging. Unfortunately, their usefulness in differentiating between benign and malignant thyroid lesions is unsatisfactory: sensitivity 17–87% and specificity 40–95% [22–24]. Thus, more reliable criteria for determining nodules which require FNAB are needed.

Table I. Clinical and US characteristics of malignant nodules

Tabela I. Kliniczne i ultrasonograficzne cechy guzków złośliwych

Clinical characteristics		
Thyroid carcinoma as a single nodule	7/22	32%
Thyroid carcinoma as an element of multinodular goiter	15/22	68%
Coexistence of Hashimoto disease	12/22	55%
Conventional US and fine-flow CD pattern		
Hypoechoogenicity	21/22	95%
Irregular margins/infiltrative growth	14/22	64%
Microcalcifications	13/22	59%
Central and peripheral/central flow	12/22	44%

Table II. Diagnostic value of a single pattern in US B-mode and fine-flow CD mode for thyroid cancer. PPV — positive predictive value; NPV — negative predictive value

Tabela II. Wartość diagnostyczna pojedynczej cechy ultrasonograficznej w prezentacji B i fine-flow CD dla raka tarczycy. PPV — dodatnia wartość predykcijna, NPV — ujemna wartość predykcijna.

US pattern	Benign (n=31)	Cancer (n=22)	p	Sensitivity (%)	Specificity (%)	PPV (%)	NPV (%)
Hypoechoogenicity							
Yes	15	21	<0.001	95	52	58	94
No	16	1					
Microcalcifications							
Yes	7	13	<0.02	59	77	65	73
No	24	9					
Irregular margins							
Yes	6	14	<0.003	64	81	70	76
No	25	8					
Intranodular vascularization							
Yes	11	12	NS	55	65	52	67
No	20	10					

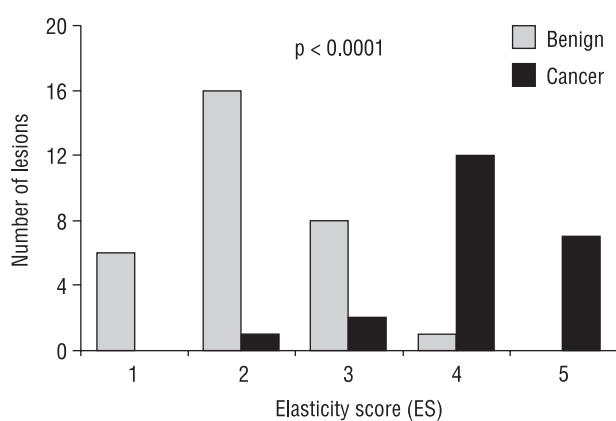
Table III. Diagnostic value of different combinations of two patterns in US B-mode and fine-flow CD mode for thyroid cancer. PPV — positive predictive value; NPV — negative predictive value

Tabela III. Wartość diagnostyczna kombinacji dwóch cech ultrasonograficznych w prezentacji B i fine-flow CD dla raka tarczycy. PPV — dodatnia wartość predykcijna, NPV — ujemna wartość predykcijna

US pattern	Benign (n=31)	Cancer (n=22)	p	Sensitivity (%)	Specificity (%)	PPV (%)	NPV (%)
Hypoechoogenicity + irregular margins							
Yes	5	6	NS	55	84	27	62
No	26	16					
Hypoechoogenicity + microcalcifications							
Yes	5	4	NS	44	84	18	59
No	26	18					
Hypoechoogenicity + intranodular vascularization							
Yes	4	9	<0.05	69	87	41	67
No	27	13					

Table IV. Elasticity score (ES) in benign lesions and thyroid cancers**Tabela IV.** Wskaźnik elastyczności (ES) w zmianach łagodnych i rakach tarczycy

ES	Benign		Cancer	
	n = 31	%	n = 22	%
1	6	19	0	0
2	16	52	1	4.5
3	8	26	2	9
4	1	3	12	54.5
5	0	0	7	32

**Figure 2.** Elasticity score (ES) distribution in benign lesions and thyroid cancers**Rycina 2.** Rozkład wskaźnika elastyczności (ES) w zmianach łagodnych i rakach tarczycy

In our material, 95% of thyroid cancers were hypoechoic, 64% had irregular margins or infiltrative growth and 59% had microcalcifications; only these features significantly differentiated malignant and benign nod-

ules with PPV value 52–70% and NPV 67–94%. Among the combination of two features in conventional US, only hypoechogenicity and type III vascularisation were significant for malignancy, with PPV and NPV of 69% and 67%, respectively. Our results confirm previous observations [24] which show that the predictive value of conventional US increases at the expense of its sensitivity.

ES 4 and 5 were found in 19 out of 22 (86.5%) thyroid cancers and in only 1 out of 31 (3%) benign nodules. ES 4 and 5 were highly predictive for malignancy ($p < 0.0001$) with PPV and NPV of 95% and 91%, respectively. These results stress the value of RTE over conventional US. However, one must be aware that RTE, although very promising, has some limitations. This method may give false results in very large nodules, and in nodules which are predominantly cystic and contain large calcifications. In the case of very large nodules which fill the whole lobe, there is no surrounding thyroid tissue to compare the stiffness. In the liquid compartments, elastograms always have the same pattern: the blue band at the top, the green in the middle and the red one at the bottom. The presence of coarse calcifications makes the nodule very hard and its elasticity score is always high [12]. RTE based on tissue compression may underestimate the ES of nodules localised over a stiff base, for example in the thyroid isthmus [12]. A particular problem concerns follicular carcinoma; according to the observations of Fukunari et al. [25] in more than 70% of cases, the elastogram shows a green colour in the centre of the nodule and blue at its periphery. There were no cases of follicular carcinoma in our material; such a nodule could be misinterpreted and classified as having ES 3. In the majority of publications, only single thyroid nodules were examined; in our observation 68% of cancers occurred in multinodular goiter. Our experience demonstrates that RTE is likewise highly valuable for investigating the nodules within multinodular goitre. Our results showed that coexistence

Table V. Results of histopathological examination and elasticity score (ES) in patients with suspicious cytology ($n = 8$)**Tabela V.** Wyniki badania histopatologicznego i oceny wskaźnika elastyczności (ES) u pacjentów z guzami cytologicznie podejrzanymi ($n = 8$)

Benign (n = 5)			Cancer (n = 3)		
No	Histopathology	ES	No	Histopathology	ES
1.	Follicular adenoma	2	1.	Oxyphilic cell type carcinoma	4
2.	Hyperplastic nodule	2	2.	Papillary carcinoma (classic type)	4
3.	Hyperplastic nodule	3	3.	Papillary carcinoma (follicular type)	4
4.	Hyperplastic nodule	3			
5.	Hyperplastic nodule	3			

of the thyroid nodule and Hashimoto's thyroiditis (HT) does not erroneously influence ES. However, one case of thyroid cancer classified falsely negative as having ES 2 was accompanied by HT. To our surprise, 55% of cases of thyroid carcinoma were accompanied by HT; the patients were hypothyroid and seropositive for anti-peroxidase and/or anti-thyroglobulin antibodies.

The frequent coexistence of these two entities is well known [26] and the historical interpretation is that HT through lymphocytic infiltration inhibits the growth of malignant tissue and protects against metastases. Recent observations about the frequent prevalence of RET/PTC rearrangements in HT and papillary carcinoma suggest the possible common molecular basis of these two entities [27–29].

Perhaps the most intriguing question concerning RTE is whether it can deliver any advance in diagnosing cytologically suspicious nodules. Our study cannot answer this question, because only eight of the 15 cytologically suspicious lesions gained histopathological results, and there was not a single case of follicular carcinoma. According to Rago et al. [11] RTE has great potential in diagnosing cytologically indeterminate results. But the experience of Fukunari et al. [25] shows that one must retain a degree of scepticism about this. Anyway, RTE is a rapidly developing method and perhaps more research will soon be done in this field.

The limitations of our study are: non-random selection of the group, the lack of interobserver agreement analysis and the lack of histopathological diagnosis of benign nodules.

To the best of our knowledge, this is the first study in Polish medical literature concerning the use of RTE in evaluating thyroid nodules. Our data is preliminary and confirms the substantial value of RTE in diagnosing thyroid nodules.

Conclusions

1. Real-time ultrasound elastography is a highly sensitive and specific method for diagnosing thyroid nodules.
2. This method can be employed in selecting thyroid incidentalomas and thyroid nodules in multinodular goitres for fine-needle aspiration biopsy.

References

1. Gietka-Czernel M. Wole guzowate obojętne. *Medycyna po Dyplomie 2008; Zeszyt edukacyjny 2008; 7: 25–28.*
2. Tan GH, Gharib H, Reading CC. Solitary thyroid nodule: comparison between palpation and ultrasonography. *Arch Intern Med 1995; 155: 2418–2423.*

3. Lerner RM, Huang SR, Parker KJ. „Sonoelasticity” images derived from ultrasound signals in mechanically vibrated tissues. *Ultrasound Med Biol 1990; 16: 231–239.*
4. Wojcinski S, Farrok A, Weber S et al. Multicenter study of ultrasound real-time tissue elastography in 779 cases for the assessment of breast lesions: improved diagnostic performance by combining the BI-RADS(R)-US classification system with sonoelastography. *Ultraschall Med 2010; 20 [Epub ahead of print].*
5. Aigner F, Mitterberger M, Rehder P et al. Status of transrectal ultrasound imaging of the prostate. *J Endourol 2010; 24: 685–691.*
6. Friedrich-Rust M, Ong M, Herman E et al. Real-time elastography for non-invasive assessment of liver fibrosis in chronic viral hepatitis. *Am J Roentgenol 2007; 188: 758–764.*
7. Levine AR. Elastografia tarczycy. In: Baskin HJ, Duick DS, Levine R (eds.). *Badanie ultrasonograficzne oraz biopsja aspiracyjna cienkoigłowa tarczycy pod kontrolą ultrasonograficzną. Medmedia 2010: 259–266.*
8. Dighe M, Kim J, Luo S, Kim Y. Utility of the ultrasound elastographic systolic thyroid stiffness index in reducing fine-needle aspirations. *J Ultrasound Med 2010; 29: 565–574.*
9. Bae U, Dighe M, Dubinsky T et al. Ultrasound thyroid elastography using carotid artery pulsation: preliminary study. *J Ultrasound Med 2007; 26: 797–805.*
10. Lyschchik A, Higashi T, Asato R et al. Thyroid gland tumor diagnosis at US elastography. *Radiology 2005; 237: 202–211.*
11. Rago T, Santini F, Scutari M et al. Elastography: new developments in ultrasound for predicting malignancy in thyroid nodules. *J Clin Endocrinol Metab 2007; 92: 2917–2922.*
12. Wang Y, Dan HJ, Dan HY et al. Differential diagnosis of small single solid thyroid nodules using real-time ultrasound elastography. *J Int Med Res 2010; 38: 466–472.*
13. Lagalla R, Caruso G, Novara V et al. Flowmetric analysis of thyroid diseases: hypothesis on integration with qualitative color-Doppler study. *Radiol Med 1993; 85: 606–610.*
14. Ueno E, Ito A. Diagnosis of breast cancer by elasticity imaging. *Eizo Joho Medical 2004; 36: 2–6.*
15. Tunbridge WM, Evered DC, Hall R et al. The spectrum of thyroid disease in a community: the Whickham survey. *Clin Endocrinol (Oxf) 1977; 7: 481–493.*
16. Vander JB, Gaston EA, Dawber TR. The significance of nontoxic thyroid nodules. Final report of a 15-year study of the incidence of thyroid malignancy. *Ann Intern Med 1968; 69: 537–540.*
17. Ezzat S, Sarti DA, Cain DR et al. Thyroid incidentalomas. Prevalence by palpation and ultrasonography. *Arch Intern Med 1994; 154: 1838–1840.*
18. Cooper DS, Doherty GM, Haugen BR et al. Revised American Thyroid Association Management Guidelines for Patients with Thyroid Nodules and Differentiated Thyroid Cancer. *Thyroid 2009; 19: 1167–1214.*
19. Gharib H, Papini E, Valcavi R et al. American Association of Clinical Endocrinologists and Associazione Medici Endocrinologi medical guidelines for clinical practice for the diagnosis and management of thyroid nodules. *Endocr Pract 2006; 12: 63–102.*
20. Diagnostyka i leczenie raka tarczycy. Praca zbiorowa przygotowana przez Polską Grupę ds. Nowotworów Endokrynnych. Gliwice-Zakopane 2010
21. Gietka-Czernel M. Wole guzowate obojętne. *Medycyna po Dyplomie 2008; Zeszyt edukacyjny 2008; 7: 25–28.*
22. Sipos JA. Advances in ultrasound for the diagnosis and management of thyroid cancer. *Thyroid 2009; 19: 1363–1372.*
23. Rago T, Vitti P. Role of thyroid ultrasound in the diagnostic evaluation of thyroid nodules. *Best Pract Res Clin Endocrinol Metab 2008; 22: 913–928.*
24. Frates MC, Benson CB, Charboneau JW et al. Management of thyroid nodules detected at US: Society of Radiologists in Ultrasound Consensus Conference Statement. *Radiology 2005; 237: 794–800.*
25. Fukunari N, Nakano M, Sakaue S et al. Clinical evaluation of thyroid elastography for the differential diagnosis of follicular tumors. *Endocrinol J 2010; 57 (Suppl. 2): S461.* 14 International Congress of Endocrinology (ICE 2010) Kyoto Japan.
26. Słowińska-Klencka D, Sporny S, Klencki M et al. Przewlekłe zapalenie tarczycy-aktualny problem w diagnostyce cytologicznej tarczycy. *Pol J Endocrinol 2006; 57: 300–306.*
27. Nikiforova MN, Caudill CM, Biddinger P et al. Prevalence of RET/PTC rearrangements in Hashimoto thyroiditis and papillary thyroid cancer. *Int J Surg Pathol 2002; 10: 15–22.*
28. Rhoden KJ, Unger K, Salvatore G et al. RET/papillary thyroid cancer rearrangement in nonneoplastic thyrocytes: follicular cells of Hashimoto's thyroiditis share low-level recombination events with a subset of papillary carcinoma. *J Clin Endocrinol Metab 2006; 91: 2414–2423.*
29. Adamiran AJ, Zhu Z, Gandhi M et al. Correlation between genetic alterations and microscopic features, clinical manifestations and prognostic characteristics of thyroid papillary carcinomas. *Am J Surg Pathol 2006; 30: 216–222.*