



From four-parathyroid gland exploration to a minimally invasive technique. Minimally invasive parathyroidectomy as a current approach in surgery for primary hyperparathyroidism

Od preparowania czterogruczołowego do technik małoinwazyjnych.
Małoinwazyjna paratyroidektomia jako obecny standard chirurgii pierwotnej nadczynności przytarczyc

Jarek Kobiela¹, Łaski Dariusz¹, Aneta Stróżyk², Monika Proczko-Markuszczyńska¹, Tomasz Stefaniak¹, Krzysztof Sworzak³, Andrzej J. Łachiński¹, Zbigniew Śledziński¹

¹Department of General, Endocrine and Transplant Surgery, Medical University of Gdansk — Invasive Medicine Centre, Gdansk, Poland

²First Department of Cardiology, Medical University of Gdansk, Gdansk, Poland

³Department of Endocrinology, Medical University of Gdansk, Poland

Abstract

Complete surgical resection of hyperfunctioning parathyroid tissue is essential for the treatment of primary hyperparathyroidism. During recent years, minimally invasive surgery has been successfully applied in neck exploration, because of significant developments of guidance by intraoperative scans, the use of quick, intraoperative PTH assay, and also preoperative imaging procedures such as high-resolution ultrasonography and sestamibi scintigraphy. The results of operations which are performed with minimally invasive techniques are comparable to those of conventional surgery, and provide advantages with regard to cosmetic result, length of hospitalisation, and reduced post-operative pain. (*Endokrynol Pol* 2014; 65 (3): 240–249x)

Key words: primary hyperparathyroidism; conventional neck exploration; minimally invasive parathyroidectomy

Streszczenie

Całkowite chirurgiczne usunięcie nadczynnej tkanki gruczołowej jest kluczowe dla leczenia pierwotnej nadczynności przytarczyc. Podczas ostatnich lat, techniki chirurgii małoinwazyjnej były z sukcesem wprowadzane do preparowania tkanek szyi. Było to możliwe dzięki opracowaniu śródoperacyjnych metod lokalizowania zmienionej tkanki, szybkim testom oznaczającym stężenie PTH w surowicy, jak również doskonaleniu technik obrazowania przedoperacyjnego, takich jak ultrasonografia wysokiej rozdzielczości czy scyntygrafia z wykorzystaniem sestamibi. Wyniki operacji z wykorzystaniem technik małoinwazyjnych są porównywalne z wynikami technik konwencjonalnych oraz wiążą się z zaletami, takimi jak skrócony okres hospitalizacji, zmniejszenie bólu pooperacyjnego czy lepszy efekt kosmetyczny. (*Endokrynol Pol* 2014; 65 (3): 240–249)

Słowa kluczowe: pierwotna nadczynność przytarczyc; konwencjonalne preparowanie tkanek szyi; minimalnie inwazyjna paratyroidektomia

Introduction

The first successful surgery of the parathyroid gland was performed by Felix Mandel in Vienna in 1925. The patient was symptomatic and had severe primary hyperparathyroidism with bone manifestation and calcinosis. The operation was performed under local anaesthesia; four parathyroid glands were identified, and a single enlarged parathyroid was excised. Since that time, the diagnostics and management of parathyroidism including surgery have been developed, resulting in a satisfactory outcome in 95–98% of operated patients [1, 2].

Pharmacological treatment of parathyroidism is quite costly and offers limited benefits. Parathyroidectomy has superior outcomes and is cost-effective both in symptomatic and asymptomatic primary hyperparathyroidism. It is recommended that those patients who are able and willing to undergo a surgical procedure should have a consultation with an experienced parathyroid surgeon [21].

As for surgical options for the treatment of primary hyperparathyroidism, there are two basic techniques. One is bilateral neck exploration, which is thought to be the 'gold standard'. This demands (as in the case de-



Jarek Kobiela M.D., Department of General, Endocrine and Transplant Surgery, Medical University of Gdansk — Invasive Medicine Centre, 17 Smoluchowskiego St., 80–211 Gdansk, Poland, e-mail: kobiela@gumed.edu.pl

scribed above) visualisation of all glands; their morphology determines the need for resection. The traditional neck exploration and excision of abnormal parathyroid tissue is effective and associated with low morbidity. Patients are usually discharged after a single-night hospital stay and are able to return to their normal activities within two weeks after the operation. The cure rates of this technique are 90-95%, with a complication rate of about 1-3%, which concerns mainly recurrent laryngeal nerve injury and temporary hypocalcaemia [2, 3].

Despite the success of the traditional surgical approach to parathyroid disease, an alternative approach that minimises the disability associated with surgery is always desirable. In recent years, radio-guided [5], endoscopic and video-assisted gasless techniques [1] have been used to develop a minimally invasive approach to surgery for primary hyperparathyroidism in order to limit patient discomfort, shorten convalescence, and, most importantly, improve the cosmetic result [3, 4]. In the setting of minimally invasive parathyroidectomy, pre-operative localisation of abnormal parathyroid tissue is absolutely mandatory. The development in imaging is thought to be the most important factor which allows this method to be performed with successful results. The definition of minimally invasive parathyroid surgery can be described as the removal of the affected parathyroid gland without four-gland visualisation. This is possible because primary hyperparathyroidism is caused by a solitary adenoma in 85-90% of cases. The avoidance of unnecessary exploration of normal parathyroids makes this technique desirable. It is further important in the context of avoiding making subsequent surgery in the thyroid region more difficult and more prone to complications.

Minimally invasive parathyroidectomy generally is classified into three main groups. The first group involves a small skin incision in the supraclavicular region with unilateral exploration. This method is sometimes performed under local anaesthesia. The second group is endoscopic

parathyroidectomy performed with CO₂ insufflation at a pressure of less than 4 mmHg (which is sufficient for lifting only the platysma) after inserting trocars through the skin of the neck, anterior chest or axilla (the last two approaches are also known as remote access endoscopic parathyroidectomy) [8]. The third group, gasless endoscopic parathyroidectomy, is performed using a small skin incision. This method is called 'video-assisted' parathyroidectomy. The operating field is clearly identified with a high-magnification video camera, and the whole field can also be visualised from a remote position [5, 6]. Sometimes, complete endoscopic and video-assisted approaches (video-endoscopic parathyroidectomy), video-assisted and open approach (open videoscopically magnified parathyroidectomy) are used in combination [19].

These minimally invasive parathyroidectomy techniques are performed with low morbidity and excellent cure rates in patients with primary hyperparathyroidism.

Indications and contraindications

The most common causes of hyperparathyroidism can be described using the acronym RHINOS [50]:

- R — Renal insufficiency (secondary and tertiary hyperparathyroidism)
- H — Hyperparathyroidism (solitary and combined in MEN1 and MEN2a)
- I — Immobilisation and iatrogenic (overdosage of calcium, vitamin D, thiazids)
- N — Neoplasms (bone metastasis, primary bone cancer and paraneoplastic syndromes)
- O — Other endocrinopathies (thyrotoxicosis and Addison's disease)
- S — Sarcoidosis

Recommendations for parathyroidectomy formulated by the National Institutes of Health Consensus Conference on Hyperparathyroidism in 1991 were widened in 2002 and 2008 [22] (Table I).

Table I. Recommendations for parathyroidectomy

Tabela I. Rekomendacje dotyczące wycięcia przytarczyc

Serum calcium (> upper limit of normal)	1.0 mg/dL (0.25 mmol/L)
Urine calcium excretion	> 400 mg/day (*not indicated after 2008)
Creatinine clearance	Reduced by 30% compared to age-matched control patients (< 60 mL/min *2008)
Bone mineral density	T-score < -2.5 at any site and/or previous fracture fragility
Patient who is symptomatic	Bone pain of osteitis fibrosa cystica Significant neuromuscular symptoms
Nephrolithiasis	Clinically or detected radiographically
Life-threatening hypercalcaemia:	One previous episode
Patient age	Under 50
Surveillance not desirable or suitable	

Most patients with biochemically proven primary hyperparathyroidism can undergo minimally invasive parathyroidectomy. Contraindications for the minimally invasive technique include [1, 3, 4, 18]:

- the presence of multiglandular disease;
- the presence of multiple endocrine neoplasia, malignancy [48];
- the presence of concomitant thyroid disease (relative);
- previous neck surgery or irradiation of the neck;
- nodular goitre;
- lithium associated primary hyperparathyroidism;
- failure to localise the adenoma preoperatively;
- unfavourable surgical anatomy.

Operating techniques

Preoperative localisation of hyperfunctioning parathyroid gland

The preoperative localisation studies usually consist of high-resolution ultrasonography and sestamibi-^{99m}Tc subtraction scintigraphy with SPECT (single positron emitted computed tomography) imaging [5, 8]. Modern ultrasound systems still cannot visualise the normal parathyroid glands, whereas enlarged, hyperfunctional glands can be identified not only on the basis of their size and oval shape, but also because of their characteristic ultrasound features including hypoechogenicity, typical intraglandular blood flow, movability and noncompressibility [10]. Compared to ultrasonography, sestamibi scanning is more sensitive and specific with a comparable degree of accuracy (91% and 92% for each method respectively) [3]. Sestamibi accumulates well in hyperfunctioning parathyroid nodules quickly after intravenous injection, as parathyroid lesions usually get a high supply of blood [11].

Intra-operative blood sampling, PTH Assay- as evidence of biochemical cure during minimally invasive parathyroidectomy

Rapid intraoperative PTH assays should be routinely employed. Intraoperative serum PTH level quantification was first introduced in 1990, but has still not been accepted as the gold standard in PHPT (primary hyperparathyroidism) surgery. Potentially it can prolong the operating time [23], but measurement takes only 5–10 minutes [24]. Moreover, double adenomas have been reported in 2–15% of patients undergoing parathyroidectomy [25] and can be missed in up to 15% of patients diagnosed with single adenoma by sestamibi scan [26, 27]. This can lead to reoperations with increased risk of complications, unnecessary patient stress, and further potential costs. [24] Intraoperative PTH monitoring is thought to be a very

important element of parathyroid surgery, because it confirms that all hypersecreting parathyroid tissue has been excised, prevents multiglandular disease being overlooked, and helps to predict post-operative eucalcaemia during surgery by providing immediate information [19].

Blood samples are analysed using the Quick-IntraOperative Intact PTH assay (Nicholas Institute Diagnostics, San Juan Capistrano, CA, USA). PTH levels are measured four times during surgery:

- prior to surgical manipulation,
- at time 0, i.e. immediately following adenoma extraction,
- at 5 minutes after adenoma removal,
- at 10 minutes after adenoma removal.

A decrease in the level of parathyroid hormone is considered significant when it is equivalent to more than 50% of the highest pre-excisional value [7, 15]. Hormone levels typically decrease to normal range (15–50 pg/mL) [9] within 10 minutes after removing the abnormal gland (Fig. 1).

Targeted open parathyroidectomy

Surgical procedure

Patients are positioned on the operating table in a reverse Trendelenburg position with their head hyperextended. The surgeon administers a superficial cervical block employing 1% lidocaine with a 1:100,000 solution of epinephrine. The surgical procedure is performed through a 2-cm to 3-cm incision at the medial border of the sternocleidomastoid muscle, precisely over the site where the enlarged gland had been located by preoperative imaging. With the sternocleidomastoid muscle and internal jugular vein retracted laterally, and the strap muscles medially, the thyroid gland is grasped in Ellis forceps and held in the medioventral

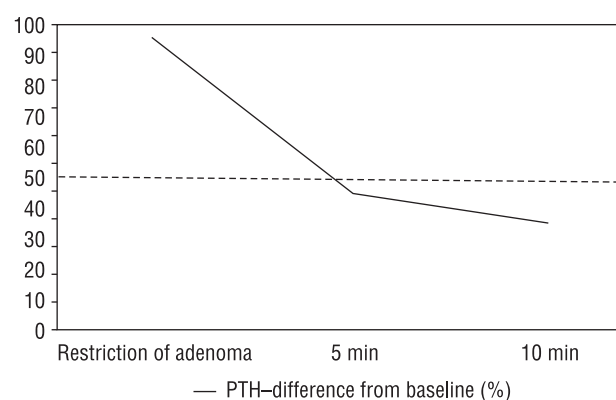


Figure 1. Exemplary PTH drop monitored by intraoperative quick PTH assay

Rycina 1. Przykładowy spadek stężenia parathormonu w badaniu śródoperacyjnym

direction. The parathyroid adenoma is identified, its blood supply is ligated, the recurrent laryngeal nerve is protected, and the adenoma is removed. The wound is closed while awaiting the results of the intraoperative PTH assay [2, 10].

Endoscopic parathyroidectomy

Surgical procedure

In 1996, Gagner et al. first described endoscopic parathyroidectomy [12] using gas (CO₂) insufflation through a cervical approach via a small cervical incision (supraclavicular position). This operation was complicated by intraoperative hypercarbia and extensive subcutaneous emphysema postoperatively (because of high carbon dioxide pressure) [6]. Nowadays, there is experimental evidence that insufflation in the extraperitoneal cavities such as the neck is completely harmless as long as the operation is performed under low pressure. Interestingly, a bilateral exploration is possible with this technique and it can also be used for total parathyroidectomy in the treatment of secondary hyperparathyroidism [5, 12].

Endoscopic parathyroidectomy by an anterior chest approach

Under general anaesthesia, the patient is placed in the supine position with the neck extended. The anterior chest approach involves a 5-mm skin incision in the chest (3.0 cm below the inferior border of the clavicle on both sides of the chest). The lower layer of the platysma is extracted manually. There are three 5 mm trocar-sites: one trocar is used to insert an endoscope and two additional trocars (inserted under endoscopic guidance: one inferior to the sternal notch and the other below the ipsilateral clavicle) are used to insert instruments. CO₂ is sufflated up to 4 mm Hg. In order to expose the parathyroid glands, the thyroid is rotated forward with the retractor through the opposite side 5-mm trocar. The adenoma is dissected with endoscopic scissors or a Harmonic Scalpel (Johnson-Johnson Medical, Cincinnati, OH, USA) to avoid injuring the recurrent laryngeal nerve. The specimen is placed in a finger of a plastic glove and extracted through the 5-mm skin incision. The other ipsilateral parathyroid gland is also explored and it is biopsied (if it appears normal) or dissected and removed (if it appears enlarged) [5]. A rapid PTH test for intraoperative assessment is performed. The topography of the approach is visualised in Figure 2.

Endoscopic parathyroidectomy by an axillary approach

Under general anaesthesia, the patient is placed in the supine position with the neck slightly extended and with raised arm in order to expose the axilla. A 30-mm skin incision is made in the axilla. The lower

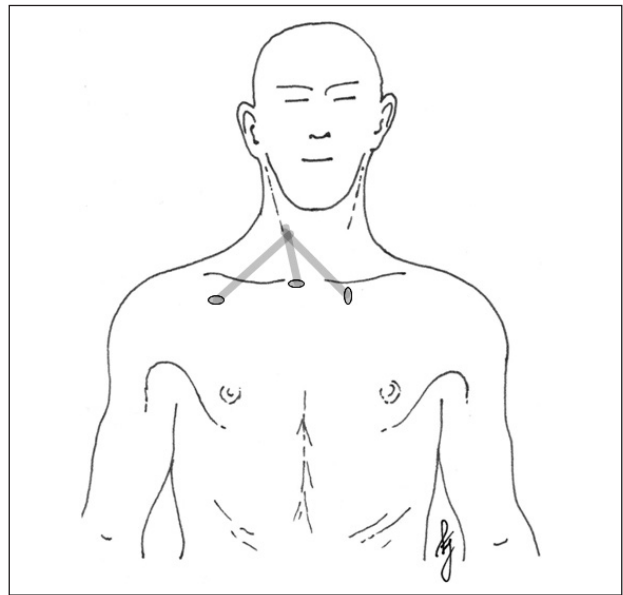


Figure 2. Topography of endoscopic parathyroidectomy by an anterior chest approach

Rycina 2. Topografia paratyroidektomii endoskopowej z dostępu klatkowego przedniego

layer of the platysma is extracted through the upper layer of the pectoralis major muscle. A 12-mm trocar and a 5-mm trocar are inserted through this incision. After ensuring the prevention of gas leakage and trocar slippage out of the wound, CO₂ is sufflated up to 4 mmHg and a flexible endoscope is inserted through the trocar. An additional 5-mm trocar is inserted inferior to the 30-mm skin incision. The thyroid gland is exposed by splitting the sternothyroid muscle and it is rotated forward to reveal the parathyroid glands. The adenoma is dissected with endoscopic scissors or a Harmonic Scalpel. As for the other ipsilateral parathyroid gland and intra-operative PTH monitoring, the procedure is similar to that described above [8]. The topography of this approach is visualised in Figure 3.

Endoscopic parathyroidectomy by a cervical approach

This procedure is performed totally endoscopically under a steady gas flow. It requires general anaesthesia [19, 20]. Small incisions are made for 3-mm, 5-mm and 10-mm trocars. One trocar is used to insert the endoscope and two additional ones are used to insert the instruments. Dissection is first performed below the platysma in order to obtain a good working space. Exploration of the parathyroid glands is carried out after dissection of the thyroid from the investing fascia [12]. Bilateral exploration by this method is possible but time-consuming.

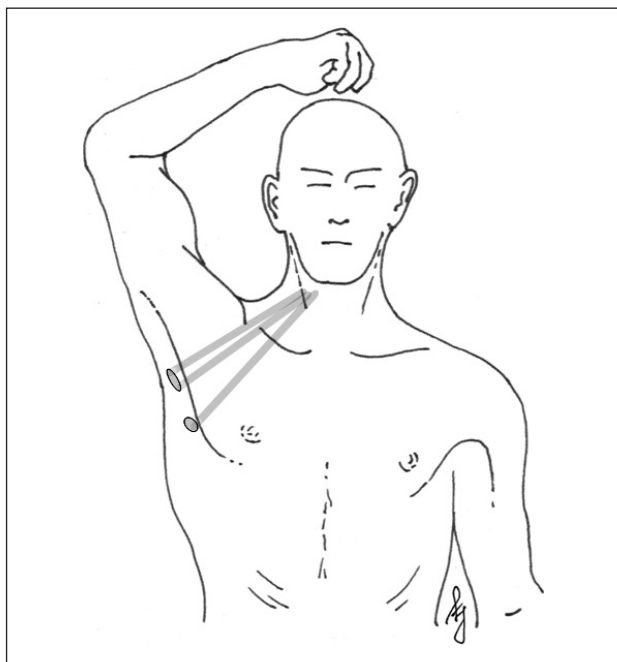


Figure 3. Topography of endoscopic parathyroidectomy by an axillary approach

Rycina 3. Topografia paratyroidektomii endoskopowej z dostępu pachowego

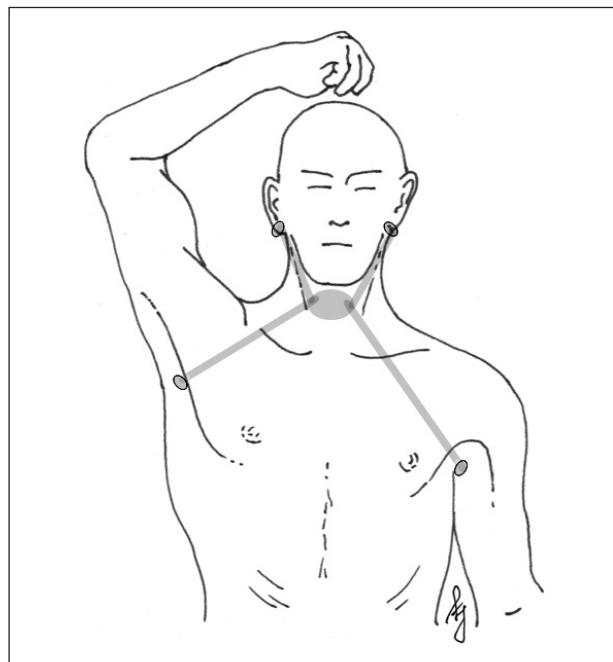


Figure 4. Topography of endoscopic parathyroidectomy by a postauricular approach

Rycina 4. Topografia paratyroidektomii endoskopowej z dostępu zauszynego

Endoscopic parathyroidectomy by a postauricular approach

Spinal needles are used to subcutaneously infiltrate the subplatysmal space of the neck and the subcutaneous space of the axillary and anterior chest area with epinephrine solution (0.1 mL of epinephrine [1:1,000] in 200 mL of normal saline). The infiltration provides space for flap dissection and prevents bleeding. A 12-mm axillary incision is made at the lesion's side, and the subplatysmal and subcutaneous spaces are dissected bluntly using a vascular tunneller. After establishing the required working space, a 12-mm trocar is inserted and the operating space under the flap is insufflated with low-pressure carbon dioxide (5–6 mm Hg). Another incision is made on the contralateral axillary region and a 5-mm trocar is inserted. Bilateral postauricular incisions are then made and two 5-mm trocars are inserted. The midline is estimated by external palpation. A midline incision is made between the strap muscles from the level of the thyroid cartilage to the suprasternal notch. After division of the midline of the strap muscles, the parathyroid gland is excised [28]. Bilateral exploration by this method is possible but time-consuming. The topography of the approach is visualised in Figure 4.

Video-assisted parathyroidectomy

Video-assisted parathyroidectomy is typically performed by a central (Miccoli et al.) or a lateral (Henry

et al.) approach in the line of the sternocleidomastoid muscle [6].

Surgical procedure

Video-assisted parathyroidectomy by central approach

In order to perform this minimally invasive technique, the operating surgeon needs two assistants. The surgical procedure is carried out through a 10–15-mm skin incision at the suprasternal notch (so it is easy to convert to the open method) [6]. The cervical mid-line is opened and complete dissection of the thyroid lobe is obtained by blunt dissection with small instruments under endoscopic vision (without trocar insertion or gas insufflation) using a 30 degree 5-mm endoscope. Small conventional retractors maintain the optimal visualisation of the surgical field by lifting the skin. Needleoscopic instruments (2–3-mm): suction, dissector, and elevator are inserted through the same incision and are used for the dissection. If another parathyroid tumour is found in the ipsilateral side, this gland is also removed [6, 19]. Optical identification of the cervical structures is amplified by videoscopic magnification, which also allows easy recognition of the recurrent laryngeal nerve [12, 13]. After removal of the adenoma, a quick parathyroid hormone assay excludes the presence of any residual hyperfunctioning parathyroid tissue [14]. Bilateral exploration by this method is easy to perform [12].

Video-assisted parathyroidectomy by lateral approach

This procedure also requires experienced assistants and special equipment. The lateral approach is characterised by a 12-mm skin incision on the medial border of the sternocleidomastoid muscle on the side of the supposed lesion. It combines two approaches: complete endoscopic and video-assisted. A 10-mm trocar is inserted into the same place as the endoscope (10-mm, zero degrees), and insufflation is carried out at 8 mm Hg. Two small trocars (3-mm) for the instruments for the dissection are inserted above and below the first trocar along the medial margin of the sternocleidomastoid muscle. A quick parathyroid hormone assay can be used with this procedure. A bilateral exploration is impossible with this method, because of the unique lateralisation [12].

The topography of both video-assisted approaches is visualised in Figure 5.

Radio-guided parathyroidectomy

Radio-guided parathyroidectomy was first described by Norman and Chheda in the mid-1990s [16]. This technique utilises preoperative intravenous injection of sestamibi and intraoperative navigation by portable gamma cameras and hand-held gamma-ray detectors. These modern technologies allow all parathyroid operations to be performed through a small 1 inch (2.5 cm) incision [12].

Preoperative procedure

Pre-operatively, patients are injected with a low dose of sestamibi with or without methylene blue dye, which in the past has been shown to localise adenomas [3]. Readouts are obtained after 5 mins, 1 h and 2 h following the injection. These images are useful for intraoperative nuclear mapping [6, 49]. The radio-guided method is also effective for ectopic lesions that are located in the deep area of the mediastinum, where direct visual observation is difficult. The intra-operative navigation by gamma-probe can easily lead the surgeon to ectopic locations of hyperfunctioning parathyroid glands. A hyperfunctioning parathyroid lesion can be clearly detected and easily resected by the radio-guided method when sestamibi is well retained in the lesion in the delayed phase- positive sestamibi scan (in about 85–90% of patients). If the activity of the lesions in the delayed images is faint, and the retention of sestamibi is thought to be poor, (which occurs in about 10-15% of patients), the radio-guided technique is not attempted [11, 17].

Surgical procedure

Radio-guided parathyroidectomy is performed using local anaesthesia with some *i.v.* sedation, or using a very light general anaesthesia called LMA which al-

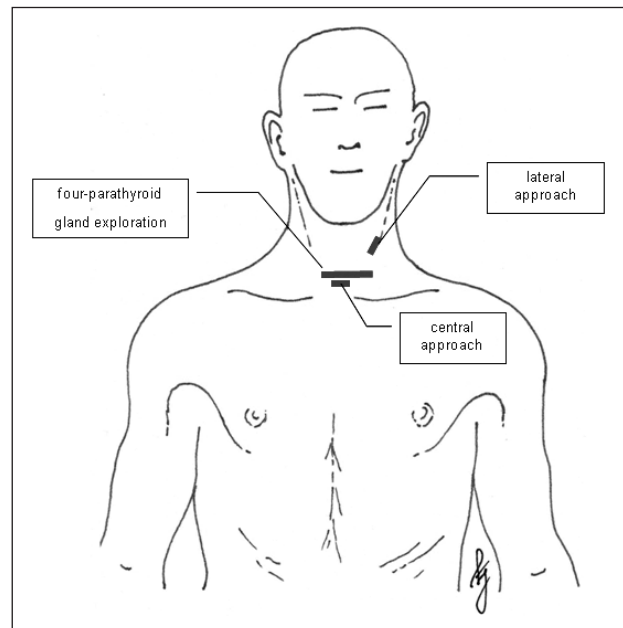


Figure 5. Topography of video-assisted parathyroidectomies compared to a four-parathyroid gland exploration

Rycina 5. Topografia paratyroidektomii w asyście wideoskopii w porównaniu do eksploracji czterogruczołowej

lows the patients to be out for the procedure, but awake enough that they breathe for themselves and wake up completely within a minute or two [17]. The operation is performed with unilateral resection technique through a transverse midline or unilateral neck incision, typically of 2.5 cm. The radioactivity is measured on the parathyroid adenoma and the probe used directs the surgeon right to it and guides the excision [3]. The average operating time to remove the hyperfunctioning parathyroid gland using the radio-guided technique is about 25 minutes [17]. Confirmation of removal of all the hyperfunctioning tissue can be obtained through intra-operative scintigraphy, thereby avoiding additional costs from quick parathyroid hormone assay or frozen section. This technique does not allow bilateral exploration [12].

NOTES (Natural orifice transluminal endoscopic surgery)

Transluminal endoscopic interventions via so-called 'natural orifices' allow operating treatment without any incision of the skin, but they are still in the experimental phase. It is possible to perform thyroid and parathyroid surgery via transoral access.

Surgical procedure

Access is accomplished via a 20-mm incision in the lateral floor of the mouth. After identification of the lingual nerve and Wharton's duct, the mylohyoid muscle is

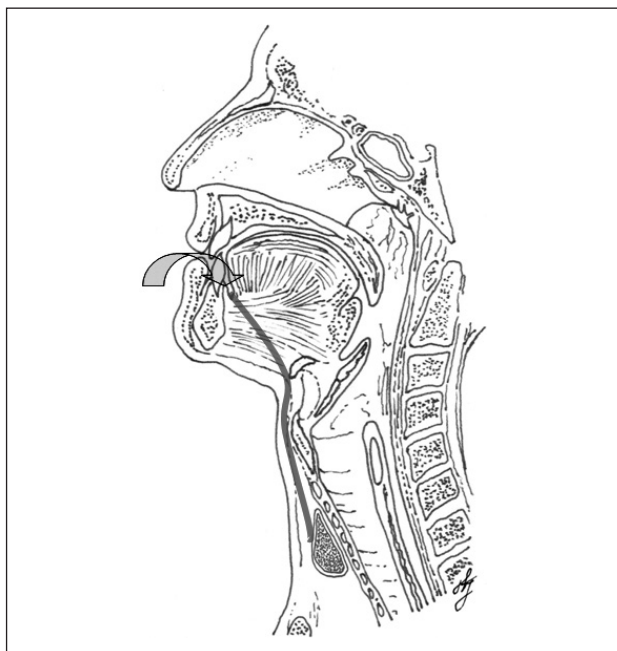


Figure 6. Topography of NOTES approach

Rycina 6. Topografia dostępu NOTES

identified and retracted medially. Additional dissection in the direction of the hyoid bone is performed using a rigid cervicoscope. This dissection is passed between the submandibular gland and the hyoglossal muscle. The hyoglossal nerve lying on the hyoglossal muscle is identified and preserved. The hyoid bone is passed ventrally in the lateral aspect of the hyoid because the thyrohyoid and sternohyoid muscles originate from the anterior part of the hyoid bone. This blunt dissection is performed carefully because of the proximity of the superior laryngeal nerve and its internal branch — the internal laryngeal nerve. The thyroid region is entered laterally and posterior to the infrahyoid muscles as well as the superior pole of the thyroid. The vessels to the upper pole of the thyroid are reached by pushing aside fibres of the thyrohyoid muscle; these fibres partially cover the thyroid lobe. The vessels to the lower pole of the thyroid, the inferior thyroid artery, the trachea, and the recurrent laryngeal nerve are then visualised. The parathyroid glands on one side, posterior to the recurrent laryngeal nerve and cranial to the inferior thyroid artery (upper parathyroid gland), as well as anterior to the recurrent laryngeal nerve and distal to the thyroid artery (lower parathyroid gland), respectively, are localised and can be resected [29]. The topography of this approach is visualised in Figure 6.

RATS (Robot assisted transaxillary surgery)

A single incision, robot assisted transaxillary surgical technique to remove benign endocrine tumours of the

neck is a feasible option. This technique can be standardised in properly selected patients. Despite longer operating times (> 100 min), very high costs, and the high possibility of complications noted (28.5%) in an initial series, the excellent three-dimensional visibility and the benefit of instrument stability makes RATS an interesting addition to the armamentarium of the endocrine surgeon. Further study and refinement of RATS are warranted prior to its widespread incorporation into clinical practice [30]. This technique does not allow bilateral exploration.

Surgical procedure

The patient is placed in a supine position on the operating table. The patient's ipsilateral arm is positioned so that the shoulder is flexed to approximately 160°, and internally rotated. After assuring that the patient is comfortable, the patient is sedated and intubated with general endotracheal anaesthesia.

A 5–6-cm longitudinal incision is made along the outer border of the pectoralis major muscle. Skin flaps are developed immediately superficial to the pectoralis fascia and extended medially and inferiorly to the clavicle and sternal notch.

The robot is positioned over the patient. Three robotic tools are secured into the robotic arms and the camera is placed at the inferior border of the incision. The camera and instruments are deployed under direct visualisation. The bedside operating surgeon retracts the carotid and internal jugular vessels laterally using a laparoscopic bolstered sponge. The assistant surgeon maintains a clear field using laparoscopic suction as needed. The console surgeon then proceeds to perform surgery robotically in a conventional fashion. [30]

Discussion

The aims of any operating techniques (including conventional neck exploration) used to treat primary hyperparathyroidism are:

- removal of all hyperfunctioning tissue;
- preservation of normal tissue (parathyroid glands)
 - to avoid hypoparathyroidism;
- avoidance of persistent primary hyperparathyroidism;
- not injuring the recurrent nerve [12];
- safety for patients and as small as possible risk of post-operative complications;
- good patient condition after operation.

It has been proven beyond question that minimally invasive surgery is performed with low morbidity, has good cosmetic results, and results in a small if any decrease in the patient's quality of life. But we must remember that the cumulative length of all scars in

the axilla or anterior chest may be longer than in open parathyroid surgery. A better cosmetic effect is based on a transfer of scars into less visible places. Patients who have had endoscopic parathyroidectomies have been significantly more satisfied with their scars compared to an open approach [31, 32].

Furthermore, some difficulties and complications should be remembered when neck surgery by minimally invasive techniques is performed. The first of these concerns the removal of parathyroid adenoma through a small incision or through an endoscopy port or cannula, because it provides a risk for rupture of the adenoma, which can lead to parathyromatosis [1]. Parathyromatosis is a rare cause of hyperparathyroidism. The condition was originally described by Palmer et al. in 1975 [35]. About 30 cases have been reported in the literature. Type 1 parathyromatosis is caused by embryologic development of multiple parathyroid glands. Type 2 parathyromatosis, which is more common, is a surgical complication associated with spillage and seeding of parathyroid tissue during parathyroidectomy [36]. The treatment of this rare condition is difficult. Usually repeated neck explorations are often unsuccessful. Alcohol ablation and several novel calcimimetics have been used in patients with unsuccessfully treated parathyromatosis, but experience is limited [37]. Parathyromatosis can be a problem in patients with secondary hyperparathyroidism (with chronic renal failure) due to constant stimulation of remaining seeded parathyroid tissue after initial parathyroidectomy [37, 38].

Disruption of parathyroid tissue from its vascular supply may lead to transitory hypoparathyroidism. Patients after parathyroidectomy should receive oral calcium and vitamin D3 immediately after surgery (patients with secondary HPT may not have symptoms related to hypocalcaemia, unlike patients after parathyroidectomy for PHPT). Empirical oral vitamin D3 and oral calcium supplementation is usually satisfactory. Intravenous calcium is reserved for patients with severe symptomatic hypocalcaemia [44, 45]. Symptomatic postoperative hypocalcaemia occurs in about 7% of patients on calcium supplementation. 0.1% of all patients require an emergency visit for *i.v.* calcium. Patients' emergency visits are particularly rare when patients are well-educated, receive a supply of calcium supplements at discharge, and are managed appropriately. Hand 'tingling' and paresthesia followed by perioral tingling and mental fog occur as the most frequent symptoms (82% of symptomatic patients). Cramps of the hands occur in only 4% of patients with symptoms, and 0.3% of all operated patients. The onset of symptoms almost always occurs on postoperative day 2 or later. Less than 0.2% of all operated patients report symptoms of low

calcium on postoperative day 1. [39] At least during the first two weeks, or until serum calcium stabilises, serum calcium has to be monitored. Vitamin D supply may be reduced to a low dosage but hypocalcaemia, as one of the strongest activators in the development of SHPT, should be carefully avoided to protect patients from recurrent disease [42]. Hungry bone syndrome may follow parathyroidectomy [46, 47]. This condition is marked by extensive hypophosphataemia and hypocalcaemia, mostly refractory to oral supplementation [40–47, 51].

Unilateral exploration-targeted open parathyroidectomy is usually performed under local anaesthesia. The quite common disadvantage of this type of anaesthesia is neck swelling (oedema), but most patients who experience such discomfort recover quickly postoperatively with complete resolution of symptoms [13]. Another difficulty associated with minimally invasive open parathyroidectomy is limited visualisation of the operating field - only one person at a time can see into the incision.

As for unilateral exploration, there is one more thing which is very important: if the surgeon needs to explore both sides of the neck, it is more difficult to convert a lateral wound to a standard approach [12]. The most common reasons for conversion are: inability to visualise the adenoma, bleeding, and incorrect localisation by the sestamibi scans [1].

Problems are associated with endoscopic procedures themselves. They are as follows: subcutaneous emphysema (because of long insufflation time), hypercapnia, respiratory acidosis, air embolism, inadvertent pneumothorax and tachycardia. There is a 2.2% risk of forming a seroma in the area of extensive dissection, even if there is a suction drain inserted [33]. Furthermore, an endoscopic approach may lead to difficulties in visualisation (because of bleeding), some problems connected with maintenance of working space, post-operative minimal hypesthesia and paresthesia [1]. In addition, endoscopic parathyroidectomy can be impractical because of the extensive exploration from anterior chest or axilla to the neck, and difficulty in identifying contralateral or infraclavicular ectopic parathyroid glands [8].

We have to remember that some of the procedures discussed above are still experimental or performed only in high volume centres as initial trials. Also, the costs of some procedures (e.g. RATS, NOTES) limit significantly their wider introduction to everyday surgical practice.

Currently, minimally invasive techniques of parathyroidectomy are performed with successful outcomes. In Poland, there have been described only single cases of experimental techniques of minimally invasive parathyroidectomy and a small series of video-assisted parathyroidectomies (n = 15) but preliminary outcomes

are very promising. The complication rate is below 3%, the success rate is high, and the cosmetic effect is satisfactory (in subjective patient opinion after six months, 'good' or 'excellent' cosmetic effect was achieved in 90-96%) [52].

Compared to conventional neck exploration, mini-invasive techniques provide [1]:

- decreased pain (because the small wound heals quickly),
- decreased complication rates,
- shorter hospital stay,
- shorter duration of surgery (except for endoscopic, RATS, NOTES approaches),
- fast reconstitution,
- improved cosmetic appearance,
- cost reduction (as for radio-guided approach),
- performed with low morbidity with long-term cure rate ~97% (whereas traditional neck exploration is performed with > 95%).

The surgeon's experience has a significant influence on the outcome of parathyroid surgery. Minimally invasive approaches require expertise in the anatomy of the neck, parathyroid pathology, and the combination of both. Most difficulties can be avoided or overcome thanks to the knowledge built on surgical training and ongoing experience. The learning curve is very steep, but it has been proven that the length of surgery decreases with surgical experience, and may possibly improve with advances in surgical instruments [34].

Conclusion

The assessment of morbidities associated with the techniques of unilateral and bilateral exploration for minimally invasive parathyroidectomy has shown benefits using either technique. The advantages of minimally invasive parathyroidectomy are clear. Performing minimally invasive surgery when possible, and converting to conventional neck exploration if necessary, enables safe surgery with a minimal risk of complications. Most minimally invasive methods are significantly less time-consuming (in experienced hands) and cosmetically attractive. The scars are not necessarily smaller than 'classic' ones in the neck, but they are in an area that is covered by clothing. Minimally invasive parathyroid surgery (video-assisted, radio-guided and targeted open parathyroidectomy) is expected to become the gold standard treatment of primary hyperparathyroidism.

Acknowledgements

Authors would like to acknowledge Mr Jerzy Łaski for preparation of the figures.

References

1. Reeve TS, Babidge WJ, Parkyn RF et al. Minimally invasive surgery for primary hyperparathyroidism: A systematic review. *Aust NZJ Surg* 2000; 70: 244–250.
2. Udelsman R, Donovan PI. Open Minimally Invasive Parathyroid Surgery. *World J Surg* 2004; 28: 1224–1226.
3. Cordes B. Minimally-Invasive Parathyroid Surgery. 2006; Baylor College of Medicine. Bobby R. Alford Department of Otolaryngology-Head and Neck Surgery.
4. Fuhrman GM, Bolton JS. Department of Surgery, Ochsner Clinic and Alton Ochsner Medical Foundation, New Orleans, LA. Minimally Invasive Parathyroid Surgery. *Ochsner J* 2000; 2: 168–171.
5. Ikeda Y, Takami H, Tajima G et al. Parathyroid Total endoscopic parathyroidectomy. *Biomed Pharmacother* 2002; 56: 22–25.
6. Suzuki S, Fukushima T, Ami H et al. Parathyroid Video-assisted parathyroidectomy. *Biomed Pharmacother* 2002; 56: 18–21.
7. Dillavous ED, Cohn HE, FACS. Minimally invasive parathyroidectomy: 101 Consecutive Cases from a Single Surgeon. *J Am Coll Surg* 2003; 197: 1–7.
8. Ikeda Y, Takami H. Endoscopic parathyroidectomy. *Biomed & Pharmacother* 2000; 54 (Suppl. 1): 52–56.
9. Watanabe T, Mochizuki H, Kohda N et al. Autosomal dominant familial hypoparathyroidism and sensorineural deafness without renal dysplasia. *European Journal of Endocrinology* 1998; 139: 633.
10. Smit PC, Borel Rinkes IH, van Dalen A et al. Minimally Invasive Adenectomy for Primary Hyperparathyroidism An Alternative to Conventional Neck Exploration? *Ann Surg* 2000; 231: 559–565.
11. Fujii H, Kubo A. Parathyroid sestamibi scintigraphy for the application of minimally invasive surgery of hyperfunctioning parathyroid lesions. *Biomed & Pharmacother* 2002; 56: 7–13.
12. Miccoli P, Berti P. Minimally invasive parathyroid surgery. *Best Practise & Research Clinical Endocrinology and Metabolism* 2001; 15: 139–147.
13. Lorenz K, Phuong N-T, Dralle H. Diversification of Minimally Invasive Parathyroidectomy for Primary Hyperparathyroidism: Minimally Invasive Video-assisted Parathyroidectomy and Minimally Invasive Open Videoscopically Magnified Parathyroidectomy with Local Anesthesia. *World J Surg* 2002; 26: 1066–1070.
14. Miccoli P, Beneditelli C, Vignali E et al. Endoscopic parathyroidectomy: report of an initial experience. *Surgery* 1988; 124: 1077–1080.
15. Irvin GL III, Sfakianakis G, Yeung L et al. Ambulatory parathyroidectomy for primary hyperparathyroidism. *Archives of Surgery* 1996; 131: 1047–1078.
16. Norman J, Chheda H. Minimally invasive parathyroidectomy facilitated by intraoperative nuclear mapping. *Surgery* 1997; 122: 998–1003.
17. University of South Florida, Norman J. Minimally invasive radio-guided parathyroidectomy. *American Surgeon* 1997; 44: 235–230.
18. Australian Safety and Efficacy Register of New Interventional Procedures- Surgical. Minimally invasive surgery for primary hyperparathyroidism 2001; (Update&Reappraisal).
19. Inabnet WB, FACS; Columbia University. New York. Endoscopic parathyroidectomy *Otolaryngol Clinics North Am* 2004; 37.
20. Inabnet WB, Rogula T. Endoscopic parathyroidectomy: is there a role? *Problems in General Surgery* 2003; 20: 38–43.
21. Zanocco K, Heller M, Sturgeon C. Cost-effectiveness of parathyroidectomy for primary hyperparathyroidism. *Endocr Pract* 2011; 17.
22. Bilezikian JP, Khan AA, Potts JT Jr. and on behalf of the Third International Workshop on the Management of Asymptomatic Primary Hyperthyroidism. Guidelines for the Management of Asymptomatic Primary Hyperparathyroidism: Summary Statement from the Third International Workshop. *J Clin Endocrinol Metab* 2009; 94: 335–339.
23. Agarwal G, Barakate MS, Robinson B et al. Intraoperative quick parathyroid hormone versus same-day parathyroid hormone testing for minimally invasive parathyroidectomy: a cost-effectiveness study. *Surgery* 2001; 130: 963–970.
24. Charfare H, Wassif WS. Intraoperative PTH Assay during Minimally Invasive Parathyroidectomy May Be Helpful in the Detection of Double Adenomas and May Minimise the Risk of Recurrent Surgery. *Int J Endocrinol* 2010; 2010: 178671.

25. Abboud B, Sleilaty G, Helou E et al. Existence and anatomic distribution of double parathyroid adenoma. *Laryngoscope* 2005; 115: 1128–1131.
26. Genc H, Morita E, Perrier ND et al. Differing histologic findings after bilateral and focused parathyroidectomy. *Journal of the American College of Surgeons* 2003; 196 (4): 535–540.
27. Lee NC, Norton JA, Dainko EA et al. Multiple-gland disease in primary hyperparathyroidism: a function of operative approach? *Archives of Surgery*. 2002; 137: 896–900.
28. Lee KY, Kim HY, Park WS et al. Postauricular and Axillary Approach Endoscopic Neck Surgery: A New Technique. *World J Surg* 2009; 33: 767–772.
29. Karakas E, Steinfeldt T, Gockel A et al. Transoral thyroid and parathyroid surgery—development of a new transoral technique. *Surgery* 2011; 150: 108–115.
30. Landry CS, Grubbs EG, Morris GS et al. Robot assisted transaxillary surgery (RATS) for the removal of thyroid and parathyroid glands. *Surgery* 2011; 149: 549–555.
31. Ikeda Y, Takami H, Sasaki Y et al. Comparative study of thyroidectomies. Endoscopic surgery versus conventional open surgery. *Surg Endosc* 2002; 16: 1741–1745.
32. Ikeda Y, Takami H, Sasaki Y et al. Are there significant benefits of minimally invasive endoscopic thyroidectomy? *World J Surg* 2004; 28: 1075–1078.
33. Tan CT, Cheah WK, Delbridge L. “Scarless” (in the neck) endoscopic thyroidectomy (SET): an evidence-based review of published techniques. *World J Surg* 2008; 32: 1349–1357.
34. Kitano H, Fujimura M, Kinoshita T et al. Endoscopic thyroid resection using cutaneous elevation in lieu of insufflation. *Surg Endosc* 2002; 16: 88–91.
35. Palmer JA, Brown WA, Kerr WH et al. The surgical aspects of hyperparathyroidism. *Arch Surg* 1975; 110: 1004–1007.
36. Reddick RL, Costa JC, Marx SJ. Parathyroid hyperplasia and Parathyromatosis. *Lancet* 1977; 1: 549.
37. Tublin ME, Yim JH, Carty SE. Recurrent Hyperparathyroidism Secondary to Parathyromatosis — Clinical and Imaging Findings. *J Ultrasound Med* 2007; 26: 847–851.
38. Meakin JL, Milne CA, Hollombly DJ et al. Total parathyroidectomy: parathyroid hormone levels and supernumerary glands in hemodialysis patients. *Clin Invest Med* 1989; 7: 21–25.
39. Vasher M, Goodman A, Politz D et al. Postoperative calcium requirement 6,000 patients undergoing outpatient parathyroidectomy: easily avoiding symptomatic hypocalcemia. *J Am Coll Surg* 2010; 211: 49–54.
40. Pludowski P, Karczmarewicz E, Bayer M et al. Practical guidelines for the supplementation of vitamin D and the treatment of deficits in Central Europe — recommended vitamin D intakes in the general population and groups at risk of vitamin D deficiency. *Endokrynol Pol* 2013; 64: 319–327.
41. Szymczak J, Bohdanowicz-Pawlak A. Osteoprotegerin, RANKL, and bone turnover in primary hyperparathyroidism: the effect of parathyroidectomy and treatment with alendronate. *Horm Metab Res* 2013; 45: 759–764.
42. Kuczera P, Adamczak M, Więcek A. Safety and efficiency of treatment with cinacalcet of haemodialysed patients with chronic kidney disease and secondary hyperparathyroidism. *Endokrynol Pol* 2013; 64: 176–81.
43. Czech-Kowalska J, Pludowski P, Dobrzanska A et al. Impact of vitamin D supplementation on markers of bone mineral metabolism in term infants. *Bone* 2012; 51: 781–786.
44. Buła G, Koziołek H, Niemiec A et al. Management of patients with secondary and tertiary hyperparathyroidism referred to surgical treatment. *Endokrynol Pol* 2010; 61: 264–268.
45. Schlosser K, Zielke A, Rothmund M. Medical and surgical treatment for secondary and tertiary hyperparathyroidism. *Scand J Surg* 2004; 93: 288–297.
46. Gawrychowski J, Gabriel A, Kluczevska E et al. Mediastinal parathyroid carcinoma: a case report. *Endokrynol Pol* 2012; 63: 143–146.
47. Baszko-Błaszyk D, Biczysko M, Gut P et al. Delayed diagnosis of primary hyperparathyroidism in a patient with osteoclastoma. *Ortop Traumatol Rehabil* 2011; 13: 505–510.
48. Piecha G, Chudek J, Więcek A. Primary hyperparathyroidism in patients with multiple endocrine neoplasia type 1. *Int J Endocrinol; Epub* 2011; 17.
49. Cytawa W, Teodorczyk J, Lass P. Advantages of hybrid SPECT-CT imaging in preoperative localization of parathyroid glands in a patient with secondary hyperparathyroidism. A case report. *Pol J Radiol* 2013; 78: 81–84.
50. Myśliwiec J. Mnemonics for endocrinologists - hyperparathyroidism. *Endokrynol Pol* 2012; 63: 504–505.
51. Misiorowski W, Zgliczyński W. Prevalence of primary hyperparathyroidism among patients with low bone mass. *Adv Med Sci* 2012; 57: 308–313.
52. Barczyński M, Konturek A, Stopa M et al. Minimally invasive video-assisted thyroidectomy: seven-year experience with 240 cases. *Video-surgery Miniinv* 2012; 7: 175–180.