

# Occult breast primary malignancy presenting as isolated axillary lymph node metastasis — early detection of primary site by $^{18}\text{F}$ -FDG PET/CT

Ramya Soundararajan, Niraj Naswa, Sellam Karunanithi, Ritika Walia, Rakesh Kumar, Chandrasekhar Bal  
Department of Nuclear Medicine, All India Institute of Medical Sciences, New Delhi, India

[Received 21 XI 2014; Accepted 18 VIII 2016]

## Abstract

Breast cancer patients rarely present with isolated axillary lymph node metastasis without any clinical or radiological evidence of primary tumor. Identification of the primary site of tumor helps in planning appropriate patient management which has definite impact on patient's survival. We present here a case of 30-year-old female who presented with isolated right axillary lymph node metastasis with no evidence of primary tumor clinically. Conventional imaging modalities were negative for primary site. She underwent whole body  $^{18}\text{F}$ -Fluorodeoxyglucose (FDG) positron emission tomography (PET)/computed tomography (CT) and it contributed significantly in early detection of occult primary tumor in right breast.

**KEY words:** occult breast primary; early detection;  $^{18}\text{F}$ -FDG PET/CT

Nucl Med Rev 2016; 19, Suppl. B: B5–B7

## Background

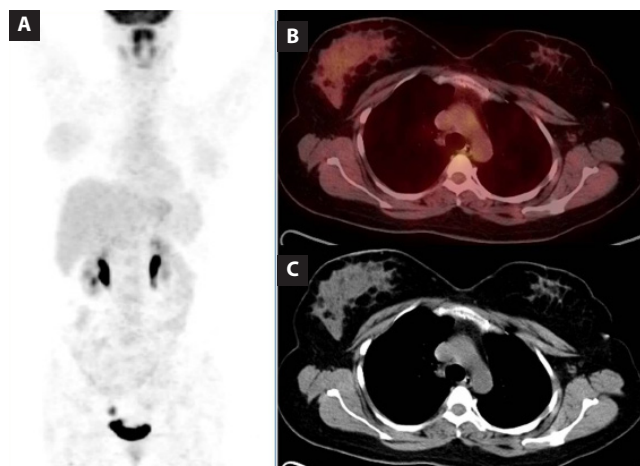
Breast cancer presenting as an isolated axillary lymph node metastasis with no clinical and radiological evidence of primary tumor is uncommon. The incidence is low ranging from 0.3–0.8% of all breast cancer patients [1]. American Joint Committee on Cancer has classified it as T0, N1-2, M0, Stage II–III [1]. Identification of primary site in such cases remains a challenge and has definite impact on patient's survival [1]. Clinical examination, noninvasive and invasive modalities like mammography, breast magnetic resonance imaging (MRI), ultrasound (USG), fine needle aspiration cytology (FNAC) and excision biopsy are used for diagnosis of primary site. The treatment of isolated axillary lymph node metastasis is controversial. Traditionally the choice of treatment for isolated axillary lymph node metastasis is mastectomy and axillary lymph node dissection [1, 2]. But in one third of patients histopathologic examination of the mastectomy specimen may not reveal the primary tumor [3, 4]. Hence there is clearly a need for noninvasive imaging modality for primary site detection

to avoid unnecessary morbidity and for appropriate management. Here we report a case of 30-year-old female patient with isolated right axillary lymph node metastasis and unknown primary site in whom  $^{18}\text{F}$ -Fluorodeoxyglucose (FDG) positron emission tomography (PET)/computed tomography (CT) had an important role in early identification of primary site in right breast.

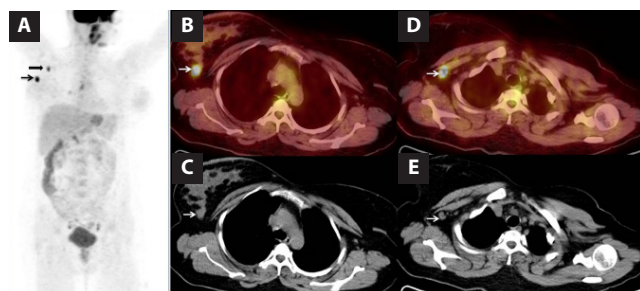
## Case report

A 30-year-old female presented with right axillary lymphadenopathy. FNAC revealed metastatic carcinoma and excisional biopsy showed metastatic adenocarcinoma. She was extensively investigated for primary site. Conventional imaging modalities like mammography, non contrast enhanced CT chest and abdomen, USG neck and abdomen, upper gastrointestinal endoscopy showed no evidence of any primary site.  $^{18}\text{F}$ -FDG PET/CT was advised and primary site could not be localized (Figure 1). Patient underwent chemotherapy and kept on follow up. Mammography, non-contrast enhanced CT of neck, chest and abdomen were done during the follow up and revealed no evidence of primary tumor. After nine months of the initial PET/CT study, she came for follow up  $^{18}\text{F}$ -FDG PET/CT for search of primary site which revealed FDG avid small subcentimeter nodular lesion in the upper outer quadrant of right breast which was suggested as the primary site and active metastatic disease in subcentimeter right subpectoral lymph nodes (Figure 2). She underwent mastectomy and adjuvant chemotherapy. Histopathology from right mastectomy specimen

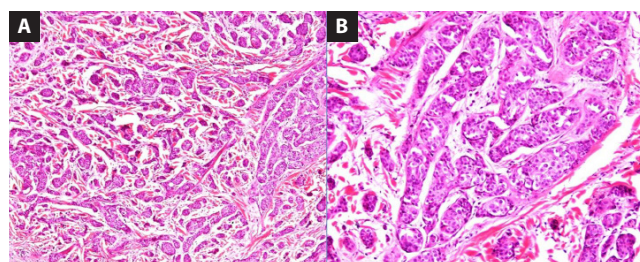
Correspondence to: Dr. Sellam Karunanithi  
MD (AIIMS, New Delhi), FANMB, FEBNM  
Fellow of Asian and European Board of Nuclear Medicine,  
Consultant, Dept. of Nuclear Medicine and PET/CT,  
Malabar Institute of Medical Sciences Ltd. (Aster MIMS),  
Calicut, Kerala, India  
E-mail: drsellam84@yahoo.co.in



**Figure 1A–C.** Maximum intensity projection images of  $^{18}\text{F}$ -FDG PET (A) and axial sections of fused PET/CT and CT images (B and C) did not show any abnormal radiotracer uptake suggestive of primary malignancy or metastases



**Figure 2A–E.** Maximum intensity projection images of  $^{18}\text{F}$ -FDG PET (A) shows abnormal increased FDG uptake in right breast (arrow) and right axillary region (bold arrow). Axial sections of fused FDG PET/CT and CT images (B and C) show a small subcentimeter soft tissue nodular lesion in upper outer quadrant of right breast with increased FDG uptake (arrow) suggestive of primary malignant disease and figures (D and E) show subcentimeter right subpectoral lymph node with increased FDG uptake suggestive of locoregional metastasis



**Figure 3A, B.** Hematoxylin and eosin stained sections from the tumor showing nests and tubules of malignant ductal epithelial cells (100  $\times$ ) (A). Tumor cells show moderate nuclear pleomorphism (200  $\times$ ) consistent with infiltrating ductal carcinoma (B)

showed infiltrating ductal carcinoma (Figure 3) and now she is clinically disease free post treatment.

## Discussion

Breast cancer presenting as isolated axillary lymph node metastasis is an uncommon form of stage II disease and management becomes difficult without identification of primary site. Halsted first described two patients of occult primary breast cancer with axillary nodes involvement [2]. After axillary lymph node metastasis the time of appearance of primary breast tumor varies from 0.5 to 5 years [5]. Diagnostic and treatment protocols are not very well established. The prognosis for occult breast cancer with isolated axillary lymph nodes appears to be better than stage II palpable breast carcinoma. Hence the proper identification of primary site and appropriate management leads to good prognosis. Lymphoma is the most common malignant cause of axillary lymphadenopathy followed by breast carcinoma. More than 90% of patients with axillary lymph node metastasis have primary tumor in breast. Primary tumor from other sites like thyroid, lung, stomach, pancreas, ovary and colon can also metastasize to axillary lymph nodes, but they are less common [6]. In cases of occult breast cancer mammography, breast USG, CT and MRI are routinely used for primary tumor identification. The sensitivity of mammography is limited and varies from 0 to 56% percent for detection of occult primary site in breast. It may be due to dense breast parenchyma causing non visualization of small primary tumors. Contrast-enhanced CT and MRI has important role in primary site detection. But smaller non-enhancing lesions lesser than its resolution may be missed [7]. Morris et al. showed that contrast-enhanced MRI has an identification rate of 75% [8]. Orel et al. reported 86% sensitivity of breast MR imaging in identification of occult breast primary in patients with axillary lymph node metastasis [9].

The role of  $^{18}\text{F}$ -FDG PET/CT has also been evaluated. Takabatake et al. described that  $^{18}\text{F}$ -FDG PET/CT was a helpful option for the diagnosis of primary sites in two cases of occult breast cancer where conventional imaging studies had difficulty in identifying [10]. Owaki et al. reported a case of 0.9 cm diameter primary breast carcinoma detected by FDG PET-CT [11]. It is a well-known fact that  $^{18}\text{F}$ -FDG PET/CT as a functional tumor imaging modality, identifies the early pathological changes before obvious anatomical changes happen. Even though it is not routinely recommended for initial tumor and locoregional staging of breast cancer because of its reduced sensitivity, it is reported to be specific once the primary site is identified in cases of occult breast cancer. Walter et al. reported the sensitivity of MRI and PET-CT as 89 and 63%, and the specificity as 74 and 91%, respectively for primary breast tumor [12].  $^{18}\text{F}$ -FDG PET/CT can completely stage the disease which prognosticates the outcome and may identify other possible sites of primary tumors. In the above case with isolated right axillary lymph node metastasis  $^{18}\text{F}$ -FDG PET/CT contributed significantly in early detection of occult primary in the right breast and it had an important impact on patient management.

## References

1. Xin Wang. Presentation of axillary metastases from occult breast carcinoma. *Chin J Clin Oncol* 2007; 4: 1–5.
2. Halsted W. The results of radical operation for the cure of carcinoma of the breast. *Ann Surg* 1907; 46: 1–19.
3. Baron PL, Moore MP, Kinne DW et al. Occult breast cancer presenting with axillary metastases. Updated management. *Arch Surg* 1990; 125: 210–214.
4. Kyokane T, Akashi-Tanaka S, Matsui T et al. Clinicopathological characteristics of non-palpable breast cancer presenting as an axillary mass. *Breast Cancer* 1995; 2: 105–112.
5. Blanchard DK, Farley DR. Retrospective study of women presenting with axillary metastases from occult breast carcinoma. *World J Surg* 2004; 28: 535–539.
6. Kemeny MM, Rivera DE, Terz JJ, Benfield JR. Occult primary adenocarcinoma with axillary metastases. *Am J Surg* 1986; 152: 43–47.
7. Abbruzzese JL, Abbruzzese MC, Lenzi R et al. Analysis of a diagnostic strategy for patients with suspected tumors of unknown origin. *J Clin Oncol* 1995; 13: 2094–2110.
8. Morris EA, Schwartz LH, Dershaw DD et al. MR imaging of the breast in patients with occult primary breast carcinoma. *Radiology* 1997; 205: 437–440.
9. Orel S, Weinstein S, Schnall M et al. Breast MR imaging in Patients with axillary node metastasis and unknown primary malignancy. *Radiology* 1999; 212: 543–549.
10. Takabatake D, Taira N, Aogi K et al. Two cases of occult breast cancer in which PET-CT was helpful in identifying primary tumors. *Breast Cancer* 2008; 15: 181–184.
11. Owaki T, Kijima Y, Yoshinaka H et al. Ductal carcinoma in-situ of the breast detected by [<sup>18</sup>F] fluorodeoxyglucose positron emission tomography. *Breast Cancer* 2006; 13: 210–213.
12. Walter C, Scheidhauer K, Scharl A et al. Clinical and diagnostic value of preoperative MR mammography and FDG-PET in suspicious breast lesions. *Eur Radiol* 2003; 13: 1651–1656.