

# Myocardial uptake of Tc-99m HDP in a patient with prostate carcinoma

Shivani Chadrawar<sup>1</sup>, Mark George<sup>1</sup>, Mohmoud Al-Akrra<sup>2</sup>, Mark Harber<sup>3</sup>, John Buscombe<sup>1</sup>

<sup>1</sup>Department of Nuclear Medicine, Royal Free Hospital, London, United Kingdom

<sup>2</sup>Department of Urology, Royal Free Hospital, London, United Kingdom

<sup>3</sup>Department of and Nephrology, Royal Free Hospital, London, United Kingdom

[Received 7 IV 2009; Accepted 7 XI 2009]

## Abstract

In this case report we present an unusual appearance of myocardial uptake of Tc-99m HDP in a 59-year-old renal transplant patient who was imaged while looking for metastases from adenocarcinoma of the prostate. Subsequent investigation demonstrated no obvious cause for this appearance, such as myocardial disease or metastatic cancer. The case report, therefore, discusses the possible causes of such an appearance and reviews the literature concerning this phenomenon.

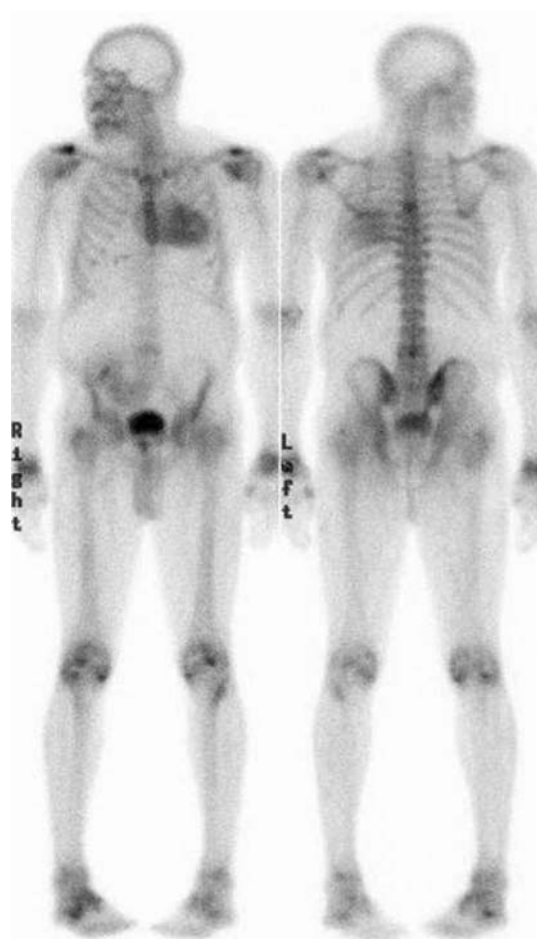
**Key words:** myocardial uptake Tc-99m-HDP, prostate cancer

Nuclear Med Rev 2009; 12, 2: 78–80

## Case report

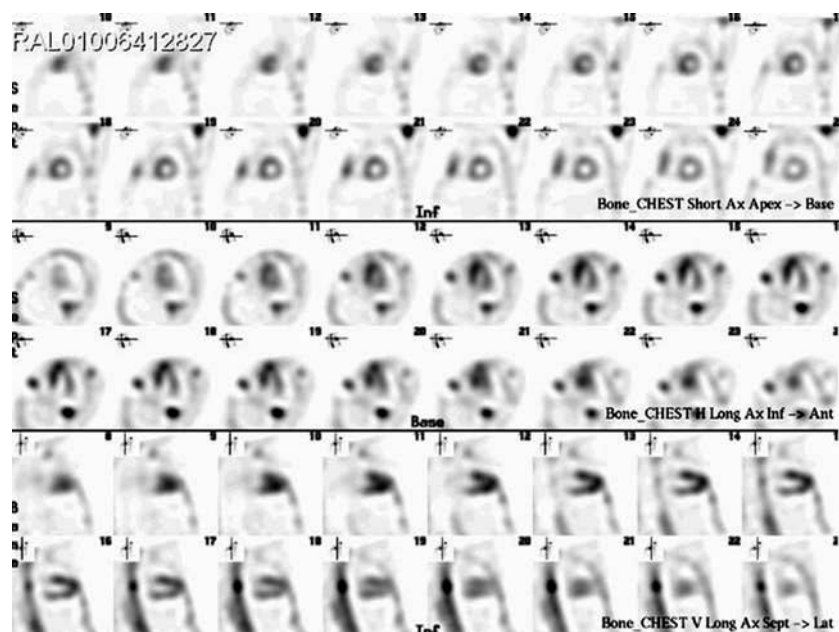
A 59-year-old patient was under investigation for prostate enlargement. Histology confirmed adenocarcinoma of the prostate with Gleason score 3 + 3. Subsequent staging with MRI and bone scintigraphy was undertaken. MRI showed the disease to be confined to the prostate with no capsular involvement. Whole body scintigraphy was performed after administration of 592 MBq of Tc-99m-HDP. This showed uptake in the lower thoracic spine that was subsequently found to be secondary to degenerative disease. However, there was marked diffuse uptake of Tc-99m-HDP through-

out the myocardium (Figure 1). Myocardial uptake was confirmed by SPECT of the thorax (Figure 2). Repeat Bone scintigraphy with Tc-99m HDP repeated after five months did not reveal any change. The patient had previously received a renal transplant which had some mild impairment with biochemical markers showing raised urea and creatinine (11.6 mmol/l and 213  $\mu$ mol/l, respectively). The patient did not need renal replacement therapy. Other biochemical markers, except for the PSA, were unremarkable with a par-



**Figure 1.** Whole body image performed 3 hours after administration of 550 MBq Tc-99m HDP. There is uptake in the 6<sup>th</sup> thoracic vertebrae and both shoulders, confirmed on radiology to be due to degenerative disease; however, there is also uptake in the left lower chest.

Correspondence to: Dr. John R. Buscombe  
Nuclear Medicine, Royal Free Hospital, London NW3 2QG, UK  
Tel: 0044 207 830 2470  
e-mail [j.buscombe@medsch.ucl.ac.uk](mailto:j.buscombe@medsch.ucl.ac.uk)



**Figure 2.** Tomographic images (displayed as transverse, sagittal, and coronal slices) of the left lower chest confirm the uptake is within the myocardium.

athormone (PTH) 26.3 pmol/l, calcium 2.25 mmol/l, corrected calcium 2.21 mmol/l, and PSA 4.3  $\mu$ mol/l. A chest X-ray taken one year prior to the first bone scan did not show any evidence of pulmonary or myocardial calcification. As part of his assessment for renal transplantation, 12 months previously he had had a routine myocardial perfusion scan which confirmed that this patient did not have any objective evidence of ischaemic heart disease. The patient did have a history of hypercholesterolaemia (baseline 7.7 mmol) and was started on 40 mg fluvastatin in 1997 and changed to atorvastatin after 6 months to achieve better control. From 1998 until the time of the bone scan, this patient's atorvastatin was increased from 20 mg to 60 mg daily.

## Discussion

Diffuse Tc-99m-diphosphonate uptake into soft tissues such as the heart muscle has been recognised in the absence of known cardiac or other disorders has been documented and due to deemed 'benign' myocardial uptake [1–3]. Tc-99m-diphosphonate uptake in the myocardium has also been associated with hypercalcaemia, secondary hyperparathyroidism, radiation therapy, adriamycin, and amyloidosis [4–9]. The aetiology has been attributed to hypercalcaemia and altered plasma binding in some of these conditions. Explanations for so-called 'benign' uptake have also included atherosclerosis; however, studies have shown there to be an association with this finding and prostate cancer [10, 11]. This raises the possibility that both conditions may be related to androgen related process. An association has been found between adverse cardiac events following myocardial infarction and raised PSA. It is postulated that Human kallikrein 2 (hK2) and other proteases involved in converting the precursor of PSA (pro-PSA) to PSA may explain this finding [12]. It follows that an intermediate metabolite may alter the form of the radiopharmaceutical such that it would have greater soft tissue bone affinity and accumulate in the myocardium. However, it is unclear why

there is isolated uptake in the myocardium, and whether this is related to a metabolic process or intracellular deposits unique to myocardial cells.

Myocardial uptake of Tc-99m MDP has been reported in a patient with secondary hyperparathyroidism where uptake was demonstrated in the abdominal aorta and iliac arteries in addition to the myocardium [13]. In a case of renal failure, progressive uptake of the radiotracer was noted in the myocardium, kidneys, stomach, lungs, and skeletal muscles, which was in keeping with CT evidence of microcalcification [14]. Similarly, systemic amyloidosis is also found in several visceral organs [15]. Isolated uptake of Tc-99m diphosphonates in the myocardium is therefore not in keeping with the pattern of uptake in secondary hyperparathyroidism or amyloidosis.

Al-Nahhas and colleagues [11] reported a 2.3% prevalence of Tc-99m HDP or MDP myocardial uptake of all bone scintigrams performed in their department over a two-year period. The experience in this institution points to the fact that myocardial uptake in bone scintigraphy is far less frequent, with this being the only case seen in the last ten years, during which time over 1000 patients with prostate cancer have been imaged. Furthermore, Al-Nahhas et al. demonstrated the highest rate of this observation in male patients over the age of 80, of which 76% also had prostate cancer. Conversely, 12.5% of all patients with prostate cancer undergoing bone scintigraphy were found to have myocardial uptake. Interestingly, it was noted that 2.5% of patients with malignancies other than prostate cancer also demonstrated myocardial uptake but only in a cohort over 80 years of age.

An alternative theory may be related to the use of statins. The patient in this case had been receiving statin therapy for over a decade. Statins are associated with oxidation injury demonstrated by in vivo elevation of isoprostanes [16]. Studies have demonstrated the uptake of Tc-99 diphosphonates in skeletal muscle due to myositis/rhabdomyolysis secondary to statins; however, this effect has not been demonstrated on the myocardium.

## Conclusion

Myocardial uptake of Tc-99m HDP is rarer than previously described and has an association with prostate cancer. Further investigation of this observation may reveal the biochemical explanation for the isolated myocardial uptake of the radiopharmaceutical and the link with prostate cancer.

## References

1. AL-Nahhas AM, Jinnouchi S et al. Clinical significance of technetium-99m methylene diphosphonate myocardial uptake: association with carcinoma of the prostate. *Eur J Nucl Med* 1995; 22: 148–153.
2. Perez LA, Hayt DB, Freeman LM. Localization of myocardial disorders other than infarction with 99mTc-labelled phosphate agents. *J Nucl Med* 1976; 17: 241–246.
3. Prasquire R, Taradash MR, Botvinick EH et al. The specificity of the diffuse pattern of cardiac uptake in myocardial infarction imaging with technetium-99m stannous pyrophosphate. *Circulation* 1977; 55: 61–66.
4. Kida T, Hujita Y, Sasaki M, Inoue J. Myocardial and vascular uptake of a bone tracer associated with secondary hyperparathyroidism. *Eur J Nucl Med*. 1986; 12: 151–154.
5. Wistow BW, McAfee JG. Renal uptake of Tc-MDP after radiation therapy. *J Nucl Med*. 1979; 29: 32–34.
6. Chacko AK, Gordon DH, Bennet JM et al. Myocardial imaging with Tc-99m pyrophosphate in patients on adriamycin treatment for neoplasia. *J Nucl Med* 1977; 18: 680–683.
7. Soin JS, Cox JD, Youker JE et al. Cardiac localization of 99mTc-(Sn)-pyrophosphate following irradiation of the chest. *Radiology* 1977; 124: 165–168.
8. Atldns HL, Oster ZH. Myocardial uptake of a bone tracer associated with hypercalcemia. *Clin Nucl Med* 1984; 9: 613–615.
9. Hongo M, Yamada H, Okubo S et al. Cardiac involvement in systemic amyloidosis: myocardial scintigraphic evaluation. *J Cardiogr* 1985; 15: 163–180.
10. Jones A, Keeling D. Benign myocardial uptake of hydroxymethylene diphosphonate. *Nucl Med Commun* 1994; 15: 21–23.
11. Al-Nahhas AM, McCready VR. The role of radionuclide studies in breast cancer. *Nucl Med Commun* 1993; 14: 192–196.
12. Patane S, Marte F. Prostate specific antigen kallikrein and acute myocardial infarction: Where we are. Where are we going. *Int J Cardiol* 2009. [Epub ahead of print]
13. Kida T, Hujita Y, Sasaki M, Inoue J. Myocardial and vascular uptake of a bone tracer associated with secondary hyperparathyroidism. *Eur J Nucl Med* 1986; 12: 151–154.
14. Low, Hicks. Progressive soft tissue uptake of Tc-99m MDP reflecting metastatic microcalcification. *Clin Nucl Med* 1992; 17: 658–662.
15. Janssen S, van Rijswijk MH, Piers DA et al. Soft-tissue uptake of 99mTc-diphosphonate in systemic AL amyloidosis. *Eur J Nucl Med* 1984; 9: 538–541.
16. Sinzinger H, Lupattelli G, Chehne F. Increased lipid peroxidation in a patient with CK elevation and muscle pain during statin therapy. *Atherosclerosis* 2000; 153: 255–256.