

Early brain perfusion improvement after ventriculoperitoneal shunt surgery in patients with idiopathic normal pressure hydrocephalus evaluated by ^{99m}Tc-HMPAO SPECT — preliminary report

Anna Nocuń¹, Anna Mosiewicz², Robert Kaczmarczyk², Teresa Kazalska³, Elżbieta Czekajska-Chehab⁴, Beata Chrapko¹, Tomasz Trojanowski²

¹Department of Nuclear Medicine, Medical University of Lublin, Poland

²Department of Neurosurgery and Paediatric Neurosurgery, Medical University of Lublin, Poland

³Department of Neurology Medical University of Lublin, Poland

⁴ Department of Medical Radiology with Laboratory for Telemedicine, Medical University of Lublin, Poland

[Received 18 II 2015; Accepted 3 VII 2015]

Abstract

BACKGROUND: Idiopathic normal pressure hydrocephalus (iNPH) is a clinical syndrome that consists of the triad: gait disturbance, mental deterioration and urinary incontinence associated with normal cerebrospinal fluid pressure (CSF), without pre-existing abnormalities. The most popular treatment option is surgical implantation of a shunt. Brain perfusion increase occurring months or years after successful shunt surgery is well described in the literature. Early improvement of perfusion is not well documented. Therefore, the objective of the present study was to determine patterns of brain perfusion changes 3–6 days after the ventriculoperitoneal shunting in patients with iNPH by using ^{99m}Tc-HMPAO SPECT.

MATERIAL AND METHODS: Sixteen patients with iNPH (9 women, 7 men, mean age 64.1 ± 12.7 years) who underwent ventriculoperitoneal shunt surgery were included into the study group. Indications for implanting a shunt were based on clinical history, neuroimaging and CSF dynamic studies with an infusion test. Brain perfusion SPECT was performed 1–2 days before and 3–6 days after the surgical treatment. For comparison of perfusion before and after the surgery SPECT scans were assessed visually and semiquantitatively with voxel based analysis.

RESULTS: No side effects were observed after the surgery. Brain perfusion improvement after shunting was observed in 10 patients (62.5%). Patterns of perfusion changes varied between patients, with combinations of different bilateral and lateralized brain regions involved. Perfusion increased in the whole brain (3 patients), in the right cerebral hemisphere (1 patient) or in the separate cerebral regions (6 patients): frontal, parietal, temporal, cerebellum, cingulate gyrus. Perfusion improvement was predominantly observed in the frontal lobes: right frontal (3 cases, 18.8%), left frontal (3 cases, 18.8%).

CONCLUSIONS: Cerebral perfusion is recovered promptly after ventriculoperitoneal shunt surgery in about 60% of patients with iNPH. This improvement may be global or regional in different cerebral areas with prevalence of the frontal lobes.

KEY words: idiopathic normal pressure hydrocephalus, ventriculoperitoneal shunt, brain perfusion, ^{99m}Tc-HMPAO SPECT

Nuclear Med Rev 2015; 18, 2: 84–88

Background

Normal pressure hydrocephalus (NPH) was first described by Adams et al. [1] as a clinical syndrome that consisted of the triad: gait disturbance, mental deterioration and urinary incontinence, in association with normal cerebrospinal fluid (CSF) pressure. Idiopathic (iNPH) also known as Hakim-Adams syndrome is defined as NPH without pre-existing conditions like tumor, head trauma, meningitis, subarachnoid or cerebral hemorrhage. Anatomical

Correspondence to: Anna Nocuń, MD, PhD
Department of Nuclear Medicine
Medical University of Lublin
Jaczewskiego 8 St., 20-954 Lublin, Poland
Tel/fax: + 48 81 72 44 339
E-mail: ampolak@o2.pl

Table 1. Clinical characteristics of the studied group

No	Age	Sex	Disease duration	The triad of symptoms			Neurological signs and symptoms in addition to the triad	
				Dementia	Gait	Urinary incontinence		
1	77	M	1,5 m	+	+		Dizziness, Romberg sign	
2	68	F	2 y	+	+	+		Increased muscle tension in lower limbs
3	34	M	2 y	+				Headache, increased muscle tension in lower limbs
4	63	F	1 y	+	+			Headache, dizziness, increased muscle tension
5	54	F	10 y	+	+			Headache, dizziness, loss of consciousness, leg stiffness, Babinski sign on the right side
6	84	M	1 y	+	+			Increased muscle tension
7	73	M	3 m	+	+	+		
8	47	F	10 y	+				Headache, loss of consciousness, bilateral Babinski sign, Romberg sign
9	63	M	3 y	+	+	+		Tetraparesis, Romberg sign
10	60	F	4 y	+	+	+		Increased muscle tension in lower limbs
11	76	F	1 m	+	+	+		Loss of consciousness, bedridden
12	68	F	1 y	+				Headache
13	61	F	6 m	+				Headache, dizziness
14	78	M	6 m	+	+	+		Increased muscle tension in lower limbs, Romberg sign
15	55	M	24 m	+	+	+		Increased muscle tension in lower limbs, Romberg sign, bedridden
16	64	F	1 y	+	+	+		Headache, increased muscle tension in lower limbs, Romberg sign

imaging displays the structural changes: enlarged ventricle systems and Sylvian fissures, tight medial and high convexity sulci [2]. This image is supplemented by the functional techniques like single photon emission computed tomography (SPECT) or positron emission tomography (PET) allowing for quantification of the cerebral blood flow and metabolism. Despite wide capabilities of those excellent imaging modalities, the iNPH etiology remains unknown [3].

The most popular treatment option is surgical implantation of a shunt that chains CSF from the lateral ventricle of the brain to the peritoneal cavity, where it is absorbed to the circulation or directly into the right heart vestibule through the jugular vein. When patients are properly selected, shunt implantation is a safe and effective management of iNPH with a prolonged positive outcome. Recently perfected types of shunts with valve opening pressure adjustments have improved precision of shunting procedures [4]. Results from studies published in the last 5 years show 82% cases of improvement of symptoms following shunt insertion and mortality of 0.2% [5]. Brain perfusion increase after successful shunt iNPH surgery, occurring months after the procedure, was well described in the literature [6–8]. Early improvement of perfusion is not well documented, however, the issue of how quickly functional changes occur after shunting is very interesting as it may shed the light on the nature of pathophysiological mechanism of this not well-known syndrome. Therefore, the objective of the present study was to determine patterns of brain perfusion changes 3–6 days after the ventriculoperitoneal shunting in patients with iNPH by using ^{99m}Tc-HMPAO SPECT with automatic voxel based analysis.

Material and methods

Sixteen patients with iNPH (9 women, 7 men, mean age 64.1 ± 12.7 years) were included into the study group. The patients underwent ventriculoperitoneal shunt surgery in the Department of Neurosurgery and Pediatric Neurosurgery, Medical Univer-

sity of Lublin, Poland. Indications for implanting a shunt were based on clinical history, neuroimaging with computed tomography (CT) or magnetic resonance imaging (MRI) and CSF dynamic studies with an infusion test. Clinical characteristics of the studied group are presented in Table 1. The interval between onset of the disease and the surgery was 1 month to 10 years (mean time 27.7 months ± 37.3). Neurological examination was performed one day before the surgery. The full clinical triad of symptoms was present in 8 patients, two symptoms (dementia + gait disturbances) in 4 patients, only one symptom (dementia) in 4 patients. The history of subarachnoid hemorrhage, cerebral hemorrhage, head trauma, meningitis or cerebrovascular disease were exclusion criteria in the studied group. Ventricular dilatation (Evans index ≥ 0.30) was demonstrated in all participants (Table 2). CSF outflow resistance (Rcsf) was determined with lumbar infusion test which measures absorptive capacity of CSF by administration of additional volume of fluid to the subarachnoid space. An abnormal rise of CSF pressure indicates that absorption capacity of CSF is reduced. Rcsf was calculated using the difference between the final CSF pressure after establishing the plateau of CSF pressure during infusion of additional fluid volume and the initial pressure and the velocity of the fluid infusion. Value of Rcsf higher than 13 mm Hg/ml/min is described as abnormal. The test was not performed in 3 patients due to the degenerative disease.

The study protocol was approved by the local ethics committee and informed consent was obtained from all the patients.

Surgical method

The shunt with valve system connecting the lateral ventricle of the brain and the peritoneal cavity was implanted under general anesthesia.

Data acquisition

Brain perfusion SPECT was performed 1–2 days before and 3–6 days after surgical treatment using ^{99m}Tc-hexamethyl propy-

Table 2. CSF dynamics and Evans ratio in examined patients

No	Age	Sex	CSF pressure measured during ventricular puncture in cm H ₂ O	CSF outflow resistance [mm Hg/min/ml]	Evans ratio
1	77	M	10	11	0.43
2	68	F	10	Not performed	0.42
3	34	M	15	17.6	0.52
4	63	F	15	Not performed	0.49
5	54	F	11	10.2	0.39
6	84	M	8	14.2	0.42
7	73	M	8	13.9	0.46
8	47	F	10	13.4	0.4
9	63	M	14	11	0.41
10	60	F	13	11.5	0.4
11	76	F	12	18.07	3.93
12	68	F	12	14.97	0.36
13	61	F	12	12	0.38
14	78	M	12	15.5	0.37
15	55	M	13	Not performed	0.39
16	64	F	14	14	0.53
Mean			11.81 (±2.20)	13.64	0.64

lene amine oxime (HMPAO) Radiopharmaceutical was injected intravenously in a dose of 740 MBq in a quiet environment to the patients in the supine position, with their eyes open. SPECT acquisition was carried out 20–30 min after injection, using a rotating, double-head, large field of view gamma camera (Elsint, Haifa, Israel), equipped with low-energy, high-resolution collimators. The data were collected in a 128 × 128 matrix through 360° rotation at 3° intervals for 25 s per view. Reconstruction of transaxial slices was performed by filtered back projection (Metz filter power, 3.00; full width at half maximum, 10 mm) with subsequent attenuation correction using the Chang method (attenuation coefficient 0.11).

Data analysis

For comparison of perfusion before and after the surgery SPECT scans were assessed visually and semiquantitatively with Brain SPECT Quantification software (Compart Medical Systems, Poland). The method which was described previously [9, 10] consisted of the four major steps:

- step 1. Both basal and control studies were interpolated to the same resolution (2 × 2 × 2 mm) as the anatomically standardized brain template (norm), provided by the manufacturer with the software;
- step 2. The software automatically matched individual SPECT with the template. Such a transformation process, defined as spatial normalization, consisted of scaling, shifting and rotation. It was associated with count normalization to the whole brain;
- step 3. Voxel-based analysis was carried out. The relative difference (RD) was computed in each voxel, using the formula: $RD = \{(B - A) / [(B + A) / 2]\} \times 100$, where B and A represented counts in the postoperative and baseline studies respectively;
- step 4. Cluster analysis was performed for selection of voxels with significant change of perfusion after surgery. Abnormalities were discerned by a 3D region-growing algorithm which compared voxels in the image to the corresponding limits (cut-off values). Cut-off values for significant perfusion change between basal and control were set as follows: RD

higher than 10% in a cluster volume (CV) greater than 10 ml. The software selects and displays clusters of voxels that fulfill these criteria. The cut-off percentage value of RD may be set by the user in a program configuration as a positive or negative number to find perfusion improvement or deterioration. Example of cluster analysis is shown on Figure 1.

Results

No side effects were observed after the surgery. Brain perfusion improvement after shunting was observed in 10 patients (62.5%). Patterns of perfusion changes varied between patients, with combinations of different bilateral and lateralized brain regions involved. The overview of these regions is presented in Tables 3 and 4. Perfusion increased in the whole brain (3 patients, 18.8%), in the right cerebral hemisphere (1 patient, 6%) or in the discrete cerebral regions (6 patients, 37.5%): frontal, parietal, temporal, cerebellum, cingulate gyrus. Perfusion improvement was predominantly observed in the frontal lobes: right frontal (3 cases, 18.8%) and left frontal (3 cases, 18.8%).

Discussion

The improvement of cerebral perfusion [6–8, 11] and increased cerebral metabolism [12, 13] several months or years after shunting surgery in NPH patients are well documented in the literature. The published data describing these changes within days following surgical procedure are very scarce. In the present study perfusion improvement was observed 3–6 days after shunting. This finding is in agreement with the recently reported increase of ¹⁸F-FDG utilization in the brain 7 days after the surgery [14, 15] and ¹⁵O-H₂O perfusion improvement in 7–10 days [16]. Using ¹⁸F-FDG PET, Calcagni et al. found in the group of 11 iNPH patients that the global [15] and regional [14] glucose metabolism significantly increased one week after shunting, which means that the neuronal cells surrounding the enlarged ventricles have preserved viability.

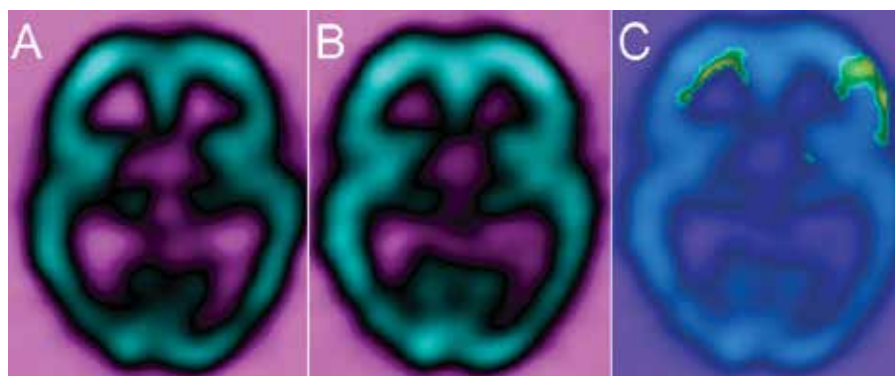


Figure 1A–C. An example of cluster analysis: **A.** Baseline SPECT; **B.** Postoperative SPECT; **C.** Postoperative perfusion increase in the frontal lobes. Yellow color represents clusters of selected voxels with relative difference between two studies (RD) > 10% in a cluster volume > 10 ml, RD in each voxel = $\{(B - A)/[(B + A)/2]\} \times 100$, where B and A represent counts in the postoperative and baseline studies respectively.

Table 3. Brain regions of perfusion improvement after surgery

No	Age	Sex	Regions of perfusion improvement
1	77	M	Whole brain
2	68	F	Whole brain
3	34	M	Whole brain
4	63	F	Right cerebral hemisphere
5	54	F	Bilateral frontal, left cerebellum
6	84	M	Left frontal, left parietal
7	73	M	Right cingulate gyrus
8	47	F	Bilateral frontal
9	63	M	Right frontal
10	60	F	Right temporal
11	76	F	No change
12	68	F	No change
13	61	F	No change
14	78	M	No change
14	55	M	No change
16	64	F	No change

Moreover, the lack of any significant reduction in the ventricular size at that time confirms that functional changes may occur independently of the morphological ones. According to the authors, since the perfusion and metabolism change so quickly, they seem to be significant disease mechanism responsible for the disturbance of CSF dynamics and brain dysfunction, whereas a ventricular enlargement may be only an “epiphenomenon” of the CSF disorder. On the level of perfusion, the present findings corroborate this prompt functional response of the brain parenchyma to the restoration of the CSF circulation by ventriculoperitoneal shunt. It probably makes the ground for the recovery of neuronal function expressed by the clinical improvement. Several hypotheses have been postulated to explain the perfusion decrease in iNPH and its improvement after surgery. The significance of venous flow is stressed by some authors: the presence of abnormal intracranial venous flow [17], retrograde jugular venous flow [18] and elevated cortical vein pressure [19] in NPH. There is also a new proposal to clarify the pathogenesis of iNPH, in which CSF is mainly absorbed in the capillaries in all the central nervous system [20].

Table 4. Number of patients with perfusion improvement in brain regions after the surgery

Brain region	Lateralization	
	Right	Left
Whole brain	3	
Frontal	3	3
Cerebral hemisphere	1	
Temporal	1	
Parietal		1
Cerebellum		1
Cingulate gyrus	1	

The present study revealed different patterns of perfusion improvement: in the whole brain, in the cerebral hemisphere or in the bilateral and lateralized brain regions. The isolated regions of significant perfusion recovery were observed predominantly in the frontal lobes laterally or bilaterally. These patterns may reflect heterogeneity of the NPH condition described by Waldemar et al [21] who, almost 20 years ago, suggested that CBF abnormalities resulted from different stages of the disease or different underlying degenerative disorders. The finding of preferential frontal lobes postsurgical improvement of perfusion with addition of other lobes involvement is consistent with previous observations. Mataro et al. [6] found increased perfusion after surgery in the left prefrontal dorsolateral areas, right frontal premotor area, right medial prefrontal region, right frontal white matter area, and right basal ganglia (lenticular nucleus, putamen, and globus pallidus). The areas most related to clinical improvement were Brodmann’s area 32 and the frontal part of the left lobule of Reil insula. Murakami et al. [7] noted clinical improvement in 14 out of 24 examined patients with iNPH. Ten to 36 months after the treatment these 14 responders demonstrated significant regional cerebral blood flow (rCBF) increase in the frontal lobe base and the cingulate gyrus in both cerebral hemispheres. The regional blood flow in the cerebellar hemispheres also increased after shunting, according to the authors possibly due to crossed cerebellar diaschisis. The same mechanism may explain cerebellar perfusion improvement observed in one of the present cases.

Calcagni et al. [14] reported significant increase of ^{18}F -FDG metabolism in all cerebral regions with the lowest values in the

pons and cerebellum in the clinically improved iNPH patients. According to Klinge et al. [16], patients with clinical improvement after the surgery showed significant increase in perfusion represented by $^{15}\text{O}\text{-H}_2\text{O}$ uptake in the superior frontal areas.

The improvement in cerebral perfusion was also shown in pediatric hydrocephalus [8]. $^{99\text{m}}\text{Tc}\text{-ECD}$ SPECT revealed perfusion increase in 14 out of 17 children (82.3%) one month after ventriculoperitoneal shunt placement in frontal, parietal and occipital lobes. All 17 children presented clinical improvement after the surgery.

The method of comparison between basal and control SPECT examinations used in the present study is very precise. Spatial normalization performed automatically by a computer program with voxel by voxel analysis allows for the comparison of exactly the same anatomical structures and displays even very subtle changes of perfusion. Statistical parametric mapping (SPM) employed in previous reports [6, 16, 22] is also automatic, operator-independent and does not require prior selection of regions of interest. However these two approaches are different. The software used in the present study enables evaluation of perfusion changes on the patient-by-patient basis, therefore it was possible to assess the pattern of improvement in each patient and also to evaluate the number of cases with improved perfusion (62.5%), not available from SPM approach. This number is lower than 82% of the cases of clinical improvement following shunt insertion cited in the literature [5], which suggests that perfusion increase does not stop 3–6 days after the treatment.

The limitation of the present study is a small number of included patients. The second limitation is that identification of baseline perfusion was not performed; however, automatic transformation of individual SPECT with the template and its comparison with the normal database in brains with hydrocephalic features is the subject to a large spatial error. Another drawback of the present study is a lack of correlation between SPECT data and clinical scales, but in our opinion, the clinical status of the patients within 3–6 days after the surgery is still influenced by the invasive procedure and therefore may not objectively represent benefits of the treatment.

Conclusions

Cerebral perfusion is recovered promptly after ventriculoperitoneal shunt surgery in about 60% of patients with iNPH. This improvement may be global or regional in different cerebral areas with prevalence of the frontal lobes.

References

- Adams RD, Fisher CM, Hakim S, Ojemann RG, Sweet WH. Symptomatic occult hydrocephalus with "normal" cerebrospinal fluid pressure. *N Engl J Med* 1965; 273: 117–126.
- Hashimoto M, Ishikawa M, Mori E, Kuwana N. Diagnosis of idiopathic normal pressure hydrocephalus is supported by MRI-based scheme: a prospective cohort study. *Cerebrospinal Fluid Res* 2010; 7: 18. doi: 10.1186/1743-8454-7-18.
- Mori E, Ishikawa M, Kato T et al; Japanese Society of Normal Pressure Hydrocephalus. Guidelines for management of idiopathic normal pressure hydrocephalus: second edition. *Neurol Med Chir (Tokyo)* 2012; 52: 775–809.
- Ghosh S, Lippa C. Diagnosis and prognosis in idiopathic normal pressure hydrocephalus. *Am J Alzheimers Dis Other Dement* 2014; 29: 583–589. doi: 10.1177/1533317514523485.
- Toma AK, Papadopoulos MC, Stapleton S, Kitchen ND, Watkins LD. Systematic review of the outcome of shunt surgery in idiopathic normal-pressure hydrocephalus. *Acta Neurochir (Wien)* 2013;155:1977–1980. doi: 10.1007/s00701-013-1835-5.
- Mataró M, Poca MA, Salgado-Pineda P et al. Postsurgical cerebral perfusion changes in idiopathic normal pressure hydrocephalus: a statistical parametric mapping study of SPECT images. *J Nucl Med* 2003; 44: 1884–1889.
- Murakami M, Hirata Y, Kuratsu JI. Predictive assessment of shunt effectiveness in patients with idiopathic normal pressure hydrocephalus by determining regional cerebral blood flow on 3D stereotactic surface projections. *Acta Neurochir (Wien)* 2007; 149: 991–997.
- Nayak PK, Agrawal D, Gowda NK, Bal CS, Mahapatra AK. Does cerebral perfusion improve following CSF diversion in pediatric hydrocephalus? A prospective study using $^{99\text{m}}\text{Tc}$ ECD single photon emission computed tomography. *Pediatr Neurosurg* 2005; 41: 117–121.
- Nocuń A, Wilczyński M, Wroński J, Chrapko B. Usefulness of $^{99\text{m}}\text{Tc}\text{-ECD}$ brain SPECT with voxel-based analysis in evaluation of perfusion changes early after carotid endarterectomy. *Med Sci Monit* 2011; 17: 297–303.
- Nocuń A, Szajner M, Obszańska K et al. Changes of brain perfusion after endovascular embolization of intracranial arteriovenous malformations visualized by $^{99\text{m}}\text{Tc}\text{-ECD}$ SPECT. *Nucl Med Commun* 2008; 29: 1073–1080. doi: 10.1097/MNM.0b013e32831392eb.
- Shih WJ, Tasdemiroglu E. Reversible hypoperfusion of the cerebral cortex in normal-pressure hydrocephalus on technetium- $^{99\text{m}}$ -HMPAO brain SPECT images after shunt operation. *J Nucl Med* 1995; 36: 470–473.
- del Mar Matarín M, Pueyo R, Poca MA, Falcón C et al. Post-surgical changes in brain metabolism detected by magnetic resonance spectroscopy in normal pressure hydrocephalus: results of a pilot study. *J Neurol Neurosurg Psychiatry* 2007; 78: 760–763.
- Miyamoto J, Tatsuzawa K, Inoue Y, Imahori Y, Mineura K. Oxygen metabolism changes in patients with idiopathic normal pressure hydrocephalus before and after shunting operation. *Acta Neurol Scand* 2007; 116: 137–143.
- Calcagni ML, Taralli S, Mangiola A et al. Regional cerebral metabolic rate of glucose evaluation and clinical assessment in patients with idiopathic normal-pressure hydrocephalus before and after ventricular shunt placement: a prospective analysis. *Clin Nucl Med* 2013; 38: 426–431. doi: 10.1097/RLU.0b013e31828e949b.
- Calcagni ML, Lavalle M, Mangiola A et al. Early evaluation of cerebral metabolic rate of glucose (CMRglu) with $^{18}\text{F}\text{-FDG}$ PET/CT and clinical assessment in idiopathic normal pressure hydrocephalus (iNPH) patients before and after ventricular shunt placement: preliminary experience. *Eur J Nucl Med Mol Imaging* 2012; 39: 236–241. doi: 10.1007/s00259-011-1950-6.
- Klinge PM, Brooks DJ, Samii A et al. Correlates of local cerebral blood flow (CBF) in normal pressure hydrocephalus patients before and after shunting — a retrospective analysis of $^{15}\text{O}\text{H}_2\text{O}$ PET-CBF studies in 65 patients. *Clin Neurol Neurosurg* 2008; 110: 369–375. doi: 10.1016/j.clineuro.2007.12.019.
- Kuriyama N, Tokuda T, Yamada K et al. Flow velocity of the superior sagittal sinus is reduced in patients with idiopathic normal pressure hydrocephalus. *J Neuroimaging* 2011; 21: 365–369. doi: 10.1111/j.1552-6569.2011.00592.x.
- Kuriyama N, Tokuda T, Miyamoto J et al. Retrograde jugular flow associated with idiopathic normal pressure hydrocephalus. *Ann Neurol* 2008; 64: 217–221. doi: 10.1002/ana.21410.
- Bateman GA. The reversibility of reduced cortical vein compliance in normal-pressure hydrocephalus following shunt insertion. *Neuroradiology* 2003; 45: 65–70.
- Ishikawa M. Idiopathic normal pressure hydrocephalus — overviews and pathogenesis. *Brain Nerve* 2008; 60: 211–217.
- Waldemar G, Schmidt JF, Delecluse F et al. High resolution SPECT with $^{99\text{m}}\text{Tc}\text{-d,l-HMPAO}$ in normal pressure hydrocephalus before and after shunt operation. *J Neurol Neurosurg Psychiatry* 1993; 56: 655–664.
- Yoon B, Yang DW, Shim YS et al. Voxel-based analysis of $^{99\text{m}}\text{Tc}$ ECD brain perfusion SPECT in patients with normal pressure hydrocephalus. *Appl Radiat Isot* 2009; 67: 1377–1381. doi: 10.1016/j.apradiso.2009.02.080.