

Extraosseous myocardial uptake incidentally detected during bone scan: report of three cases and a systematic literature review of extraosseous uptake

Federico Caobelli¹, Barbara Paghera², Claudio Pizzocaro¹,
Ugo Paolo Guerra¹

¹Fondazione Poliambulanza, Nuclear Medicine Department, Italy
²Spedali Civili Brescia, Italy

[Received 16 XI 2012; Accepted 10 VI 2013]

Abstract

Bone scintigraphy is widely considered as an important technique able to investigate various pathological conditions of the skeletal system. Many unexpected extraosseous uptakes have been reported in literature. We present here three cases of unexpected ^{99m}Tc-oxidronate (HDP) myocardial extraosseous uptakes in patients undergoing bone scan for staging purposes. In particular, we present the first reported case of a myocardial uptake in a patient with IgM-related amyloidosis. Subsequently, we perform a review of the existing literature about extraosseous uptakes.

KEY words: bone scan, extraosseous uptake, myocardial uptake, amyloidosis

Nuclear Med Rev 2013; 16, 2: 82–87

Introduction

Bone scintigraphy is widely considered as an important technique able to investigate various pathological conditions of the skeletal system and its use is embedded in national and international guidelines. Many unexpected extraosseous uptakes have been reported in literature: although several causes can be addressed, still the majority of cases do not recognize a clear pathological entity [1].

Correspondence to: Federico Caobelli
Fondazione Poliambulanza, Nuclear Medicine Department, Italy
E-mail: fedefournier@libero.it

This phenomenon can be due to a huge variety of pathophysiological mechanisms, such as an alteration in calcium metabolism, as it often happens in many systemic diseases, extracellular fluid expansion and enhanced regional vascularity and permeability [2, 3]; lung has been reported to be the most frequently site, followed by myocardium, chest wall, spleen, lymph nodes, kidney, stomach, retroperitoneum, adrenal gland, and pelvic cavity [4–9].

We present here three cases of unexpected ^{99m}Tc-oxidronate (HDP) uptakes in patients undergoing bone scan for staging purposes; subsequently, we perform a review of the existing literature about extraosseous uptakes.

Cases description

Case 1

A 75 year old man came to our observation in order to perform a bone scan for staging purposes. The patient has been diagnosed with prostate cancer two months before. Three hours after administering 850 MBq ^{99m}Tc-HDP, we performed a total body scan. No clear metastatic lesions could be found, but there was an evidence of an unexpected myocardial uptake (Fig. 1). No possible underlying causes could be detected, and the patient underwent a second bone scan two days later. The myocardial uptake was still present and an intense uptake involving the left upper extremity also could be detected (Fig. 2), not present on the first examination. The patient denied physical exercise the day before examination as well as receiving intravenous or intra-arterial drugs. Standard routine blood test were unremarkable, while D-dimer was not available. An extravenous administration was excluded, since the injection site was on the right arm. Likewise, a possible contamination was excluded. The possible cause of these extraosseous uptakes remained unexplained.

Case 2

A 65 year-old woman came to our observation for staging purposes after being diagnosed with breast cancer. Four hours after administering 780 MBq ^{99m}Tc-HDP, a total body bone scan was per-

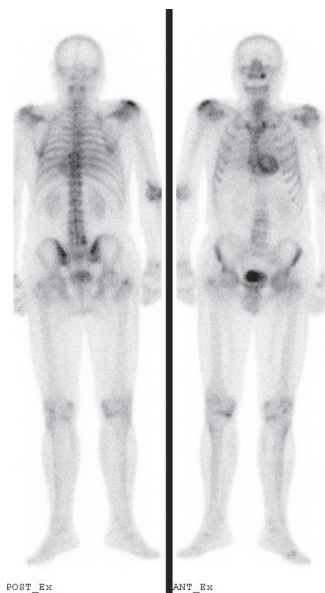


Figure 1. Bone scan (anterior and posterior view) in the patient described in case 1. There is an evidence of a myocardial uptake

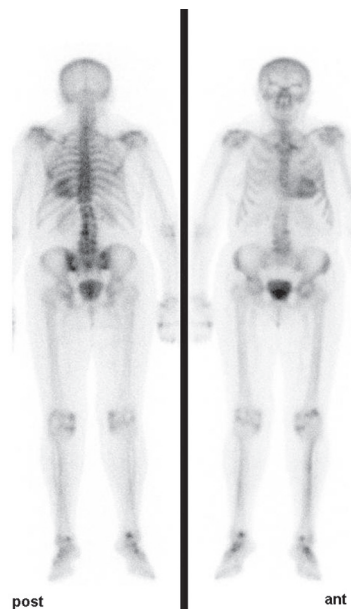


Figure 3. Bone scan (anterior and posterior view) in the patient described in case 2. There is an evidence of a myocardial uptake

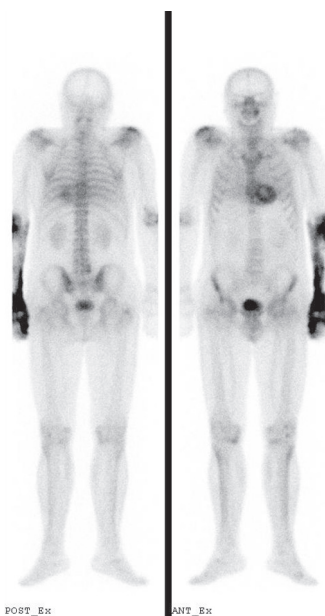


Figure 2. The same patient of Figure 1 two days later: the myocardial uptake is still present, while there is a new large uptake on the left upper extremity

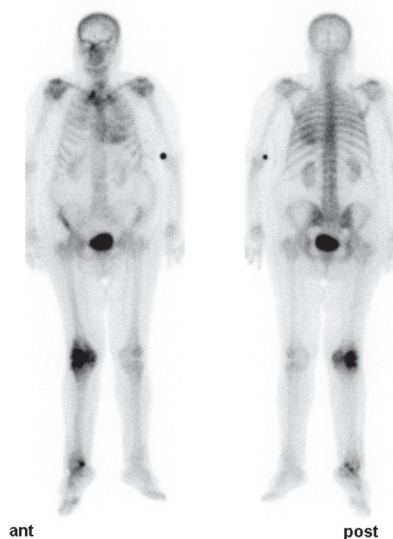


Figure 4. Bone scan (anterior and posterior view) in the patient described in case 3. There is an evidence of a myocardial uptake. The patient was later diagnosed with IgM-related amyloidosis

formed. The patient had no history of other diseases and she was on well-being at the observation. No symptoms were reported.

There was an evidence of small uptakes on the pelvis and the lumbar spine, probably related to arthrosis, and an extraosseous myocardial uptake (Fig. 3). The patient had no history of cardiac diseases, but she was later investigated and diagnosed with amyloidosis.

Case 3

A 78 year-old woman came to our observation because of suspicion of a metastatic lesion located on the right knee. Three hours after administering 568 MBq ^{99m}Tc -HDP, the patient underwent a total body bone scan, revealing an intense uptake on

the right knee. A myocardial uptake was also evident (Fig. 4). The clinical history was investigated, and we found that the patient has been diagnosed with Waldenstrom disease two years before, and suffered from IgM-related amyloidosis. The patient was not on specific therapy at the time of our observation. Right knee pain was the only symptom reported by the patient.

Discussion

Extraosseous uptakes of ^{99m}Tc -labelled phosphates have been reported in many papers, although they represent a relatively rare clinical entity (Table 1).

Table 1. Conditions associated to extrasosseous ^{99m}Tc-phosphates uptake during a bone scan and the most frequent localizations

Alteration		More frequent localizations	
Neoplasia	Prostate cancer	Myocardium	
	Parathyroid adenoma and carcinoma	Various organs	
	Metastases	Myocardium, soft tissues, lung, other organs	
	Lung carcinoma	Spleen	
	Breast carcinoma	Spleen	
	Spleen angiosarcoma	Spleen	
	Melanoma	Lung, stomach, kidney	
	Thyroid carcinoma	Liver	
	Colon cancer	Colon	
	Other tumors	Various organs	
Haematological disorders	Lymphoma	Spleen, other organs	
	Leukemia	Spleen, other organs	
	Multiple myeloma	Soft tissues, spleen, liver, other organs	
	Waldenstrom macroglobulinemia	Lung, liver, spleen, other organs	
	Sickle cell disease	Myocardium, other organs	
	Megaloblastic anemia	Spleen	
	Thalassemia major	Spleen	
Metabolic diseases	Nephrocalcinosis	Myocardium	
	Amyloidosis	Myocardium, soft tissues	
	Hypercalcemia	Myocardium	
	Alterations in calcium metabolism	Soft tissues	
	Renal failure	Lung, Myocardium, other organs	
	Calcinosis and calcifications	Various organs	
	Hypersplenism	Spleen	
	Iron overload	Kidney	
	Vascular diseases	Vasculitis	Myocardium, lung, other organs
		Atherosclerosis	Myocardium
Infarction and ischemia		Myocardium, spleen, brain	
Inflammatory diseases	Diverticulitis	Colon	
Other	Physical exercise	Soft tissues, muscles	
	Unknown origin	Myocardium, soft tissues	
	Cold exposure	Soft tissues	
	Aematomas	Various localizations	
	Calcium injection	Soft tissues	
	Arterial injection	Soft tissues	
	Liver transplantation	Soft tissues	

Different organs can present an abnormal uptake and this finding is often accompanied by systemic diseases, although the underlying cause remains unknown in most cases. We could demonstrate a precise pathophysiological mechanism only in the patient of case no. 2, diagnosed with amyloidosis and in patient of case no. 3, who was diagnosed with Waldenstrom macroglobulinemia.

Although amyloidosis is a known complication of IgG gammopathies, IgM-related amyloidosis represents an extremely rare entity, described in a few cases [10]. In particular, it was reported in only 2.2% of patients with IgM monoclonal gammopathies [11]. Patients affected by IgM-related amyloidosis usually present a peculiar pattern of organ involvement, with more frequent lymph node and lung involvement compared to patients with non-IgM amyloidosis [10].

An extrasosseous uptake has been described before [12] in a patient affected by Waldenstrom macroglobulinemia, even if in this case only hepatic and spleen involvement was present, while our description is the first case of a myocardial uptake related to such a condition.

In our first case, no apparent explanation could be hypothesized for the uptake involving the left upper extremity. Phosphates uptakes in soft tissues have also been reported and many causes have been described [13]; anyway, none of them were diagnosed in our patient and, moreover, there is not a clear explanation why this finding was not present on the first body scan, performed only two days before.

As previously mentioned, extravenuous administration could not be a cause, since the site of injection was the right arm. For the

same reason, contamination or intra-arterial injection, which was reported to be another possible cause of soft tissue uptake [14], was excluded. The preparation of the radiopharmaceutical had no issues as well.

Also physical exercise could be suspected: some cases have been reported in literature [15–20] but the pattern of uptake which is confined to the left forearm makes this unlikely. Cold exposure was suspected as well, but could not be properly confirmed.

To our knowledge, no other reports can be found in literature, comparing two body scans and demonstrating the onset of an uptake on an extremity in a so short time interval.

Other cases of myocardial uptake have been described in literature.

Al-Nahhas et al. described 19 myocardial uptakes (17 males, one female) and observed that most of the male patients with increased myocardial uptake had prostatic carcinoma and were over 80 years of age [21]. Wadhwa et al reported HDP uptake in cardiac amyloidosis in a background of tuberculosis, prostate cancer and coronary artery disease in an 86 year old patient. [22].

Chadrawar et al. presented another case of myocardial uptake without a clear cause and reviewed the literature concerning this phenomenon [23]. Jones et al reported on prominent myocardial uptake in 10 elderly men on HDP bone scan due to obscure benign etiology but presumably with atherosclerosis as contributing factor [24].

Other causes described in literature are amyloidosis [25–27], hypercalcemia [28, 29], metastases [30–32], vasculitis [33], nephrocalcinosis [21]; anyway, in many cases no correlations with other pathologies can be demonstrated [34].

Soft tissues are other potential sites for extrasosseous uptake and have been reported to be correlated to conditions like amyloidosis [35], alterations in calcium metabolism [36, 37], metastases [38] and multiple myeloma [39–41].

Extrasosseous uptakes of ^{99m}Tc -labelled phosphates involving other organs are reported in patients with leukemia [41–44], parathyroid carcinoma [45], parathyroid adenoma [46], renal failure [38, 47, 48], lymphomas [49–51], multiple myeloma [52, 53], Waldenstrom macroglobulinemia [12, 54], hematological disorders [55–60], tumors [61–69], calcinosis [70, 71] and vasculitis [72].

Finally, other papers report HDP uptakes in hematomas [4–9, 73], cold exposure [74], hypercalcemia [75], diverticulitis [76] and calcium injection [77].

Although calcifications in various organs could also be consequent to multiple small infarcts of extremely small size [78–80], definite pathologic findings which could demonstrate the presence of ischemia can be hardly found in the cases reported in literature [81].

There is an evidence that calcium phosphate molar ratio, crystalline surface area, and presence of other metallic ions are factors that determine the reactivity of diphosphonates to a calcium deposition [75, 82]; as an example, high concentrations of iron in soft tissues produce extraskelatal Tc-99m MDP uptake [60, 83].

The most probable mechanism is an impairment of calcium metabolism, as it can be often observed in systemic diseases and in some paraneoplastic syndromes; normally, pure and amorphous calcium phosphate accumulations with a low molar ratio and a large surface area can be found in sites of ^{99m}Tc -labelled phosphates, causing an avid diphosphonate adsorption similar to that of mature hydroxyapatite [71].

Conclusion

Extrasosseous uptake of ^{99m}Tc -labelled phosphates is a relatively rare finding, which is however increasing in clinical reports.

Large studies investigating the precise pathophysiologic mechanisms related to this phenomenon would be desirable, even if the huge variability of possible conditions limits this possibility.

References

- Peller PJ, Ho VB, Kransdorf MJ. Extrasosseous Tc-99 MDP uptake: a pathophysiologic approach. *Radiographics* 1993; 13: 715–734.
- Xu YH, Song HJ, Qiu ZL, Luo QY. Multiple extrasosseous accumulation of ^{99m}Tc -MDP in acute lymphocytic leukemia and reference to literature. *Hell J Nucl Med* 2010; 13: 273–276.
- Kim SH, Zeon SK, Choi BW et al. Extrasosseous Bone Tracer Accumulation of the Liver on ^{99m}Tc -HDP Bone Scintigraphy in Intermittent Bleeding After Iatrogenic Liver Injury. *Clin Nucl Med* 2012; 37: 995–996.
- Bhattacharya A, Prasad V, Mittal BR. Tc-99m MDP uptake in a soft tissue hematoma of the chest wall. *Clin Nucl Med* 2004; 29: 454–455.
- Park C, LaRoy L, Ali A, Fordham EW. Pelvic hematoma diagnosed on technetium-99m methylene diphosphonate bone imaging. *Clin Nucl Med* 1989; 14: 139–140.
- Tondeur M, Michel O, Ham HR. Extrasosseous Tc-99m methylene diphosphonate uptake related to pulmonary bleeding. *Clin Nucl Med* 1997; 22: 255–256.
- Nguyen HV, Chiam QL, Dixon H, Goddard KA. Traumatic retroperitoneal hematoma illustrated on Tc-99m methylene diphosphonate bone scintigraphy in a patient presenting with a fall. *Clin Nucl Med* 2007; 32: 635–637.
- Lee VW, Leiter BE, Weitzman F, Shapiro JH. Occult gastric bleeding demonstrated by bone scan and Tc-99m-DTPA renal scan. *Clin Nucl Med* 1981; 6: 470–473.
- Jacobsson A, Kaiser S, Granholm T, Ringertz HG. Neonatal adrenal haemorrhage at bone scintigraphy: a case report. *Pediatr Radiol* 1998; 28: 896–898.
- Terrier B, Jaccard A, Harousseau JL et al. The Clinical Spectrum of IgM-Related Amyloidosis A French Nationwide Retrospective Study of 72 Patients. *Medicine* 2008; 87: 99–109.
- Gertz MA, Kyle RA. Amyloidosis with IgM monoclonal gammopathies. *Semin Oncol* 2003; 30: 325–328.
- Yang JG, Yin CH, Li CL, Zou LF. Simultaneously significant hepatic and mild splenic uptake of Tc-99m MDP resulting from Waldenstrom macroglobulinemia. *Clin Nucl Med* 2009; 34: 441–442.
- Ergün EL, Ceylan E. Soft tissue uptake observed on Tc-99m MDP bone scans: rare imaging patterns in two cases. *Clin Nucl Med* 2001; 26: 958–959.
- Bybel B, Kwok P, Neumann DR. Arterial injection artifact on F-18 FDG positron emission tomographic scan. *Clin Nucl Med* 2003; 28: 350.
- Lafforgue P, Silas S, Daumen-legre V, Acquaviva PC. An unexpected, benign cause of increased muscular uptake at bone scintigraphy. *Clin Exp Rheumatol* 1994; 12: 309–311.
- Groell R, Aigner R. Extrasosseous uptake of Tc-99m methylene diphosphonate in the pectoralis muscles 8 days after exercise. *Clin Nucl Med* 2000; 25: 65–66.
- Kao PF, Tzen KY, Chen JY, Lin KJ, Tsai MF, Yen TC. Rectus abdominis rhabdomyolysis after sit ups: unexpected detection by bone scan. *Br J Sports Med* 1998; 32: 253–254.
- Frater C, Rossleigh M, Murray P. Specific muscle uptake on bone scintigraphy after strenuous activity. *Clin Nucl Med* 1997; 22: 857.
- Olea E, Ortiz V, Nagel J, Arenas L. Bone seeking agent uptake in abdominal muscle after exercise. *Clin Nucl Med* 1995; 20: 561–562.
- Kung JW, Yu JQ, Lee B, Alavi A, Zhuang H. Increased Tc-99m MDP accumulation in soft tissue caused by bicycle riding. *Clin Nucl Med* 2004; 29: 279–280.
- Al-Nahhas AM, Jinnouchi S, Anagnostopoulos C, Hirsch W, Heary T, McCready VR. Clinical significance of technetium-99m methylene diphospho-

- nate myocardial uptake: association with carcinoma of the prostate. *Eur J Nucl Med* 1995; 22: 148–153.
22. Wadhwa SS, Nour R. Tc 99m HDP uptake in cardiac amyloidosis. *Clin Nucl Med* 1999; 24: 156–158.
 23. Chadrawar S, George M, Al-Akraa M, Herber M, Buscombe J. Myocardial uptake of Tc 99m HDP in a patient with prostate cancer. *Nucl Med Rev Cent East Eur* 2009; 12: 78–80.
 24. Jones A, Keeling D. Benign myocardial uptake of hydroxymethylene diphosphonate. *Nucl Med Commun* 1994; 15: 21–23.
 25. Kinney EL, Chandarlapaty SK. Transient myocardial uptake of Tc-99m methylene diphosphonate in a patient with amyloidosis. *Am J Med Sci* 1988; 296: 413–416.
 26. Ak I, Vardareli E, Erdinç O, Kasapoğlu E, Ata N. Myocardial Tc-99m MDP uptake on a bone scan in senile systemic amyloidosis with cardiac involvement. *Clin Nucl Med* 2000; 25: 826–827.
 27. Kulhanek J, Movahed A. Uptake of technetium 99mHDP in cardiac amyloidosis. *Int J Cardiovasc Imaging* 2003; 19: 225–227.
 28. Di Leo C, Gallieni M, Bestetti A et al. Cardiac and pulmonary calcification in a hemodialysis patient: partial regression 4 years after parathyroidectomy. *Clin Nephrol* 2003; 59: 59–63.
 29. Atkins HL, Oster ZH. Myocardial uptake of a bone tracer associated with hypercalcemia. *Clin Nucl Med* 1984; 9: 613–615.
 30. Kawase T, Fujii H, Nakahara T, Shigematsu N, Kubo A, Kosuda S. Intense Accumulation of Tc-99m MDP in Pericardial Metastasis From Breast Cancer. *Clin Nucl Med* 2009; 34: 173–174.
 31. Phillips CD, Williamson BR. Osteosarcoma with pericardial metastases seen on bone scan. *Clin Nucl Med* 1987; 12: 899–900.
 32. Valdez VA, Jacobstein JG. Visualization of a malignant pericardial effusion with Tc-99m-EHDP. *Clin Nucl Med* 1980; 5: 210–212.
 33. Macdonald WB, Troedson RG. Unexpected myocardial uptake on bone scintigraphy in an infant with Kawasaki disease. *Clin Nucl Med* 2001; 26: 455.
 34. Poblete Garcia VM, Rodado Marina S, Garcia Vicente A, Soriano Castrejón A. Benign myocardial uptake of 99mTc-HMDP in prostate carcinoma: based on three cases. *Rev Esp Med Nucl* 2003; 22: 35–39.
 35. Janssen S, Piers DA, van Rijswijk MH, Meijer S, Mandema E. Soft tissue uptake of 99mTc-diphosphonates and 99mTc-pyrophosphate in amyloidosis. *Eur J Nucl Med* 1990; 16: 663–670.
 36. Palmer AM, Watt I, Dieppe PA. Soft tissue localization of 99mTc HDMP due to interaction with calcium. *Clin Radiol* 1992; 45: 326–330.
 37. Munoz SJ, Nagelberg SB, Green PJ et al. Ectopic soft tissue calcium deposition following liver transplantation. *Hepatology* 1998; 8: 476–483.
 38. Low RD, Hicks RJ, Arkles LB, Gill G, Adam W. Progressive soft tissue uptake of Tc-99m MDP reflecting metastatic microcalcification. *Clin Nucl Med* 1992; 17: 658–662.
 39. Evans JC, Murphy M, Eyes B. Extensive soft tissue uptake of Tc-99mMDP in a patient with multiple myeloma. *Br J Radiol* 2000; 73: 1018–1020.
 40. Kanoh T, Uchino H, Yamamoto I, Torizuka K. Soft tissue uptake of Tc-99m MDP in multiple myeloma. *Clin Nucl Med* 1986; 11: 878–879.
 41. Marwah A, Kumar R, Dasan JB Choudhury S, Bandothyaya G, Malhotra A. Soft tissue uptake of Tc-99m MDP in acute lymphoblastic leukemia. *Clin Imaging* 2002; 26: 206–208.
 42. Togawa T, Hoshi K, Kimura K et al. A case of adult T-cell leukemia with metastatic calcification. *Eur J Nucl Med* 1985; 10: 90–92.
 43. McHugh K, Lee DM, Batty VB. Splenic accumulation of technetium 99m in chronic lymphocytic leukaemia. *Br J Radiol* 1988; 61: 957–959.
 44. Franceschi D, Nagel JS, Holman BL. Splenic accumulation of technetium 99mmethylene diphosphonate in a transfusion-dependent patient with chronic myelogenous leukemia. *J Nucl Med* 1990; 31: 1552–1553.
 45. Davidson RM, Dhokne RD, Moore WH, Butler DB. Metastatic calcification in a patient with malignant parathyroid carcinoma. Correlation of clinical, surgical, radiographic, and scintigraphic findings. *Clin Nucl Med* 1990; 15: 692–696.
 46. Hwang GJ, Lee JD, Park CY, Lim SK. Reversible extraskeletal uptake of bone scanning in primary hyperparathyroidism. *J Nucl Med* 1996; 37: 469–471.
 47. Strain JP, Hill TC, Parker JA, Donohoe KJ, Kolodny GM. Diffuse, intense lung uptake on a bone scan: a case report. *Clin Nucl Med* 2000; 25: 608–610.
 48. Suzuki A, Togawa T, Kuyama J et al. Extrasosseous accumulation of bone scanning agents in malignant brain tumors: comparison to semiquantitative evaluation with 99mTc SPECT/201TI SPECT and histological findings. *Ann Nucl Med* 2003; 17: 387–392.
 49. Ceylan Gunay E, Erdogan A, Apaydin D. Unusual extrasosseous tumoral accumulation of 99mTc-MDP in non-Hodgkin's lymphoma in two cases. *Rev Esp Med Nucl* 2011; 30: 162–164.
 50. Winter PF. Splenic accumulation of 99mTc-diphosphonate. *J Nucl Med* 1976; 17: 850.
 51. Nisbet AP, Maisey MN. Splenic accumulation of technetium 99m-methylene diphosphonate. *Br J Radiol* 1982; 55: 454–455.
 52. Berk F, Demir H, Hacihanefioglu A et al. Hepatic and splenic uptake of Tc-99m HDP in multiple myeloma: additional findings on Tc-99m MIBI and Tc-99m sulfur colloid images. *Ann Nucl Med* 2002; 16: 137–141.
 53. Eagel BA, Stier SA, Wakem C. Non-osseous bone scan abnormalities in multiple myeloma associated with hypercalcemia. *Clin Nucl Med* 1988; 13: 869–873.
 54. Ortapamuk H, Alp A. Lung uptake on a bone scan: a case of pulmonary Waldenstrom's macroglobulinemia. *Ann Nucl Med* 2002; 16: 487–489.
 55. Yapar AF, Aydin M, Reyhan M. Diffuse splenic Tc-99m MDP uptake in hypersplenic patient. *Ann Nucl Med* 2004; 18: 703–705.
 56. Cerci SS, Suslu H, Cerci C et al. Different findings in Tc-99m MDP bone scintigraphy of patients with sickle cell disease: report of three cases. *Ann Nucl Med* 2007; 21: 311–314.
 57. Koizumi M, Suzuki T, Takahashi S, Ogata E. Transient splenic accumulation of Tc-99m HMDP caused by megaloblastic anemia. *Clin Nucl Med* 2000; 25: 1024–1027.
 58. Howman-Giles RB, Gilday DL, Ash JM, Brown RG. Splenic accumulation of Tc-99m diphosphonate in thalassemia major. *J Nucl Med* 1978; 19: 976–977.
 59. Costello P, Gramm HF, Steinberg D. Simultaneous occurrence of functional asplenia and splenic accumulation of diphosphonate in metastatic breast carcinoma. *J Nucl Med* 1977; 18: 1237–1238.
 60. Ohta H. Liver uptake and increased renal uptake of Tc-99m HMDP in a patient with iron overload. *Clin Nucl Med* 2001; 26: 164–165.
 61. Sirota P, Nelp WB. Unexplained transient splenic uptake of Tc-99m MDP in bronchogenic carcinoma. *Clin Nucl Med* 1984; 9: 495–497.
 62. Mathews J, Sziklas JJ, Spencer RP. Functional asplenia and uptake of bone imaging agent in angiosarcoma of spleen. *Clin Nucl Med* 1985; 10: 527–528.
 63. Wheat D, McCarthy P. Metastatic pulmonary, gastric, and renal calcification demonstrated on bone scintigraphy in a patient with malignant melanoma and renal failure. *Clin Nucl Med* 1998; 23: 824–827.
 64. Gholamrezanezhad A, Moinian D, Mirpour S, Hajimohammadi H. Unilateral pulmonary metastases from Ewing's sarcoma shown in a technetium-99m-methylene-diphosphonate bone scan. *Hell J Nucl Med* 2006; 9: 181–183.
 65. Thomas BG, Silverman ED. Focal uptake of Tc-99m MDP in a Gossypiboma. *Clin Nucl Med* 2008; 33: 290–291.
 66. Ali I, Johns W, Gupta SM. Visualization of hepatic metastases of medullary thyroid carcinoma on Tc-99m MDP bone scintigraphy. *Clin Nucl Med* 2006; 31: 611–613.
 67. Nair N, Goyal V, Nair CN. Uptake of Tc-99m MDP by a primitive neuroectodermal tumor of the liver. *Clin Nucl Med* 1998; 23: 548–549.
 68. Shih WJ, DeLand FH, Domstad PA et al. Extrasosseous localization of 99mTc-MDP in ganglioneuroblastoma. *Eur J Nucl Med* 1982; 7: 336–338.
 69. Tomonori Y, Noriyuki S, Koji T et al. Tc-99m MDP uptake by an advanced colon cancer lesion in a juvenile patient. *Clin Nucl Med* 2000; 25: 295–296.
 70. Chang CY, Cheng CY, Shen DH, Bai CY, Lin LF, Huang WS. Tumoral calcinosis demonstrated on Tc-99m sestamibi scintigraphy. *Clin Nucl Med* 2008; 33: 920–921.

71. Agrawal A, Purandare N, Sridhar E, Shah S, Dua SG, Rangarajan V. Imaging findings in a rare case of extra-articular chondrocalcinosis. *Clin Nucl Med* 2012; 37: 184–187.
72. Kuyvenhoven JD, Ommeslag DJ, Ackerman CM, Hilderson JM, Troch ME. Lung uptake on technetium-99m-MDP bone scan in Wegener's vasculitis. *J Nucl Med* 1996; 37: 857–858.
73. Williams HT, Sorsdahl OA. SPECT imaging of intense bone tracer uptake by an extensive extraosseous hemangioma. *Clin Nucl Med* 1993; 18: 358–360.
74. Shih WJ, Riley C, Magoun S et al. Intense bone imaging agent uptake in the soft tissues of the lower legs and feet relating to ischemia and cold exposure. *Eur J Nucl Med* 1988; 14: 419–421.
75. Castaigne C, Martin P, Blocklet D. Lung, gastric, and soft tissue uptake of Tc-99m MDP and Ga-67 citrate associated with hypercalcemia. *Clin Nucl Med* 2003; 28: 467–471.
76. Chang WK, Shih WJ, Primo M. Diffusely increased radioactivity in the left abdomen on bone scan of patient with acute colonic diverticulitis: correlation with CT. *Clin Nucl Med* 2004; 29: 564–566.
77. Planchon CA, Donadieu AM, Perez R, Cousins JL Jr. Calcium heparinate induced extraosseous uptake in bone scanning. *Eur J Nucl Med* 1983; 8: 113–117.
78. Wakat MA, Chilton HM, Hackshaw BT, Cowan RJ, Ball JD, Watson NE Jr. Comparison of Tc-99m pyrophosphate and Tc-99m hydroxymethylene diphosphonate in acute myocardial infarction: concise communication. *J Nucl Med* 1980; 21: 203.
79. Silberstein EB, DeLong S, Cline J. Tc-99m diphosphonate and sulfur colloid uptake by the spleen in sickle cell disease: interrelationship and clinical correlates: concise communication. *J Nucl Med* 1984; 2: 1300–1303.
80. Christopher MG. Tc-99m MDP uptake resulting from acute middle cerebral artery territory infarction. *Clin Nucl Med* 2003; 28: 851–852.
81. Dewanjee MK, Kahn PC. Mechanism of localization of 99mTc-labeled pyrophosphate and tetracycline in infarcted myocardium. *J Nucl Med* 1976; 17: 639–646.
82. Peller PJ, Ho VB, Kransdorf MJ. Extraosseous Tc-99m MDP uptake: a pathophysiologic approach. *RadioGraphics* 1993; 13: 715–734.
83. Byun HH, Rodman SG, Chung KE. Soft-tissue concentration of 99mTc phosphates associated with injection of iron dextran complex. *J Nucl Med* 1976; 17: 374–375.