

V/P scan in diagnosis and follow-up of pulmonary embolism in 15–25-year-old females in relation to hormonal contraception use

Daniela Chroustova¹, Jozef Kubinyi¹, Pavel Jansa², Lenka Veprekova³, Jiří Trnka⁴

¹Department of Nuclear Medicine, General Teaching Hospital and First Faculty of Medicine, Charles University, Prague, Czech Republic

²2nd Department of Medicine — Department of Cardiovascular Medicine, General Teaching Hospital and First Faculty of Medicine, Charles University, Prague, Czech Republic

³Thrombotic Centre, General Teaching Hospital, Prague, Czech Republic

⁴Department of Medical Physics, General Teaching Hospital and First Faculty of Medicine, Charles University, Prague, Czech Republic

[Received 16 VIII 2011; Accepted 16 XI 2011]

Abstract

Background: An analysis of medical records of young females who were examined in our department during a five-year period (2005–2009) on suspicion of pulmonary embolism (PE) in relation to hormonal contraception (HC).

Material and methods: The patient sample included 86 young females aged 15–25 (mean 21) years who underwent a ventilation/perfusion scintigraphy (V/P scan). Seventeen of them were examined repeatedly. Altogether, 114 scintigraphic examinations were performed. Lung perfusion scintigraphy was performed using a planar gamma camera (Mediso MB 9200) in 4 projections following 100 MBq ^{99m}Tc — MAA *i.v.* application with 81 mKr ventilation scintigraphy concurrently.

Results: 1. Among 57/86 (66%) patients on HC, 24 (42%) had scintigraphic signs of PE. 2. 11/57 (19%) of them had clinical signs of deep venous system thrombosis of the lower limbs that were confirmed by sonography. 3. Leiden mutation was found in 9/24 (37%) patients with PE. 4. Among 29/86 (34%) females not taking HC, PE was detected in only 3 patients (10%). 5. 10/17 (59%) repeatedly examined females had permanent post-embolic residual changes of lung perfusion.

Conclusions: In our group of patients who underwent a P/V scan, 42% of those on HC were diagnosed with PE on scintigraphy, compared to 10% of those not taking HC. Among the patients with PE, there were 10/24 (42%) young females with persistent post-embolic changes. Our study indicates that the well-known risk of venous thromboembolism related to the use of HC needs to be considered as a cause of PE even among very young females. In our experience, prevention of these life-threatening conditions in patients with a family history of venous thromboembolism consists of timely examination of their thrombotic profile and selection of appropriate contraception.

Key words: pulmonary embolism, hormonal contraception, V/P scan

Nuclear Med Rev 2011; 14, 2: 63–67

Introduction

Pulmonary embolism (PE) is a common, serious, but treatable medical condition caused by migration of a thrombus to the pulmonary circulation, usually from the veins of the lower extremities [1]. It can cause death or lead to chronic thromboembolic pulmonary hypertension at any age. In recent years, the number of young females treated for PE or deep-vein thrombosis in the legs has been increasing in the Czech Republic. Hormonal contraception (HC) is an effective form of contraception used by 100 million women world-wide. While its effect on the incidence of

Correspondence to: Daniela Chroustova
 Department of Nuclear Medicine, General Teaching Hospital and First Faculty of Medicine, Charles University, U Nemocnice 5, 128 08 Prague 2, Czech Republic
 Tel: 420 224965973, fax: 420 224922486
 e-mail: Daniela.Chroustova@vfjn.cz

venous thromboembolism (VTE) is not large, it is an important risk factor of VTE in 15–45-year-old women. As the potential risk of VTE in younger women has not been determined, we have performed a retrospective analysis of PE diagnosed by a pulmonary V/P scan in all 15–25-year-old females examined in our department during a five-year period (2005–2009) in relation to hormonal contraception.

Material and methods

The patients group consisted of 86 females aged 15–25 years. (mean age 21 years) who had undergone a V/P scan. Seventeen of them were examined repeatedly with 1–2 control perfusion after PE. Altogether, 114 scintigraphic examinations were performed.

V/P scan with planar imaging was done using a planar gamma camera (Mediso MB 9200) in 4 projections. Perfusion studies were performed with the use of ^{99m}Tc — MAA (macroaggregated human albumin); followed with ^{81m}Kr ventilation scintigraphy simultaneously. ^{81m}Kr is a gas produced from a generator of rubidium (^{81}Rb). This gas has the ideal gamma energy of 193 keV and a half-life of 13 seconds. Data acquisition of both investigations included four views: anterior, posterior, and right and left posterior oblique (ANT, POST, RPO, LPO), using low-energy collimator, 400 000 counts/image, matrix 128×128 .

Evaluation

In our study we evaluated our findings according the recommended criteria PLOPED II [1, 3].

Results

The incidence of PE in relation to hormonal contraception use in our group of patients is presented in Table 1.

- 57/86 (66%) of our patients were using HC.
- Among the 57 on HC, 24 (42%) had scintigraphic signs of PE.
- Among 29/86 (34%) females not using HC, PE was detected in 3 patients (10%) only. Pathological scintigraphic findings of PE were evident and quite large at V/P scans in the majority of the positive cases (Figure 1). Their evaluation was usually without diagnostic problems. Changes with multiple, very small defects were found rarely (Figures 2 and 4). Recanalisation of the lungs was a common finding (Figure 3).
- 11/57 (19%) of them had clinical signs of deep venous system thrombosis of lower limbs that were confirmed by sonography.
- Leiden mutation was found in 9/24 (37%) patients with PE.
- 10/17(59%) females who were examined repeatedly had permanent post-embolic residual changes of lung perfusion (Figure 5).

Discussion

PE presents with recognized patterns of symptoms that may include unexplained breathlessness, chest pain (central or pleuritic), cough, haemoptysis, syncope, palpitations, tachypnoea, tachycardia (heart rate > 100 bpm), cyanosis, fever, hypotension (systolic blood pressure < 100 mm Hg), right heart failure, pulmonary hypertension, and leg swelling.

Table 1. Incidence of pulmonary embolism (PE) in relation to hormonal contraception use in our group of patients

HC	No (%)	Positive signs of PE		Negative signs of PE	
		No (%)	No (%)	No (%)	No (%)
HC use	57 (66%)	24 (42%)	33 (58%)		
HC not use	29 (34%)	3 (10%)	26 (90%)		
Total	86 (100%)	27 (31%)	59 (69%)		

HC — hormonal contraception

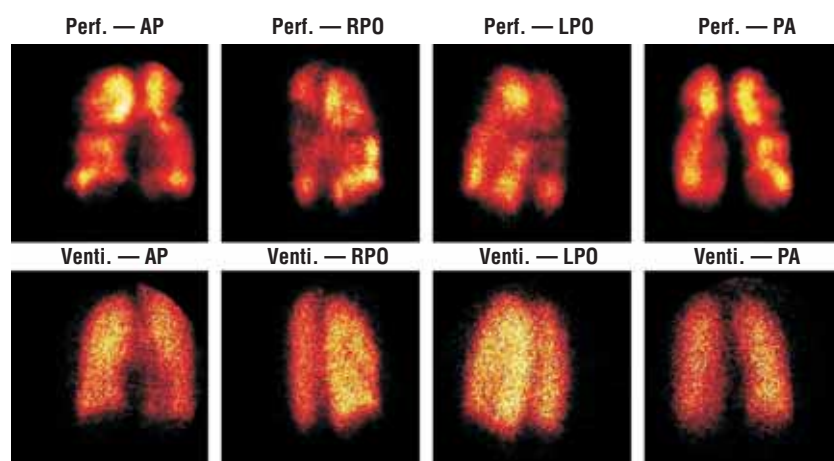


Figure 1. V/P scans with the high probability of the bilateral pulmonary embolism (PE) in a 24-year-old woman. Scans with multiple perfusion defects of both lungs (upper row), scans with homogenous lung ventilation.

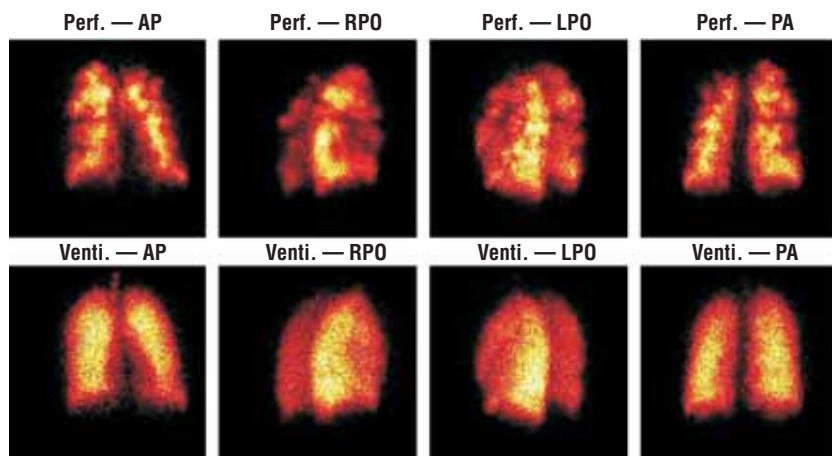


Figure 2. V/P scans with pathological signs in a 25-year-old woman with chronic thromboembolic pulmonary hypertension (CTEPH). Scans with multiple, very small perfusion defects of the lungs (upper row), scans with homogenous lung ventilation (bottom row).

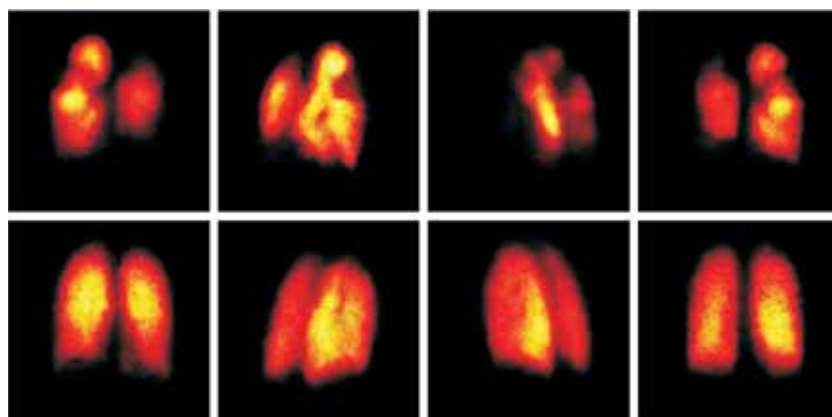


Figure 3. Scan with large perfusion defects (upper row), normalization of the pathologic signs after anticoagulative therapy (bottom row) in a 17-year-old girl with pulmonary embolism (PE).

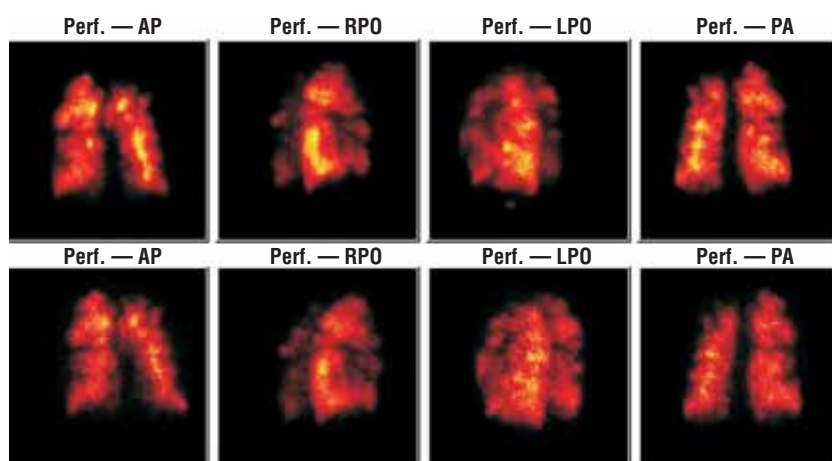


Figure 4. Comparison of pre therapy perfusion scan (upper row), with post therapy perfusion scan (bottom row). No recanalisation after 3 weeks of therapy.

However, these clinical features are also common in patients without PE. They may develop abruptly or insidiously over days and weeks. While certain symptoms and signs are more

commonly observed in PE than in other conditions, the diagnosis of PE cannot be made from clinical features alone. Rather, it must be confirmed or refuted on the basis of a conclusive imaging test,

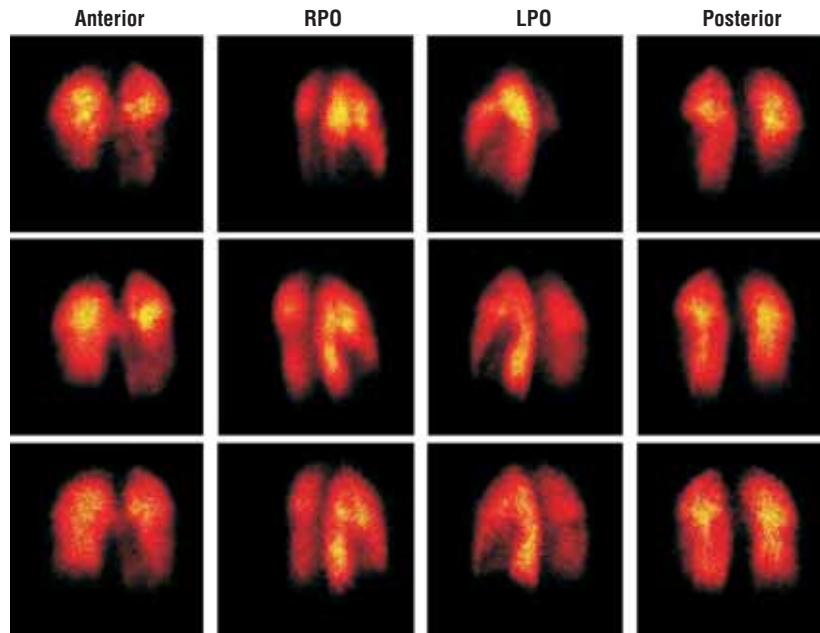


Figure 5. Development of the postembolic residual perfusion changes in a 20-year-old woman after pulmonary embolism (PE). First examination immediately after PE (upper row), second examination 3 weeks (medium row) after PE, third examination 8 weeks (bottom row) after PE.

performing a V/P scan, or multidetector computed tomography of the pulmonary arteries (MDCT). Pulmonary angiography (PA) is considered to be the “gold standard”, but it is invasive, difficult to perform, and not readily available and is now rarely used in routine clinical practice. Methods based upon magnetic resonance have not yet been established [2, 3].

V/P scan is more readily available than MDCT but access to both techniques is vital for the diagnosis of PE. MDCT is often contraindicated for complications including an allergy or contrast-agent extravasation. By contrast, a V/P scan has no contraindications, complications do not occur, and it carries a much lower radiation burden than MDCT. Therefore, V/P scan is recommended as a first-line procedure in young patients, especially females, with suspected PE [3, 4].

The main indication for V/P scan in our study were successive PEs, commonly caused by migration of a thrombus to the pulmonary circulation. Usually, this is due to the embolism of a blood clot from the deep veins in the legs, a process termed venous thromboembolism (VTE).

Multiple risk factors of VTE are congenital and acquired [5]. Congenital genetic causes of the hypercoagulable state: antithrombin III deficiency, deficiency of the other coagulative inhibitors, C and S protein deficiency, factor II deficiency (prothrombin deficiency), and factor V Leiden mutation. Acquired predisposition of VTE: extensive varicose vein, obesity, trauma, surgery, malignancy, antiphospholipid syndrome, and some kinds of medication — not least HCs. A more recently recognized risk factor is long-distance flights, even in healthy individuals [6]. It is well known that the use of oestrogen-progesterone-OC gives rise to a risk of VTE. Therefore, lower oestrogen medication has begun to be applied in common practice, but a risk of VTE persists. VTE risk depends, in addition to the oestrogens, on the presence of progestin and its types as well. In the literature more papers were noted which were devoted to the effect of OC use on the emer-

gence of VTE risk [7, 8]; a few of them compared and assessed the VTE risk in third- and second-generation OCs [9, 10]. For VTE development, time is also very important — how long a woman uses OCs [11]. The risk of venous thrombosis in current users of combined OCs decreases with duration of use and decreasing oestrogen dose. For the same dose of oestrogen and the same length of use, OCs with desogestrel, gestodene, or drospirenone were associated with a significantly higher risk of venous thrombosis than OCs with levonorgestrel. Progestogen-only pills and hormone-releasing intrauterine devices were not associated with any increased risk of venous thrombosis [12].

The relatively small risk of VTE attributable to oral HC use may interact geometrically with the procoagulant mutations and the combination of the mutations in the prothrombin gene, and factor V Leiden is associated with a greater risk of thrombosis. The relative risk for VTE in women who have this mutation is approximately 35 for OC users compared with nonusers [13]. Leiden mutation was the most frequent finding in our group of patients. Two thirds of our patients used per oral HCs. But that is a big heterogeneous group in which women were medicated with different sorts of HCs (second or third generation oral contraceptives) and during different time periods (1–7 years). Overall, the young women who have undergone PE are not numerous, but the prevention of this life-threatening status should be more consistent with a detailed personal and family history of VTE and timely examination of their thrombotic profile before OC pill prescription.

Conclusions

The majority of our patients who underwent a V/P used HC. PE was confirmed by scintigraphy in 42% of them. In comparison, only 10% of females not using HC were positive for PE. 42% of patients with PE had persistent postembolic changes.

The risk of venous thromboembolism related to the use of HC is well known. Our study indicates that VTE needs to be considered as a cause of PE even in very young females.

In our experience, prevention of this life-threatening status in patients with family history of venous thromboembolism consists of timely examination of their thrombotic profile and selection of appropriate contraception.

References

1. Bajc M, Neilly JB, Miniati M, Schuemichen C, Meignan M, Jonson B. EANM guidelines for ventilation/perfusion scintigraphy Part 1. Pulmonary imaging with ventilation/perfusion single photon emission tomography. *Eur J Nucl Med Mol Imaging* 2009; 36: 1356–1370.
2. Baile EM, King GG, Muller NL et al. Spiral computed tomography is comparable to angiography for the diagnosis of pulmonary embolism. *Am J Respir Crit Care Med* 2000; 161: 1010–1015.
3. Bajc M, Neilly JB, Miniati M, Schuemichen C, Meignan M, Jonson B. EANM guidelines for ventilation/perfusion scintigraphy Part 2. Algorithms and clinical considerations for diagnosis of pulmonary embolism with V/PSPECT and MDCT. *Eur J Nucl Med Mol Imaging* 2009; 36: 1528–1538.
4. Tunariu N, Gibbs SJ, Win Z et al. Ventilation-perfusion scintigraphy is more sensitive than multidetector CTPA in detecting chronic thromboembolic pulmonary disease as a treatable cause of pulmonary hypertension. *J Nucl Med* 2007; 48: 680–684.
5. Anderson FA, Spencer FA. Risk factors for venous thromboembolism. *Circulation* 2003; 107: 1–9.
6. Lehmann R, Suess C, Leus M et al. Incidence, clinical characteristics, and long-term prognosis of travel-associated pulmonary embolism. *Eur Heart J* 2009; 30: 233–241.
7. Farmer RD, Lawrenson RA, Thompson CR, Kennedy JG, Hambleton IR. Population-based study of risk of venous thromboembolism associated with various oral contraceptives. *Lancet* 1997; 349: 83–88.
8. Spitzer WO, Lewis MA, Heinemann LA. Third generation oral contraceptives and risk of venous thromboembolic disorders: an international case — control study. Transnational research group on oral contraceptives and the health of young women. *BMJ* 1996; 312: 83–88.
9. Kaper RF, Norpoth T, Rekers H. Third- and second-generation oral contraceptives are associated with similar risk estimates for venous thromboembolism. *Eur J Contracept Reprod Health Care* 2002; 5: 1–15.
10. Rintelen C, Mannhalter C, Ireland H. Oral contraceptives and venous thrombosis: different sensitivities to activated protein C in women using second- and third-generation oral contraceptives. *Br J Haematol* 1996; 93: 487–490.
11. Bloemenkamp KW, Rosendaal FR, Helmerhorst FM. Higher risk OF venous thrombosis during early use of oral contraceptives in women with inherited clotting defects. *Arch Intern Med* 2000; 160: 49–52.
12. Lidegaard Ø, Løkkegaard E, Svendsen AE et al. Hormonal contraception and risk of venous thromboembolism: national follow-up study. *BMJ* 2009, 339: b2890.
13. Greydanus DE, Patel DR, Rimsza ME. Contraception in the adolescent: an update. *Pediatrics* 2001; 107: 562–573.