

The effect of image translation table on diagnostic efficacy of myocardial perfusion SPECT studies

Jakub Siennicki¹, Jacek Kuśmierk²,
Katarzyna Kovacevic-Kuśmierk¹, Małgorzata Bieńkiewicz¹,
Krzysztof Chiżyński³, Anna Płachcińska¹

¹Department of Quality Control and Radiological Protection,
Chair of Diagnostic Imaging, Medical University, Łódź, Poland

²Department of Nuclear Medicine, Chair of Diagnostic Imaging,
Medical University, Łódź, Poland

³Department of Cardiology, ¹st Chair of Cardiology and Cardiosurgery,
Medical University of Łódź, Poland

[Received 14 II 2011; Accepted 18 II 2011]

Abstract

BACKGROUND: The aim of this study was to determine which of the most popular colour scales used in the Xeleris processing system (GE) should preferably be used during a clinical interpretation of myocardial perfusion images, and to find out whether a colour scale saturation level affects the diagnostic efficacy of the study. **MATERIAL AND METHODS:** From among 100 patients in whom a myocardial perfusion scintigraphy had been performed, a subgroup of people referred for coronary angiography, with neither prior history nor ECG signs of a myocardial infarction has been selected retrospectively. This group consisted of 41 patients (14 females) in the age group 46 to 76 years. All patients underwent two-day myocardial perfusion SPECT imaging using ^{99m}Tc-MIBI as a radiopharmaceutical.

Reconstructed slices were interpreted in 3 colour scales: white-red-yellow-green-blue-black with computer-assigned thresholds (French 100%), the same French scale but without a white colour (image maximum set manually to a border value

between red and white — French w.w.), and a white-yellow-violet-pink-blue-black scale (GEcolor), by consensus of two experienced nuclear medicine specialists. A semiquantitative method for evaluation of perfusion images was applied, based on myocardium segmentation. Perfusion in each segment was scored using a five-point system. Study interpretation (normal/abnormal perfusion) was based on summed stress scores (SSS), being equal/above or below a given threshold value. The choice of optimal SSS threshold value was based on sensitivity and specificity of the study in detection of perfusion defects resulting from critical stenoses of main coronary arteries

RESULTS: SSS values differed among colour scales ($p < 0.00001$). The lowest values were obtained for a French 100% scale (mean value = 5.0, SD = 8.0), the highest for French w.w. (mean values = 8.1, SD = 8.7), and for GE colour scale — mean value — 5.6, SD — 7.9. A French 100% scale gave high sensitivity (88%), as well as specificity (83%), but only when a low SSS threshold value of 2, hardly acceptable for study interpreters, was used. When higher threshold values were applied, they compromised the sensitivity of the study. A French w.w. scale with SSS threshold values lower than 3 provided a slightly higher sensitivity (94%), but with a significant reduction in specificity (to values below 50%). Only a threshold value of 4 provided acceptable, but still low specificity (63%) with preserved high sensitivity (88%). At the same time, the scale GE colour provided indices of diagnostic efficacy with the SSS threshold value of 3 as high as a scale French 100% with threshold value of 2. **CONCLUSIONS:** A French scale (Xeleris, GE) is not the scale of choice for the interpretation of myocardial perfusion SPECT images. It seems that a GE colour scale is better suited for this purpose. SSS threshold values accepted as diagnostic criteria for the detection of myocardial perfusion abnormalities should be suited separately for every translation table. The choice of optimal value should be verified by results of coronary angiography.

Key words: myocardial perfusion SPECT study, semiquantitative analysis, summed stress score, display translation table

Correspondence to: Anna Płachcińska
Department of Quality Control and Radiological Protection
Central Teaching Hospital
Czechosłowacka Str 8/10, 92–216 Łódź, Poland
e-mail: anna@csk.umed.lodz.pl

Nuclear Med Rev 2010; 13, 2: 64–69

Introduction

Single photon emission computed tomography myocardial perfusion imaging is a widely accepted study applied in the diagnosis of coronary artery disease. The reliability of a final study report relies on many factors depending on the acquisition as well as processing protocols. The process of obtaining a final report consists of many steps, and this is why myocardial perfusion scintigraphy is among the most complex of diagnostic procedures in nuclear medicine. Many procedural guidelines are available at present, published by several scientific societies like the European Association of Nuclear Medicine together with the European Society of Cardiology [1], the American Society of Nuclear Cardiology [2], and the Society of Nuclear Medicine [3], which are engaged in a detailed description of study acquisition and processing protocols in order to obtain a reliable final report and ensure patient safety. Although these procedure guideline documents are very extensive, in general they do not point out a display translation table (providing a translation from the number of counts to display colour and intensity) that would be optimal for presentation of reconstructed slices of myocardium. However, observations made by the authors of this communication indicate a significant role of a colour scale applied for the clinical interpretation of perfusion images.

To this end, the aim of this study was to determine which of the most popular colour scales should preferably be used during a clinical interpretation of myocardial perfusion images, as well as to find out whether the colour scale saturation level affects the diagnostic efficacy of the study.

Material and methods

From among 100 patients in whom a myocardial perfusion scintigraphy had been performed, a subgroup of people referred for coronary angiography, with neither prior history nor ECG signs of a myocardial infarction, without left ventricular contraction abnormalities, significant valvular insufficiency or myocardial hypertrophy diagnosed in echocardiography, has been selected retrospectively. This group consisted of 41 patients (14 females, 17 males) in the age from 46 to 76 years, body mass between 61 and 120 kg (mean value 78.9). In 23 patients, typical, and in the remaining 18, atypical stenocardial pain was revealed by anamnesis.

All patients underwent two-day myocardial perfusion SPECT imaging using ^{99m}Tc -MIBI as a radiopharmaceutical. Patients underwent treadmill testing via a Bruce protocol. A radiopharmaceutical, in a dose depending on body mass (11 MBq/kg), i.e. from 670 to 1320 MBq, was administered intravenously at peak stress after attainment of an adequate heart rate response to exercise (defined by 85% of age predicted maximum heart rate). Stress study acquisition was started 45 minutes, and rest study 1.5 hours post administration of the radiopharmaceutical. Patients were placed in a supine position, with left arm held above the head. SPECT studies were acquired on a dual-head Hawkeye gamma camera (GE) with detectors in L-mode and fitted with low energy high resolution collimators (energy window 140 keV \pm 10%) rotating between RPO (right anterior oblique — 45°) and LAO (left posterior oblique — 45°) position in a step and shoot mode, along a circular orbit. Each projection lasted

25 seconds. Studies were acquired with a zoom factor of 1.28 and stored in a 64 \times 64 matrix.

Tomographic reconstruction was performed with an iterative OSEM method (2 iterations, 10 subsets) without attenuation correction. Reconstructed series of slices were evaluated in 3 planes: transversal, coronal, and sagittal. Every set of slices was presented in 3 translation tables:

- A. Consisting of white, red, yellow, green, blue, and black colours and referred to as French in a Xeleris processing system (GE), with computer-assigned thresholds (French 100%) — Figure 1a.
- B. The same French scale, but without white colour (image maximum set manually to a border value between red and white) — French w.w. — Figure 1b.
- C. GE colour, consisting of white, yellow, violet, pink, blue, and black, recommended in a Xeleris system for evaluation of myocardial perfusion images with computer-assigned thresholds, referred to in a Xeleris system as GE colour — Figure 1c.

The choice of the above listed scales was based on a previous practice.

Reconstructed slices were interpreted in all 3 colour scales by consensus of two experienced nuclear medicine specialists, with blinding to other clinical information or results of coronary angiography. A semiquantitative method for evaluation of perfusion images was applied, based on myocardium segmentation recommended by the principal North American societies dealing with cardiac imaging [4] and also by guidelines of EANM [1]. Left ventricular myocardium was divided into 17 segments (Figure 2) in such a way that three short-axis slices: basal, mid, and apical, were subdivided into six segments each and a vertical long axis slice contained the 17th segment — the apex. Perfusion in each segment was scored using a five-point system (Table 1). Next, perfusion scores in all 17 segments of stress studies were summed, thus deriving summed stress scores (SSS), which were used as diagnostic criterion for the detection of perfusion abnormalities. Summed stress scores were in general simple summations of the scores given to the 17 segments excepting situations when a segment was assigned a score “1” (equivocal reduction of uptake) on both stress and rest images. Segments with stress/rest scores of 1.1 were ignored and considered 0.0 for purposes of deriving summed scores, in agreement with a recommendation of Berman et al. [5].

Next, SSS threshold values were selected for the detection of perfusion abnormalities. When SSS for a given perfusion study was equal or higher than the threshold value, perfusion defect was considered significant and the study result abnormal. Selection of SSS threshold values was done separately for each colour scale because of significant differences in SSS values observed for three colour scales. The choice of SSS threshold value was based on sensitivity and specificity of the study in detection of perfusion defects resulting from critical stenoses of main coronary arteries.

Results of myocardial SPECT perfusion study were verified by coronary angiography performed not later than three months after the study. Artery stenosis was assessed with a biplane method by an experienced radiologist. A stenosis was considered critical if artery lumen was reduced by at least 70%. Results of coronary angiography were divided into positive (critical stenosis of at least one main coronary artery) and negative (no such stenosis).

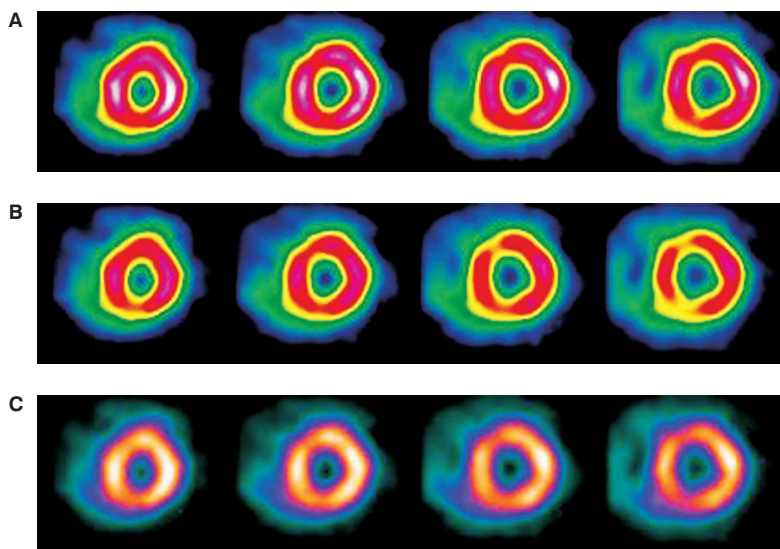


Figure 1. Examples of short axis slices of myocardial perfusion studies in 3 colour scales. **A.** French 100%; **B.** French w.w. (without white); **C.** GE color.

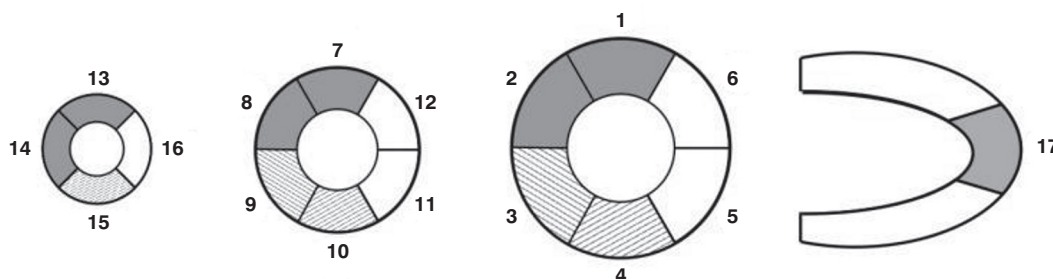


Figure 2. 17-segment model of left ventricular myocardium applied in semiquantitative assessment of myocardial perfusion. 1 — basal anterior, 2—basal anteroseptal, 3 — basal inferoseptal, 4 — basal inferior, 5 — basal inferolateral, 6 — basal anterolateral, 7 — mid anterior, 8 — mid anteroseptal, 9 — mid inferoseptal, 10 — mid-inferior, 11 — mid inferolateral, 12 — mid anterolateral, 13 — apical anterior, 14 — apical septal, 15 — apical inferior, 16 — apical lateral, 17 — apex.

Table 1. Five-point system score used for assessment of radio-pharmaceutical uptake in segments. According to Berman et al. [5]

0	Normal
1	Slight (equivocal) reduction of uptake
2	Moderate reduction of uptake (usually implies a significant abnormality)
3	Severe reduction of uptake
4	Absence of radioactive uptake

This enabled the determination of diagnostic efficacy of myocardial perfusion scintigraphy in the detection of perfusion abnormalities resulting from critical stenoses of main coronary arteries using three colour scales.

Statistical methods

The data were analysed by means of simple descriptive statistics of location and dispersion and non-parametric Wilcoxon

matched paired test for comparison of distributions of summed stress scores (SSS). In all analyses, statistical significance was considered achieved at a value of $p \leq 0.05$. All the calculations were derived by means of Statistica v8.0 software.

Results

The results of coronary angiography turned out negative in 24 patients and positive in 17, from among which seven patients had critical stenosis of two arteries, and one patient of three arteries. Five patients had a previous history of percutaneous transluminal coronary angioplasty (four patients of one artery, and one patient of two arteries).

Summed stress scores SSS differed among colour scales. The lowest values were obtained for a French 100% scale (mean value = 5.0, SD = 8.0), the highest was for French w.w. (mean values = 8.1, SD = 8.7), whereas in the case of GE colour scale, the mean value was 5.6, SD = 7.9. A statistically significant difference was found between mean SSS values for French w.w. and French 100% ($p = 0.000001$), as well as between French w.w. and GE colour ($p = 0.0001$). Differences between mean SSS

Table 2. Indices of diagnostic efficacy of myocardial perfusion SPECT study for specific SSS threshold values applied to images displayed in three color scales

Threshold	French 100%		French w.w.		GE color	
	Sensitivity	Specificity	Sensitivity	Specificity	Sensitivity	Specificity
1	94	75	100	25	88	54
2	88	83	94	33	88	79
3	82	96	94	50	88	83
4	77	96	88	63	82	88
5	77	100	82	75	77	88

SSS \geq threshold values were considered abnormal

values for French 100% and GE colour did not reach statistical significance ($p = 0.09$).

Table 2 presents indices of diagnostic efficacy of a myocardial SPECT perfusion study dependant on a colour scale (translation table) applied for display of images and SSS threshold values (SSS \geq respective threshold value formed the basis for detection of perfusion abnormalities).

A French colour scale with computer-assigned thresholds (French 100%) gave high sensitivity (88%, 15 out of 17 patients) and specificity (83%, 20 out of 24 patients), but only when a low SSS threshold value of 2 was used. When higher threshold values were applied, they compromised the sensitivity of the study.

A French translation table without white colour (French w.w.) with low SSS threshold values (lower than 3) provided a slightly higher sensitivity when compared to the French colour scale with computer-assigned thresholds (94%, 16 out of 17 patients), but with a significant reduction of specificity (to values below 50%). Only a threshold value of 4 provided acceptable specificity (63%, 15 out of 24 patients), with preserved high sensitivity (88%). At the same time, the GE colour scale provided indices of diagnostic efficacy with the SSS threshold value of 3 as high as a French scale 100% with threshold value of 2.

Figure 3 presents an example of images of the same patient in three colour scales together with respective SSS values.

Discussion

A semiquantitative method applied for the assessment of myocardial perfusion scintigraphy is at present the only relatively objective and acknowledged method for interpretation of perfusion images providing a high sensitivity of detection of perfusion abnormalities. A quantitative method based on the comparison of patient myocardial perfusion images with normative values derived from a group of patients with normal myocardial perfusion, in the form of a bull's-eye map, is only a supplement, although valuable, to a visual or semi-quantitative analysis as it compromises sensitivity of detection of perfusion defects. This lower sensitivity is a consequence of the philosophy of the method. It should be stressed here that a high sensitivity in detection of myocardial perfusion abnormalities is one of the most important values of the SPECT myocardial perfusion study [6].

A semi-quantitative method for the assessment of perfusion images along with a properly selected threshold value of a summed stress score (SSS) aims at detection of perfusion

defects (providing sufficiently high sensitivity of the study) but at the same time, by ignoring insignificant, slight non-uniformities of tracer accumulation, should provide a reasonable study specificity. Moreover, summed stress score values determined in a reliable way provide a high prognostic value [5].

However, the present communication reveals a dependence of SSS values on the colour scale used for image display. It seems that an optimal image translation table should reveal sufficiently small details of tracer distribution. Such a scale would make physicians interpreting studies feel confident about their ability not to overlook significant perfusion defects. Long-term use of the scale consisting of white, red, yellow, green, blue, and black, which was widely applied in older computer processing systems for the display of many scintigraphic images, including myocardial perfusion studies, has made physicians interpreting images reluctant to change the colour scale. At the same time, this scale, with computer-assigned colour thresholds, seems not to show potentially significant details of tracer distribution because they seem suppressed by white and strong red colours. This is how the colour reassignment idea was born; it was a natural consequence of the dissatisfaction of physicians with this colour scale and a trial to adapt it to their needs. However, the present communication shows that although this modified scale seemed better adapted to specific needs (more details could be observed), it was in fact counter-productive because it mainly reduced study specificity. When the SSS threshold value was set to 3 or lower it caused a reduction in the study specificity to below 50%, which was unacceptable in the face of the high indices of diagnostic efficacy attainable in this material. Although an SSS threshold value of 4 provided a better study specificity (approx. 60%), this value was much lower than the specificity (about 80%) provided by GE colour with the same study sensitivity (close to 90%).

On the other hand, a French 100% colour scale provided high study sensitivity only when an SSS threshold was set to 2, a very low value, obtained, for example, when tracer uptake in two segments was scored as equivocal (score 1). In such a case, interpretation of perfusion scintigrams as abnormal caused the justified objection of physicians. This is why the authors of this communication express the opinion that the French colour scale is not optimally adapted to visual interpretation of myocardial perfusion scintigrams.

While using colour display of SPECT images one should keep in mind that colour scales consist of 3 components: red,

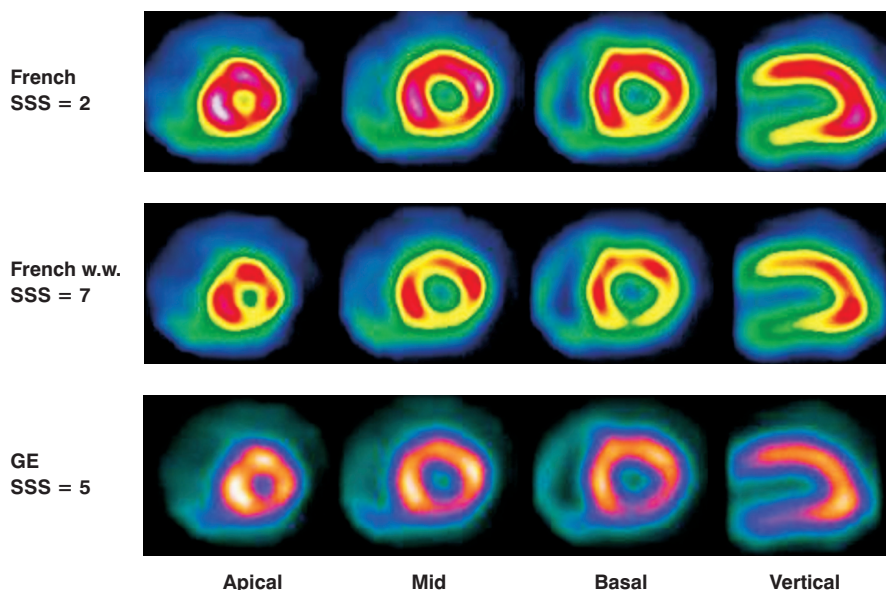


Figure 3. Three short-axis slices: basal, mid, and apical and a vertical long axis slice (in accordance with Figure 2) assessed in 3 colour scales. Additionally, values of summed stress scores for each colour scale are presented.

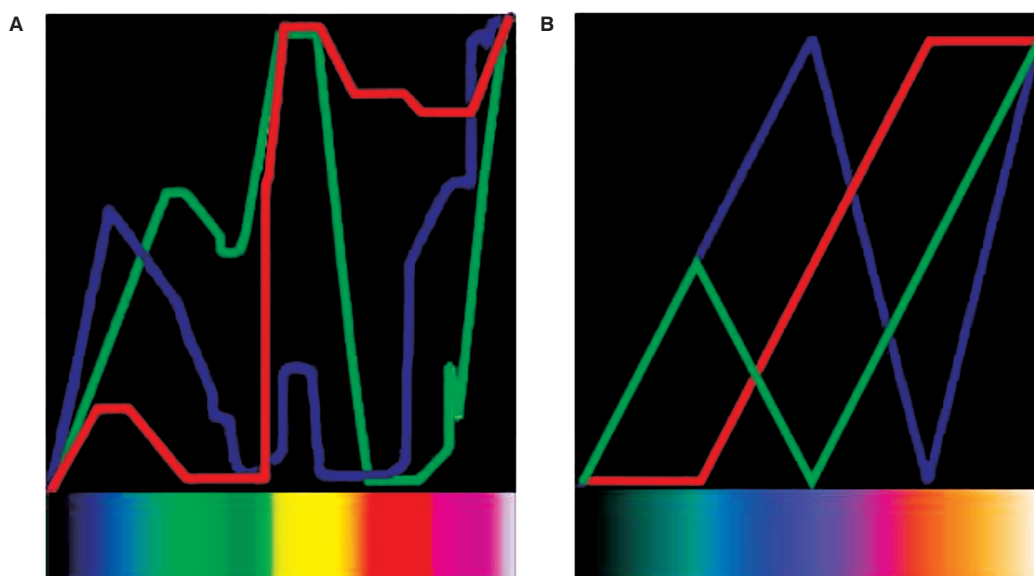


Figure 4. Red-green-blue components of colour scales applied in the study. The curves present how shares of 3 basic colour components (Y axis) change with the growing number of counts (X axis). **A.** French; **B.** GE colour.

green, and blue. Transitions between colours tend to be perceived as edges, an effect known as pseudocontouring, which can give the false perception of a significant change in counts, even when the change is minimal. This is probably where the effect of "overdetection" of perfusion defects on slices displayed in French w.w. scale has its origin. Slight nonuniformities of tracer distribution have been enhanced by pseudocontours formed by points of transition between red and yellow and also yellow and green colours. So adaptation of a French colour scale to the needs of physicians interpreting perfusion scans by elimination of white does not improve the diagnostic efficacy of the study and therefore should not be applied.

In order to reduce the negative effect of pseudocontouring on diagnostic efficacy of myocardial perfusion studies some authors use two translation tables for every image interpretation: colour and grey, e.g. Links et al. [7] and Utsunomiya et al. [8], who made use of grey and rainbow translation tables.

At present only a few communications dealing with the diagnostic impact of translation tables applied for the display of myocardial perfusion scans can be found. A work by Candell-Riera et al. [9] should be mentioned here, who compared results of clinical interpretation of studies of 150 patients using ^{99m}Tc -tetrofosmin as a radiopharmaceutical in five hospitals. Substantial differences in interpretation of studies should, in the authors' opinion,

be chiefly attributed to different formats of image display including the use of different colour scales.

Dim et al. [10] report different diagnostic efficacy of myocardial perfusion SPECT studies applying a 1-day study protocol (rest: ^{201}Tl , stress: $^{99\text{m}}\text{Tc-MIBI}$) in 30 patients verified by coronary angiography, depending on image translation table: linear grey and Cequal, as well as the experience of the physicians interpreting the images. This study showed that a colour scale showed more perfusion defects irrespective of the experience of the study interpreter.

Weinsaft et al. [11] compared the diagnostic efficacy of myocardial perfusion studies in a group of 183 patients also using a 1-day study protocol (^{201}Tl and $^{99\text{m}}\text{Tc-MIBI}$) and displaying myocardial images in two scales: linear grey and CEQUAL. They applied a semi-quantitative image assessment, and a summed stress score (SSS) of 4 or greater was considered abnormal. The prevalence of abnormal study findings was higher with grey than with colour images. When a summed stress score threshold value for grey images was adjusted upwards (SSS ≥ 5), grey and colour images provided equivalent sensitivity and specificity for global and vessel-specific coronary artery disease. This is the only communication on the necessary adjustment of the SSS threshold value to a specific translation table applied for image display that the authors of the present publication could find in available databases.

The SSS threshold value of 3 considered optimal for GE colour scale in the present study is lower than the value of 4 recommended by Berman et al. [5]. This may be a consequence of the different structure of the studied material, so this value should be verified on a larger group of patients.

Procedure guidelines for myocardial SPECT perfusion studies available at present, European [1] as well as American [2, 3], do not strongly recommend any translation table for study interpretation. The European Association of Nuclear Medicine/European Society of Cardiology document [1] advocates the use of continuous colour scales, whereas the American Society of Nuclear Cardiology prefers a linear grey scale to colour tables, but it presents the opinion that the familiarity of a reader with a given translation table is also very important. The guideline procedure of the Society of Nuclear Medicine does not touch on the question of a translation table at all. Thus, it seems that the opinion is being shared at present that there is no single correct translation table to use; rather, it is more a matter of preference and familiarity [12].

In the present study no grey scale was used because it was rejected at the beginning of the study as difficult to read. The authors acknowledge that this decision might have not been justified enough and a linear grey scale should probably have also been taken into account.

As mentioned earlier, the authors of EANM/ESC procedure guidelines stress that a translation table used for the interpretation of myocardial perfusion studies should preferably be linear. Figure 4 presents how red-green-blue components change with growing numbers of counts in two scales applied in the present study. It is clear that a GE colour scale (Figure 4b) is much more linear than a French scale (Figure 4a), and it probably explains, at least partly, its higher usefulness for interpretation of myocardial

perfusion images because a linear transition between each colour prevents pseudocontouring.

Conclusions

Two conclusions can be drawn from this study:

- a scale consisting of white, red, yellow, green, blue, and black colours, referred to in the Xeleris system (GE) as French, is not the scale of choice for the interpretation of myocardial perfusion SPECT images. It seems that a scale made up of white, yellow, violet, pink, blue, and black colours, known as GEcolor in the Xeleris system, is better suited for this purpose;
- the summed stress score threshold value accepted as a diagnostic criterion for detection of myocardial perfusion abnormalities should be suited separately for every translation table. The choice of optimal value should be verified by results of coronary angiography.

This research was done by Jakub Siennicki as a part of his PhD studies that is not correlated with his employment in GE Healthcare.

References

1. Hesse B, Tagil K, Cuocolo A et al. EANM/ESC procedural guidelines for myocardial perfusion imaging in nuclear cardiology. *Eur J Nucl Med Mol Imaging* 2005; 32: 855–897.
2. Holly TA, Abbott BG, Al-Mallah M et al. Single photon emission computed tomography. ASNC imaging guidelines for nuclear cardiology procedures. *J Nucl Cardiol* 2010; 17: 941–973.
3. Strauss HW, Miller DD, Wittry MD et al. Procedure guideline for myocardial perfusion imaging 3.3. *J Nucl Med Technol* 2008; 36: 155–161.
4. Cerqueira MD, Weissman LJ, Dilsizian V et al. Standardized myocardial segmentation and nomenclature for tomographic imaging of the heart: a statement for healthcare professionals from Cardiac Imaging Committee of the Council on Clinical Cardiology of the American Heart Association. *Circulation* 2002; 105: 539–542.
5. Berman DS, Germano G. Interpretation and reporting of gated myocardial perfusion SPECT. In: Germano GG, Berman DS (eds). *Clinical gated cardiac SPECT*. Blackwell Publishing 2006.
6. Hachamovitch R. Clinical value of combined perfusion and function imaging in the diagnosis, prognosis, and management of patients with suspected or known coronary artery disease. In: Germano GG, Berman DS (eds). *Clinical gated cardiac SPECT*. Blackwell Publishing 2006.
7. Links JM, Becker LC et al. Combined corrections for attenuation, depth-dependent blur, and motion in cardiac SPECT: A multicenter trial. *J Nucl Cardiol* 2000; 5: 414–422.
8. Utsunomiya D, Tomiguch S et al. Initial experience with X-ray CT based attenuation correction in myocardial perfusion SPECT imaging using a combined SPECT/CT system. *Ann Nucl Med* 2000; 1: 485–489.
9. Candell-Riera J, Santana-Boacio C, Bermajo B et al. Inter-hospital observer agreement in interpretation of exercise myocardial Tc-99m tetrofosmin SPECT studies. *J Nucl Cardiol* 2001; 8: 49–57.
10. Dim UR, Ngai K, Druz RS. Assessment of myocardial perfusion by novice and experienced observers: Does color make a difference? *J Nucl Cardiol* 2004; 11: S37.
11. Weinsaft JW, Gade CL, Wong FJ et al. Diagnostic impact of SPECT image display on assessment of obstructive coronary artery disease. *J Nucl Cardiol* 2007; 14: 659–668.
12. Hansen CL. The role of translation table in cardiac image display. *J Nucl Cardiol* 2006; 13: 571–575.