

The diagnosis of brain death – own experience

Otakar Kraft¹, Jiří Samlík², Jana Chmelová³

¹Department of Nuclear Medicine, University Hospital, Ostrava-Poruba, Czech Republic

²Transplantation Centre, University Hospital, Ostrava-Poruba, Czech Republic

³Radiodiagnostic Institute, University Hospital, Ostrava-Poruba, Czech Republic

[Received 18 VIII 2006; Accepted 30 X 2006]

Abstract

BACKGROUND: The aim of this paper is a description of our experience with scintigraphic detection of brain death.

MATERIAL AND METHODS: Thirty-four patients were studied from February 2003 to June 2006. We performed brain scintigraphic examination utilising ^{99m}Tc-HMPAO and a two-headed SPECT camera E.CAM. We used LEHR collimators. 15% energy window was centred around 140 keV. 650–750 MBq of radiopharmaceutical was injected as a bolus. Then dynamic scintigraphy of the head and neck was done in an anterior projection — 2 s per frame for 60 s. Then static scintigraphy of the head in four projections followed (anterior, both lateral and posterior views), for 4 minutes per view.

RESULTS: A typical picture of brain death on planar dynamic and static scintigrams showed an absence of perfusion and radiopharmaceutical accumulation in both cerebral and cerebral hemispheres and brain stem. Radioactivity in the area of the scalp and face could be present. Borderline findings, which demanded careful interpretation, were the cases with preservation of minimal cerebral perfusion and simultaneous absence of radiopharmaceutical accumulation in its parenchyma and cut-off of tracer accumulation in cerebral parenchyma only supra- or infratentorial.

Correspondence to: Otakar Kraft
Department of Nuclear Medicine, University Hospital
17. listopadu 1790, 708 52 Ostrava-Poruba, Czech Republic
Tel: (+42) 0597 372 290, fax: (+42) 0596 919 156
e-mail: otakar.kraft@fnspo.cz

CONCLUSIONS: Cerebral perfusion scintigraphy is the most contributing factor for the diagnosis of brain death in patients after cranial trauma with subsequent neurosurgical operation, when angiography is often unsuitable. In these situations perfusion scintigraphy is able to show the absence of radiopharmaceutical accumulation in cerebral tissue. Scintigraphic detection of brain death gained an important role in new Czech legislation, and the demands of transplant centres for these examinations will certainly grow with the accrual of organ collections.

Key words: brain death, brain scintigraphy, cerebral angiography, organ transplantation, organ donor

Introduction

Before organ transplantation from dead donors it is necessary to determine irreversible brain changes and brain death. Brain scintigraphy plays an important role in this.

Material and methods

Thirty-four patients (age range 3–65 yrs; average age 37.6 yrs; 22 men and 12 women) were studied from February 2003 to June 2006 (patients' data are given in Tables 1 and 2).

The method of scintigraphic procedure is based on the guidelines of the Board of the Czech Society of Nuclear Medicine [1, 2].

We performed this study utilising the ^{99m}Tc-hexamethyl-propylene-amine-oxime (HMPAO) (BRAIN-SPECT, „Fodor József” National Centre of Public Health, „Frédéric Joliot-Curie” National Research Institute for Radiobiology and Radiohygiene, Budapest, Hungary), for its very easy preparation and quick and easy determination of radiochemical purity. We could perform the cerebral perfusion scintigraphy on any day of the week. The radiopharmaceutical was prepared exactly according to the producer's instructions and in the time specified by the producer. We carried out quality control of labelling and stability of the compound and radiochemistry purity before the injection of radiopharmaceutical. Assessment of radiochemical purity of ^{99m}Tc-hexamethyl-propylene-amine-oxime: into a test tube with 3.0 ml chloroform and 2.9 ml 0.9% solution of sodium chlorate we added 0.1 ml of prepared ^{99m}Tc-HMPAO which we shook intensively for 1 minute. We left the test tube at rest for 1-2 minutes to facilitate phase separation. Then we completely transferred one of the phases to the

Table 1. Classification of patients: sex, age, conditions, surgery

Pts no.	Sex	Age	Conditions	Surgery
1	M	9	Spontaneous cerebral haemorrhage	YES
2	M	52	Cranial injury	YES
3	M	10	Multiple injury, cranial injury	NO
4	M	30	Cranial injury, subdural haematoma	NO
5	M	38	Subdural haematoma, brain oedema	YES
6	M	37	Cranial injury, brain contusion, brain oedema	NO
7	M	52	Subdural haematoma, brain oedema	YES
8	F	61	Spontaneous cerebral haemorrhage	YES
9	M	50	Cerebral haemorrhage	YES
10	M	20	Cranio-cerebral injury	YES
11	F	26	Cerebral haemorrhage, AV malformation	YES
12	M	10	Multiple injury, cranial injury	YES
13	M	36	Cranial injury in ebrietas	YES
14	F	51	Spontaneous cerebral haemorrhage	YES
15	M	18	Spontaneous cerebral haemorrhage	YES
16	F	52	Spontaneous cerebral haemorrhage	YES
17	M	40	Spontaneous cerebral haemorrhage	YES
18	F	11	Malignant brain edema in obstructive hydrocephalus	YES
19	M	47	Cranial injury in ebrietas	YES
20	F	61	Malignant brain edema after cerebral ischemia	YES
21	F	36	Status after astrocytoma extirpation, brain edema	NO
22	M	24	Cranial injury in epileptic paroxysm	YES
23	M	14	Cranial injury, malignant brain edema, hemocephalus	NO
24	F	39	Subarachnoidal haemorrhage, malignant brain edema	YES
25	F	47	Subarachnoidal haemorrhage, malignant brain edema	YES
26	M	55	Cranial injury, subdural haemorrhage	YES
27	F	43	Cranial injury, subdural haemorrhage, brain edema	YES
28	M	47	Brain contusion, malignant brain edema	YES
29	M	3	Malignant brain edema after operation	NO
30	F	39	Cranial injury	YES
31	M	65	Intracranial haemorrhage	YES
32	M	46	Brain contusion, subdural and epidural haemorrhage, brain oedema	YES
33	F	59	Brain aneurysm rupture	YES
34	M	52	Cranial injury, subdural haemorrhage	YES

M — man; F — female

second tube. We measured the activity of both test tubes (both phases). A lipophilic complex of ^{99m}Tc -HM-PAO was located in the chloroform phase and contaminants in the solution of sodium chloride. The result was expressed as a percentage of radiochemical purity. The radiopharmaceutical could be used for 2 hours after preparation, and minimal acceptable radiochemistry purity is 80%. We performed brain scintigraphy utilising the two-headed SPECT camera E.CAM (Siemens, Erlangen, Germany). We used LEHR collimators. A 15% energy window was centred around 140 keV.

650–750 MBq of radiopharmaceutical was injected as a bolus. Then dynamic scintigraphy of the head and neck was performed in anterior projection — 2 s per frame for 60 s (matrix 64 × 64, zoom 1.0). Then static scintigraphy of the head in four projec-

Table 2. Classification of parents: type of organ withdrawal

Pts no.	Organ withdrawal
1	Kidneys and heart
2	Kidneys
3	Kidneys, heart, lungs, liver
4	Heart, kidneys, pancreas
5	Kidneys, heart, liver
6	Kidneys and heart
7	Kidneys
8	Kidneys
9	Kidneys
10	Kidneys and heart
11	Kidneys, heart, lungs, liver
12	Kidneys and heart
13	Kidneys, heart, liver
14	Kidneys
15	Kidneys, heart, pancreas, liver
16	Kidneys
17	Kidneys and heart
18	Heart, lungs, liver, pancreas, kidneys
19	Kidneys
20	Kidneys
21	Multiple organ withdrawal
22	Multiple organ withdrawal
23	Multiple organ withdrawal
24	Multiple organ withdrawal
25	Multiple organ withdrawal
26	Multiple organ withdrawal
27	Multiple organ withdrawal
28	Withdrawal contraindicated — positive serology for syphilis
29	Withdrawal was not performed
30	Multiple organ withdrawal
31	Kidneys
32	Multiple organ withdrawal
33	Multiple organ withdrawal
34	Multiple organ withdrawal

tions followed (in anterior, both lateral and posterior views) for 4 minutes per view (matrix 128 × 128, zoom 1.0).

We evaluated the scintigraphic images as follows: typical picture of brain death on dynamic scintigrams as the absence of perfusion and on planar static scintigrams the absence of radiopharmaceutical accumulation in both cerebral and cerebellar hemispheres and brain stem, absence of internal carotid circulation and the circle of Willis circulation. Radioactivity in the area of scalp and face can be present. Borderline findings which demanded careful interpretation were included cases with preservation of minimal cerebral perfusion and simultaneous absence of radiopharmaceutical accumulation in its parenchyma. The mere presence of sagittal venous sinus in the absence of demonstrable cerebral arterial flow activity is not clinically significant and does not contradict the diagnosis of brain death [3].

Results

We performed this examination on 34 patients as possible organ donors; in all of them we established brain death.

In Figures 1A, 1B and 2 we show the dynamic and static scintigrams of a patient (woman aged 47 yrs) with subarachnoid haemor-

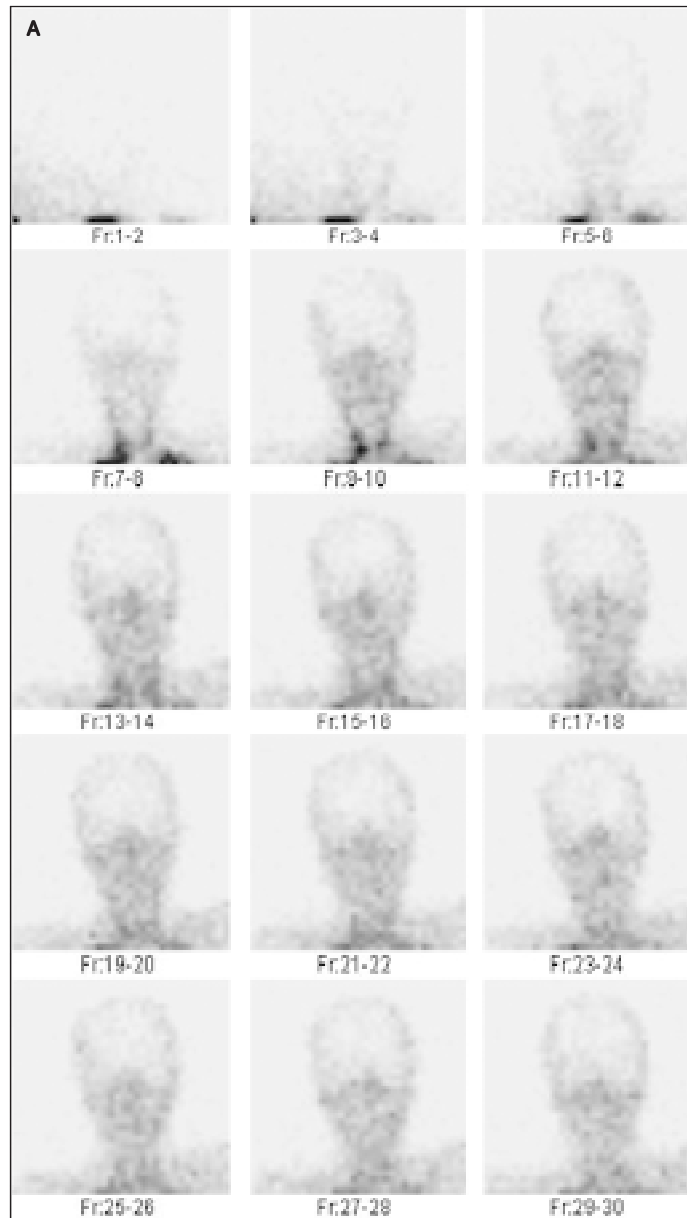


Figure 1.A.B. Dynamic brain scintigraphy in a 47 yr old woman with subarachnoidal haemorrhage, malignant brain oedema and after bilateral neurosurgery (anterior projection, acquisition 60 seconds, 30 frames, 2 seconds per frame). No brain perfusion.

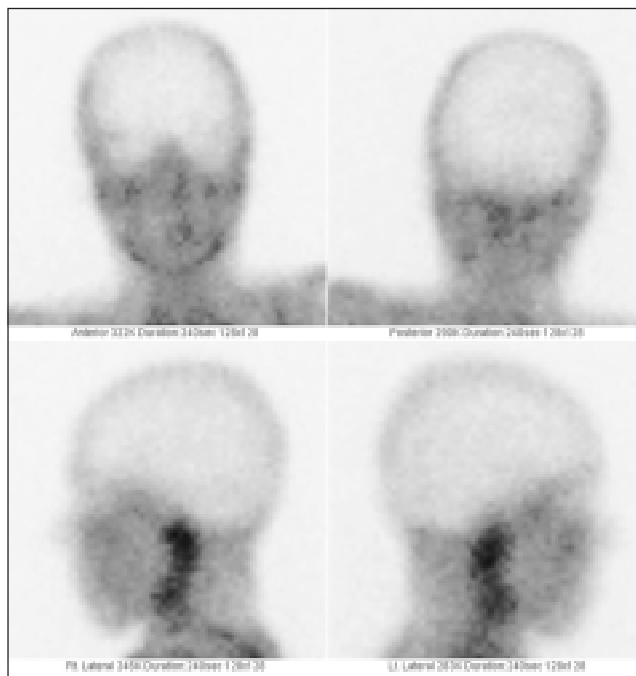


Figure 2. Static brain scintigraphy in the same patient as in Figures 1a and 1b (anterior, posterior and both lateral projections, 4 minutes per frame; anterior and posterior projections are done simultaneously, both lateral projections are also performed simultaneously). No brain perfusion.

rhage and malignant brain oedema after bilateral neurosurgery (bilateral external decompression surgery). No radiopharmaceutical accumulation in either cerebral and cerebellar hemisphere or brain stem is visible (sign of so-called "hollow skull"). On the basis of scintigraphic results, brain death was established. For comparison we have also shown dynamic and static scintigrams taken before brain SPECT in a patient (man aged 47 yrs) examined after a stroke (Figure 3A, 3B and Figure 4A, 4B). Normal cerebral perfusion is evident.

Discussion

In the majority of European countries recommendations have been published for the diagnosis of brain death as a necessary prerequisite for organ donation. The concept of brain death as defining the death of the individual is accepted in all European countries; however, the guidelines for determining the total and irreversible loss of all brain function differ somewhat in the various countries. While the clinical examinations and documentation of the clinical signs of brain death are very uniform, there are significant differences in the guidelines for using technical confirmatory tests to corroborate the clinical signs [4]. For example, in Croatia, the Czech Republic, Slovenia and Switzerland brain scintigraphy is mandatory or accepted as one of the ancillary methods. In Austria neurological examination, MRI or angiography is crucial, in Sweden neurological examination and angiography, in Finland CT, MRI angiography and rtg angiography, in Turkey EEG and clinical examination, sometimes angiography; scintigraphy not mandatory and in Slovakia neurology and angiography.

A common indication of brain death scintigraphy is to assess brain blood flow in patients suspected of brain death.

Our University Hospital has developed clinical guidelines and procedures for clinical diagnosis, including performing scintigraphy for assessing possible brain death. These guidelines include repeated neurological examinations with a special focus on the absence of brain stem reflexes (the minimum time between first and second neurological examinations is 4 hours) [5]. These guidelines also include ancillary tests such as perfusion scintigraphy and angiography.

According the Czech government enactment number 436/2002 and the so-called Czech Transplantation Act number 285/2002 it is necessary to perform cerebral angiography or cerebral perfusion scintigraphy (in the department of nuclear medicine) for the verification of the irreversibility of clinical signs of brain death.

Angiographic detection of brain death is based on the supposition that upon brain death accrual of brain oedema with subsequent increase of intracranial pressure, which eventually exceeds systolic pressure (critical closing pressure), gradually leads to failure of cerebral circulation. This is why it is requested that cerebral angiography (and also brain scintigraphy) be performed (and also brain scintigraphy) at a mean pressure of 60–80 mm Hg to exclude the situation in which cessation of cerebral circulation will be induced by the low systolic (perfusion) pressure.

Cerebral angiography is performed as digital subtraction angiography (DSA) by a certified radiologist utilising a minimum volume of 30 ml Omnipaque.

Validation of brain death is confirmation of brain circulation cessation. In patients with some types of cranial injuries or after craniectomy, cerebral blood flow can be partially preserved. In such cases, penetration of Omnipaque to some cerebral arteries does not exclude brain death, and in these patients brain death cannot be confirmed.

In these situations brain scintigraphy plays the main role.

The method of scintigraphic procedure is based on the guidelines of the board of the Czech Society of Nuclear Medicine which was inspired by the Society of Nuclear Medicine (SNM) Procedure Guidelines for Brain Death Scintigraphy [6].

To meet the criteria for whole-brain death, perfusion must be absent in the whole brain, both cerebrum and cerebellum [7]. We agree with Spieth et al. [7, 8] that without the use of agents trapped in brain tissue for a relatively long time, accurate evaluation of brain perfusion is not possible. At this time HMPAO and Neurolite are the only available technetium-labelled agents able to meet the strict criteria for the clinical confirmation of whole-brain death [8, 9]. After the application of the radiopharmaceutical its accumulation is proportional to the regional perfusion of the brain, and confirms cell viability. The absence of radiopharmaceutical accumulation in brain tissue detected by scintigraphy confirms brain death. In static scintigraphy it is important to perform anterior, both lateral and posterior projections [7]. The examination in our department is done by physicians with nuclear medicine attestation.

We perform qualitative visual assessment of the presence or absence of delayed ^{99m}Tc -HMPAO deposition in the brain.

After dynamic and static scintigraphy it is possible to supplement by SPECT examination [10, 11]. It is also possible to perform some semi-quantitative evaluation (for example to calculate blood flow index, i.e. the ratio of the area under the brain time-activity curve vs that under the curve for the carotid arteries; and delayed uptake index, i.e. the ratio of ^{99m}Tc -HMPAO deposition in




Figure 3.A.B. Dynamic brain scintigraphy in a 47 yr old man after stroke (anterior projection, acquisition 60 seconds, 30 frames, 2 seconds per frame). Normal brain perfusion is visible.

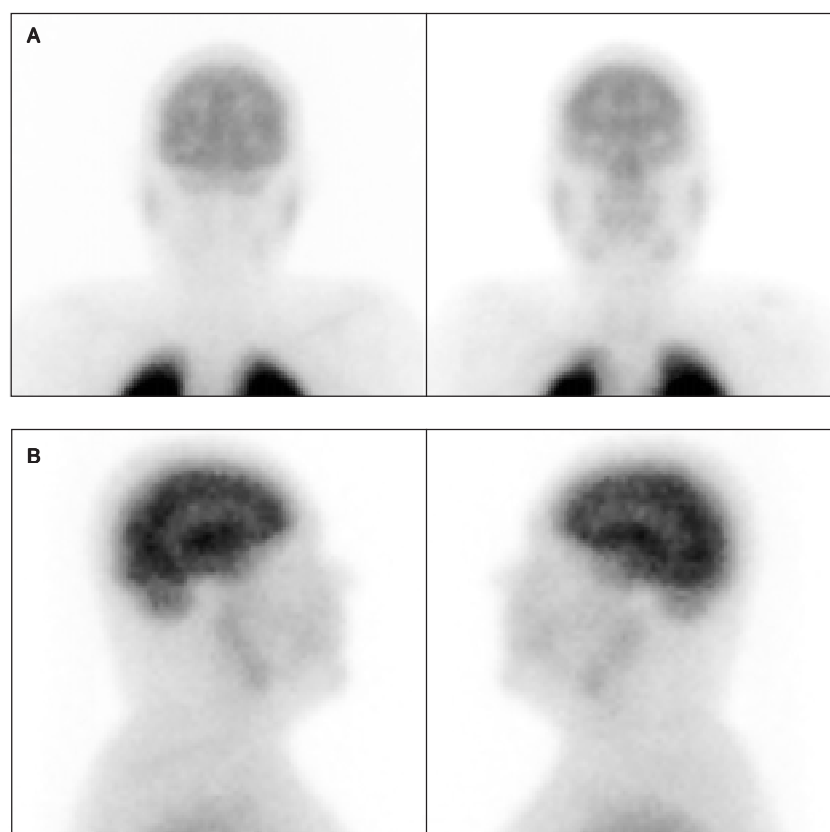


Figure 4.A.B. Static brain scintigraphy in the same patient as in Figure 3AB (Figure 4A — anterior and posterior projections; Figure 4B — both lateral projections; 4 minutes per frame; anterior and posterior projections are carried out simultaneously, both lateral projections are also performed simultaneously. Normal brain perfusion is visible.

the brain vs. that in the facial regions of interest) [12]. But we believe that tomographic scintigraphy and some calculations are not necessary. In our 34 patients brain death was determined without problem by means of static and dynamic scintigraphy, without SPECT and without any calculation.

Conclusions

Cerebral perfusion scintigraphy is the greatest contribution in the diagnosis of brain death in patients after cranial trauma with subsequent neurosurgery intervention, when (according to the experience of our radiologists) angiography is often unsuitable (for long-term filling of cerebral arteries). In these situations perfusion scintigraphy is able to show the absence of radiopharmaceutical accumulation in cerebral tissue.

In a limited number of uncertain findings in perfusion scintigrams, nuclear medicine physicians must not confirm the absence of tracer accumulation in the brain by its own signature (in Czech government enactment number 436/2002).

Brain scintigraphy is a simple and reliable method for this purpose.

Scintigraphic detection of brain death has gained an important role in the new Czech legislation, and the demands of transplant centres for these examinations will certainly grow markedly with the accrual of organ collections.

References

1. Kraft O, Samlík J, Skotnicová S. Problems of the detection of brain death. Abstracts of the 6th Congress of the Czech Transplantation Society, Prague 14–16.10.2004: 20 (abstract).
2. Vižďa J, Urbanová E, Doležal J. Perfusion brain scintigraphy — possibility of detection of brain death. Abstracts of the 6th Congress of the Czech Transplantation Society, Prague 14–16.10.2004: 19–20 (abstract).
3. Lee VW, Hauck RM, Morrison MC. Scintigraphic evaluation of brain death: significance of sagittal sinus visualization. *J Nucl Med* 1987; 28: 1279–1283.
4. Haupt WF, Rudolf J. European brain death codes: a comparison of national guidelines. *J Neurol* 1999; 246: 432–437.
5. Flowers WM, Patel BR. Accuracy of clinical evaluation in the determination of brain death. *South Med J* 2000; 93: 203–206.
6. Donohoe KJ, Frey KA, Gerbaudo VH et al. Procedure guideline for brain death scintigraphy. *J Nucl Med* 2003; 44: 846–851.
7. Spieth M, Abella E, Sutter C et al. Importance of the lateral view in the evaluation of suspected brain death. *Clin Nucl Med* 1995; 20: 965–968.
8. Spieth ME, Ansari AN, Kawada TK. Direct comparison of Tc-99m DTPA and Tc-99m HMPAO for the evaluation of brain death. *Clin Nucl Med* 1994; 19: 867–872.
9. Spieth ME, Devadas GC, Gauger BS. Procedure guidelines for brain death scintigraphy. *J Nucl Med* 2004; 45: 922.
10. Bonetti MG, Ciritella P, Valle G et al. 99mTc HM-PAO brain perfusion SPECT in brain death. *Neuroradiology* 1995; 37: 365–369.
11. Facco E, Zucchetto P, Munari M et al. 99mTc-HMPAO SPECT in the diagnosis of brain death. *Intensive Care Med* 1998; 24: 911–917.
12. Mrhac L, Zakko S, Parikh Y. Brain death: the evaluation of semi-quantitative parameters and other signs in HMPAO scintigraphy. *Nucl Med Commun* 1995; 16: 1016–1020.