

Use of lung and brain perfusion imaging in the HELLP syndrome

John R. Buscombe, Piotr Lass¹, Andrew J.W. Hilson

Department of Nuclear Medicine, Royal Free Hospital and School of Medicine, London, NW3 2QG, UK

¹Department of Nuclear Medicine, Medical University of Gdańsk, Gdańsk, Poland

Abstract

Patients with multi-organ disorders may present with a plethora of confusing symptoms and signs. Often early diagnosis of significant disease is essential and can be difficult with standard radiological techniques. This case report presents the use of two radioisotopic techniques to assess brain and lung perfusion in a patient with such an acute-multi-organ disorder - the HELLP syndrome.

Key words: Tc-99m HMPAO, brain perfusion, ventilation perfusion lung scintigraphy, HELLP syndrome

Introduction

Brain perfusion imaging using Tc-99m hexamethylpropyleneamine-oxine (HMPAO) has been used in a variety of clinical conditions (1-3). It is of particular use when infarcts are small and may be missed on X-ray computed tomography (CT). Such diffuse micro vascular disease may be seen in patients with multi-infarct dementia (4) but is rarely seen in younger people unless they have an underlying cause for microangiopathy. In some cases this may be combined with a syndrome which results in widespread emboli. Such a condition, normally occurring at the end of first pregnancy, is the recently described Haemolysis-Elevated Liver enzyme-Low Platelet count (HELLP) syndrome (5). In this, we demonstrate the use of radioisotopic techniques to investigate both micro-angiopathic infarcts in the brain and major vessel emboli in the lungs using standard lung and brain perfusion imaging methods.

Case report

31-year-old white Caucasian patient with an initial clinical diagnosis of system lupus erythematosus presented aged 31 when preg-

nant (first trimester) with left calf tenderness. This was found on contrast venography to be secondary to a deep venous thrombosis and the patient treated with heparin. Following pregnancy the patient was given Warfarin and remained anti-coagulated. However her requirement for Warfarin continued to rise over the subsequent 12 months.

An auto-antibody screen was performed which showed a positive anti-DNA antibody titre at a titre of greater than 100. There were no double-stranded DNA antibodies though anticardiolipin antibody titre was greater than 1 in 120 rising to a titre of 1 in 274 over 12 months.

A family history revealed a maternal great aunt who had died of pulmonary embolism during pregnancy and a female maternal cousin who had also presented with a deep venous thrombosis during pregnancy.

At the end of her pregnancy the patient's blood pressure began to rise and she appeared to be developing pre-eclampsia. Delivery was induced and four days after being delivered of a healthy infant, the patient suffered a series of epileptiform convulsions. An MRI was performed but this was unremarkable, however a Tc-99m HMPAO study (Figure 1) was performed which showed multiple defects in perfusion throughout the cerebral hemispheres consistent with multiple small infarcts.

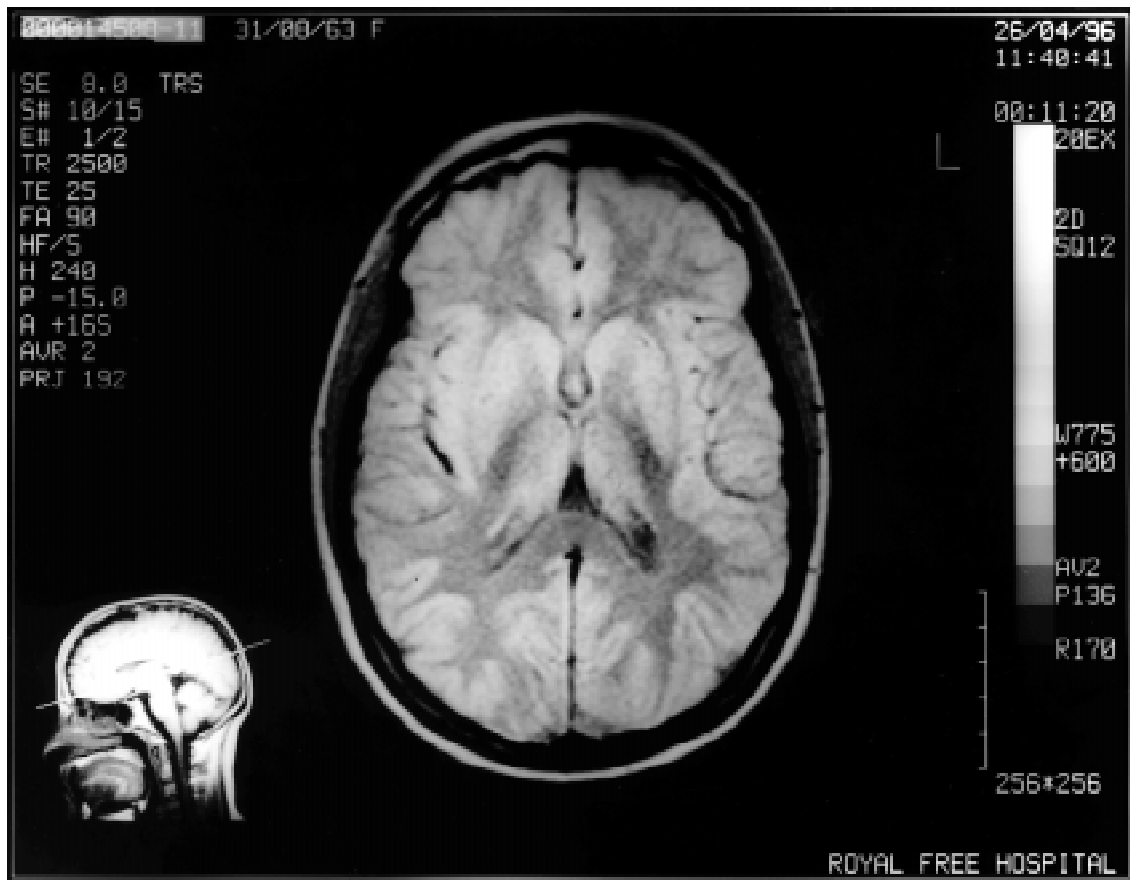
Her circulating platelet count began to fall, and she developed both liver and renal impairment consistent with a HELLP syndrome. To reduce the level of anti-cardiolipin antibodies plasma exchange was initiated, but during treatment the patient developed chest pain and dyspnoea. Ventilation/perfusion lung scanning revealed multiple perfusion defects on the Tc-99m MAA scan but a normal Kr-81m ventilation scan consistent with multiple pulmonary emboli (Figure 2).

Discussion

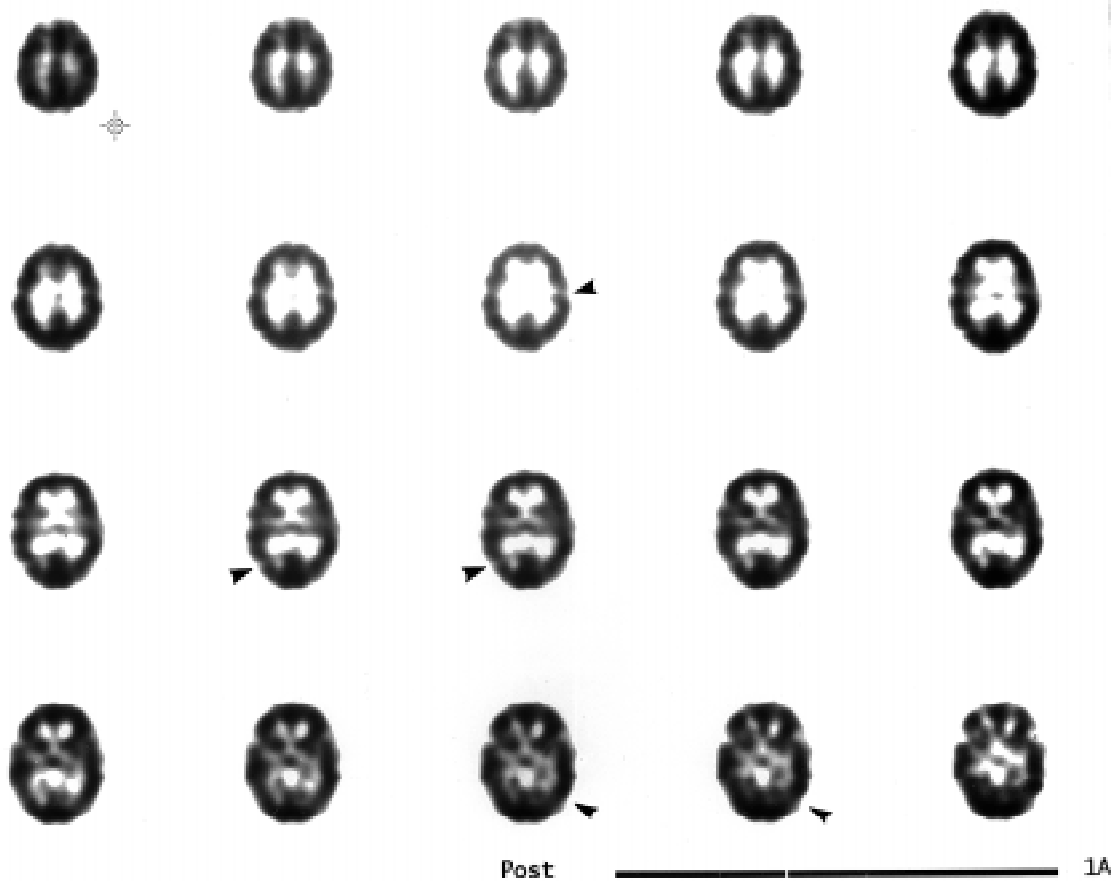
This case illustrates the flexibility of nuclear medicine techniques in being able to identify different sites of vascular occlusion. Tc-99m HMPAO brain perfusion SPECT can be used to identify the small infarcts which occur within the brains of patients with HELLP syndrome -the use of anatomical methodologies such as CT has been described (6). However in our patient, defects consistent with multiple small brain infarcts were only seen on Tc-99m HMPAO imaging but not with MRI.

The condition itself is rare and affects about 1 in 15,000 live births, it is less common in Caucasians than other racial groups

Correspondence to: Dr J.R. Buscombe
Department of Nuclear Medicine, Royal Free Hospital,
Pond Street, London NW3 2QG
Tel/fax: (+44 171) 8302469



A



B

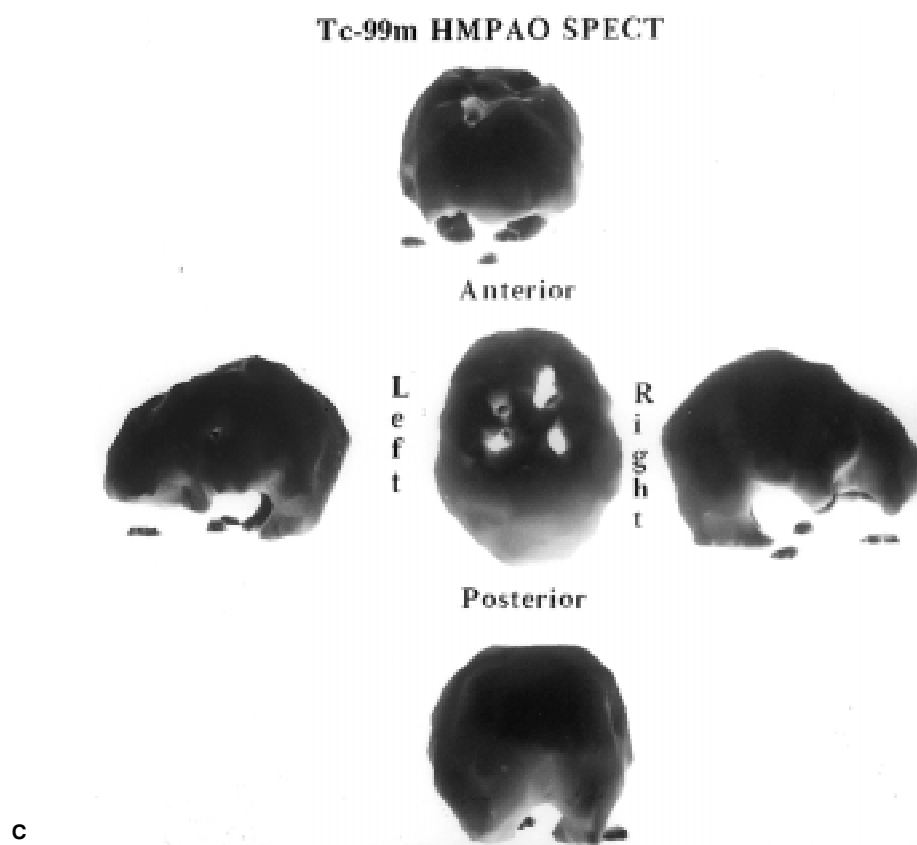


Figure 1. With brain imaging the normal MRI (Figure 1a) contrasts with the small defects seen in the cortex on Tc-99m HMPAO brain perfusion SPECT displayed as transaxial slices (Figure 1b) and as a 3D surface rendered image (Figure 1c).

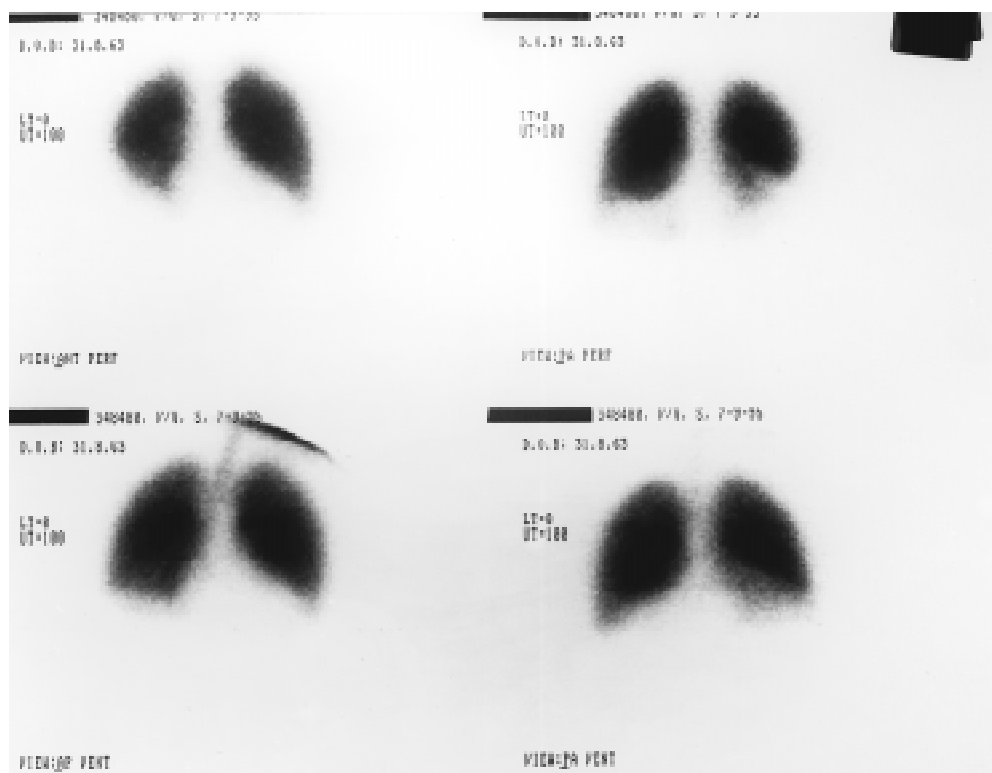


Figure 2. Tc-99m MAA and Kr-81m lung scintigraphy showing a significant ventilation/perfusion mismatch in the right lung base (ventilation films marked „vent” and perfusion films marked „pert”, anterior images are in upper row and posterior images in the lower row).

(7). Treatment in these patients often proves difficult with repeated emboli occurring (8). As in the patient reported here, there is evidence of a familial predisposition to the HELLP syndrome with either the frank syndrome appearing within families or other family members having a history of multiple emboli. At present it is unclear whether this family link operates through the expression of anti-phospholipid antibodies or the anti-cardiolipin antibodies present in our patient (9).

As this condition is a multi-organ disorder it is surprising that there have not been other reports of the use of imaging. The only reported use of nuclear medicine has been to assess the degree of hepatic impairment using hepatobiliary scintigraphy and Tc-99m sulphur colloid imaging (10–11).

The distinct features of this case are not only the first reported use of both Tc-99m HMPAO and radionuclide ventilation perfusion lung imaging in a patient with the HELLP syndrome but also to emphasise the enhanced sensitivity and versatility of radionuclide techniques in patients such as this who have acute multi-organ disease.

References

1. Sharp PF, Smith FW, Gemmell HG. Tc-99m HMPAO stereoisomers as potential agents for imaging cerebral blood flow: human volunteer studies. *J Nucl Med* 1986; 21: 171–177.
2. Ell PJ. Mapping cerebral blood flow. *J Nucl Med* 1992; 33: 1843–1845.
3. Ell PJ, Jarritt PH, Costa DC, Cullum ID, Lui D. Functional imaging of the brain. *Semin Nucl Med* 17: 214–229.
4. Gemmell HG, Sharp PF, Besson JA, et al. Differential diagnosis in dementia using the cerebral blood flow agent Tc-99m HM-POA: a SPECT study. *J Comput Assist Tomogr* 1997; 11: 398–402.
5. Weinstein L. Syndrome of hemolysis, elevated liver enzymes, and low platelets: A severe consequence of hypertension in pregnancy. *Am J Obstet Gynecol* 1982; 142: 159–167.
6. Stefanowicz M, Lipinska J, Stefanowicz E, Malarkewicz CJ. Zmiany w tkance mózgowej w przebytym zespole HELLP potwierdzone badaniem CT. *Ginekologia Polska* 1995; 66: 185–187.
7. Sebban E, Benfila JL, Pennehowat G, et al. Predisposition ethnique du HELLP syndrome. Etude retrospective de 12 cas d'ont 5 serveres en post partum. *J de Gynecologie, Obstetrics et Biologique de la Reproduction* 1994; 23: 181–187.
8. Omstein MH, Rand JH. An association between refractory HELLP syndrome and anti-phospholipid antibodies during pregnancy, a report of 2 cases. *J Rheumatol* 1994; 21: 1360–1361.
9. Berti P, Contino L, Presondo P, et al. Is the HELLP syndrome due to inherited factors? Report of two cases. *Haematologica* 1994; 79: 170–172.
10. Rosen JM, Luhman KC, Tank RA. Hepatobiliary scintigraphy in the evaluation of preeclampsia and HELLP syndrome. *Clin Nucl Med* 1994; 19: 740–741.
11. Davidson RM, Barron BJ, White PA, et al. Diagnosis by radiocolloid imaging of post partum hepatic necrosis in the syndrome of hemolysis, elevated liver enzymes, and low platelets. *Clin Nucl Med* 1992; 17: 322–324.