

Recombinant human TSH in the diagnosis and treatment of disseminated differentiated thyroid cancer

Barbara Jarzab, Daria Handkiewicz-Junak,
Marzena Gawkowska-Suwińska

Centre of Oncology, Maria Skłodowska-Curie Memorial Institute, Nuclear
Medicine and Endocrine Oncology Department, Gliwice, Poland

Radioiodine diagnosis of disseminated recurrent thyroid cancer and radioiodine treatment are in most cases unachievable without stimulation of cancer cells by thyrotropin (TSH) (1, 2, 3). TSH stimulation is needed for nearly all functions of the thyroid cell, particularly for its hormonal activity, but also for its proliferation (3, 4, 5). The thyroid-specific functions are dependent on the expression of thyroid-specific genes, such as sodium iodide symporter, thyroperoxidase, thyroglobulin or the TSH receptor gene (6). The expression of these genes is reduced in differentiated thyroid cancer (DTC) to a variable extent, and this results in an impairment of the functions of cancer cells (6, 7). The effect may be detected already on the clinical level, because iodine trapping by cancer cells is much less efficient in comparison to normal follicular cells. Thus, preoperatively, a malignant tumour of the thyroid is seen mostly as a cold lesion on the scintigram. Post surgery, when the thyroid gland is removed and the remnants are destroyed by ^{131}I ablation, the ^{131}I uptake becomes visible, which enables the early detection of cancer spread and indicates ^{131}I therapy (8).

Stimulation with TSH is able to increase iodine uptake and organification in thyroid cancer cells (Figure 1) (5, 9, 10, 11). This is important for the visualisation of cancer foci on a radioiodine scan, and is also essential for the improvement of the sensitivity of thyroglobulin testing (12, 13, 14). The rise in endogenous TSH, achieved by a 4–6 week thyroxine withdrawal, is most often used to reach this goal. However, this is connected with symptomatic hypothyroidism (Table 1) (9, 14, 15). The introduction of recombinant human TSH (rhTSH) (16, 17, 18, 19) has created a chance to

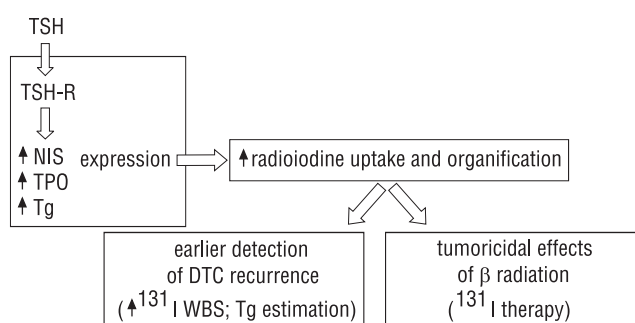


Figure 1. TSH impact on radioiodine uptake.

perform both therapy and follow-up without pauses in thyroxine administration (3, 20). The diagnostic use of rhTSH in thyroid cancer patients has already been approved on the basis of extensive multi-centre studies carried out in the last few years (9, 10, 21). The second phase III clinical study showed that results of endo- and exogenous TSH stimulation were quite comparable on iodine scans (10). Circa 89% of scans performed while on rhTSH gave identical results as compared to the routine thyroxine withdrawal procedure. Even when only positive scans were compared, about 75% were concordant, and in some cases, recombinant TSH was more effective.

Table 1. Incidence of hypothyroidism symptom during thyroxine withdrawal (modified according to Billewicz)

Frequency range	Symptoms
> 50%	Periorbital swelling Slow movements Cold intolerance Weight increase
20–50%	Slowing of the ankle jerk reflex Decrease in heart rate Constipation Hoarseness Dry skin
< 20%	Diminished sweating Paraesthesia Rough skin Deafness

Correspondence to: Barbara Jarzab
Wybrzeże Armii Krajowej 15, 44–100 Gliwice, Poland
Tel: (+48 32) 2789301, fax: (+48 32) 2311512
e-mail: bjarzab@onkol.gliwice.pl

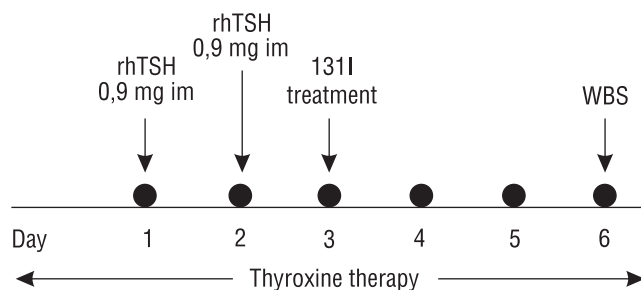


Figure 2. rhTSH administration schedule before ¹³¹I therapy.

The accepted procedure consisted of repeated intramuscular injections of 0.9 mg rhTSH for two consecutive days and ¹³¹I administration on day 3, with whole body scans (WBS) performed 48h after radioiodine administration (Figure 2). Due to the lower iodine renal clearance during thyroxine withdrawal-induced hypothyroidism, the activity of ¹³¹I given was doubled from 2 to 4 mCi during rhTSH aided diagnostics.

According to the published results of multi-centre studies (9, 10, 21) only minor and negligible side effects were observed during diagnostic rhTSH use. Their rare occurrence was in striking contrast to the frequent symptoms of hypothyroidism, seen after thyroxine withdrawal in the same patients (14, 15) (Table 1). Although those symptoms do not belong to the life-threatening category and do regress after reintroduction of thyroxine, the quality of life is lowered significantly during the hypothyroid phase. The major loss was seen in physical and emotional roles as estimated on the basis of psychological tests (15, 22).

When we compare the serum TSH rises induced by rhTSH and thyroxine withdrawal, the first is more distinct but shorter – the two im injections result in a 5–6 day long increase (Figure 3). Although rhTSH is able to stimulate the ¹³¹I uptake very efficiently, circa 8–15% of scans performed under rhTSH yield poorer results in comparison to thyroxine withdrawal (9, 10). This problem may be solved by a concomitant estimation of the thyroglobulin (Tg) serum level (10). When a Tg rise is observed after rhTSH stimulation but the ¹³¹I WBS is negative, a repeated diagnostic after thyroxine withdrawal should be performed in order not to miss distant metastases. In the second phase III study the joined analysis of rhTSH-stimulated ¹³¹I whole body scans and thyroglobulin se-

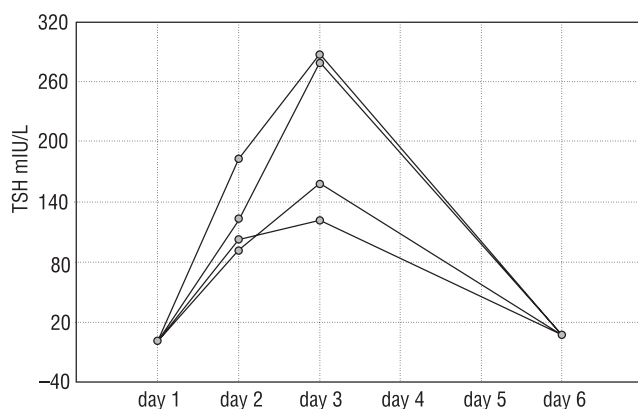


Figure 3. Serum TSH after exogenous rhTSH application.

rum levels yielded 100% sensitivity in the detection of hidden cancer foci and 93% sensitivity in patients with disease or tissue limited to the thyroid bed (10). However, the specificity of the rhTSH-stimulated Tg estimation has not yet been determined. It is obvious that different cut-off levels should be applied for Tg estimations under rhTSH, as this stimulation results in a weaker Tg response than thyroxine withdrawal (10, 23, 24).

The therapeutic use of recombinant human TSH has not yet been approved and intensive multi-centre studies are currently being conducted. In this paper we would like to analyse the reports published until now (25–27) and our own experience with rhTSH used during therapy of disseminated thyroid carcinoma (23, 24), mainly in the context of the priority of indications for rhTSH aided treatment.

The therapeutic use of radioiodine in cancer disease implies that after radioiodine administration a sufficient quantity of radioisotope will be concentrated providing the tumoricidal dose of beta radiation energy (28, 29). Thus, TSH is needed not only for stimulation of iodine trapping but also for its longer retention by thyroid cancer cells. The clinical advantages of the use of recombinant hTSH in the radioiodine therapy are quite clear, as the risk of hypothyroidism may be omitted (9, 10, 20). However, it is necessary to document that the transient stimulation with exogenous TSH is sufficient to accumulate ¹³¹I long enough to obtain the regression of cancer disease and the complete ablation of thyroid remnants. Only when this is proved, will rhTSH aided ¹³¹I therapy be indicated for all DTC patients. The realisation of this ideal goal will probably take a long time, because of both logistic and financial reasons. So, we have to analyse and evaluate the most important, unquestionable indications for recombinant TSH application.

The main indications for rhTSH aided iodine therapy are summarised in Table 2. It is clear that recombinant TSH is to be applied in patients, in whom it is impossible to achieve stimulation with endogenous hormone. Obviously, pituitary insufficiency with secondary hypothyroidism in a patient with differentiated thyroid cancer requiring ¹³¹I therapy is a classical indication for recombinant human TSH administration (30–32). However, these are both rare diseases and only a few patients suffer simultaneously from each of them. The published casuistic results clearly show that the use of recombinant TSH increases the target to background ratio very well in these cases. Most of them concern patients with DTC metastases destroying the pituitary gland (26, 32, 33).

The most frequent clinical situation, where endogenous TSH is low and may not be increased by thyroxine withdrawal, is an inoperable cancer disease, where the production of endogenous thyroid hormones is high enough to prevent TSH rise. Mostly, these hormones are produced by the surrounding normal follicular cells. When the operation is not possible, we have first to destroy normal thyroid tissue by radioiodine and only then further treatment of cancer disease by the next ¹³¹I therapy is to be considered (34). This is a time-consuming process and during the period required to destroy thyroid tissue cancer progression may proceed. The use of recombinant TSH at the first therapeutic ¹³¹I iodine administration would be beneficial through the activation of radioiodine uptake in the tumour, which presents at this time as a cold lesion. We considered the possibility of rhTSH administration in a patient who presented with a metastatic brain tumour, concentrating ¹³¹I, as the first symptom of DTC. However, our application has been

rejected, due to the risk of the induction of thyroid storm. It has been shown by Ramirez and Braverman et al. (35) that recombinant TSH stimulates normal thyroid very efficiently. RhTSH amounts of 0.1 mg (i.e. much lower than those applied in DTC athyroid patients) are able to stimulate thyroid hormone secretion in healthy subjects up to the levels seen in hyperthyroidism. So, the clinical consequences of the induced hyperthyroidism in patients with the preserved thyroid gland must be considered. Further clinical studies are urgently needed to solve the question, whether the risk of thyroid storm in patients with preserved thyroid is substantial. In our opinion the administration of rhTSH could be a very promising help for ^{131}I therapy in inoperable primary thyroid cancer.

Recombinant TSH is also considered when functional DTC metastases are the source of excessive thyroid hormones, which lower the endogenous TSH level. The opponents indicate that hormonally active metastases will also concentrate iodine, so the help from recombinant TSH may not be so important. One very interesting case report has been published recently (27), where recombinant human TSH was applied to stimulate iodine uptake in the liver metastases of a malignant struma ovarii with overt hyperthyroidism due to their hyperfunction. A careful dosimetric analysis was performed after diagnostic iodine application under rhTSH stimulation. The single course of ^{131}I therapy under rhTSH resulted in a very distinct regression of liver metastases. A 78% uptake of administered iodine in liver metastases was obtained. The authors did not perform a basic study of ^{131}I uptake, so it is not known to what extent the very high uptake of iodine in metastases was due to the administered recombinant TSH (the basal uptake may not be neglected, as liver metastases were able to induce hyperthyroidism in this patient). However, the results indicate the possibility of a significant increase in the efficacy of ^{131}I therapy by

recombinant TSH. Interestingly enough, no aggravation of hyperthyroidism was observed under metoprolol pretreatment, although the rise of T3 up to 310 ng/ml was stated.

Another group of indications for rhTSH encompasses the known contraindications to thyroxine withdrawal. Patients, in whom the rise of endogenous TSH by thyroxine withdrawal is connected with a significant risk of complications, form a major group of candidates for rhTSH treatment. Serious health consequences, such as major depression or heavy gastric symptoms, are imminent after thyroxine withdrawal in some patients. What is clinically more important, however, is that hypothyroidism induced by thyroxine withdrawal may aggravate other serious diseases concomitant to thyroid cancer or caused by DTC. Patients with circulatory or renal insufficiency as well as patients with ischaemic brain disease are most prone to hypothyroidism-induced consequences. This category of indications for recombinant hTSH may be considered as patient-related indications (Table 2).

The second category of contraindications to withdraw thyroid hormones is cancer disease-related contraindications. During thyroxine withdrawal both hypothyroidism-related oedema and TSH stimulation-related increase of tumour volume may induce or aggravate the symptoms of compression in the surrounding normal tissue (25, 37–38). This is extremely dangerous in patients with brain and skull or spine metastases, which may compress neural tissue (36–38). These patients constitute the most obvious candidates for recombinant TSH-aided ^{131}I treatment. Until now we have treated five patients with spine metastases with the support of recombinant hTSH (with six courses of therapy performed) (23, 24). No pain increase due to compression of dorsal nerve roots was noted during therapy or immediately after it in four of them (although in one patient with spine metastasis an incident of distinct pain in-

Table 2. Indications for recombinant human TSH to support ^{131}I therapy of differentiated thyroid carcinoma

Category of indication	Cause	Type of indication for rhTSH
Patient-related	Hypopituitarism	Lack of endogenous TSH
	History of serious complications during former thyroxine withdrawal severe forms of gastritis requiring hospitalisation major depression other symptoms of severe impairment of patient's status or his quality of life	Contraindication for thyroxine withdrawal
	Concomitant diseases which may be potentiated by thyroxine withdrawal circulatory insufficiency renal insufficiency ischaemic brain disease others	Contraindication for thyroxine withdrawal
Cancer disease-related	Metastases destroying pituitary gland	Lack of endogenous TSH
	Risk of compression on neural tissue Brain and spinal cord metastases Central skeleton (skull and spine) metastases	Contraindication for thyroxine withdrawal
	Risk of progression due to the prolonged stimulation of TSH Bone metastases Brain and spinal cord metastases Lymph node metastases Lung metastases	Contraindication for thyroxine withdrawal

crease was observed during preceding ^{131}I therapy after thyroxine withdrawal). The posttherapeutic uptake of ^{131}I was confirmed in 5 of 6 therapies. The short term response (regression or the stagnation of the disease) was stated in three out of five patients.

Another very important indication for rhTSH results from the fact that prolonged stimulation with TSH obtained during thyroxine withdrawal may be dangerous for the induction of cancer progression. This is a well-known clinical phenomenon, although rarely determined in quantitative terms (26, 34). We saw it several times, particularly in patients with bone metastases, when pain started at hormone withdrawal due to the expansion of the tumour volume but was not released after reintroduction of thyroxine, as not only oedema but also increased proliferation were responsible for this effect. Also, lymph node metastases may grow very quickly after thyroxine withdrawal (26).

It is widely accepted that thyroxine-induced TSH suppression is a tool for reduction of DTC relapse. Mazzaferri et al. (1) showed that even in the face of improper primary treatment of DTC (lack of total surgery and/or lack of ^{131}I therapy) thyroxine administration reduced the recurrence rate and death rate from cancer in comparison to no treatment. Recent published reports indicate that a prolonged lack of TSH suppression is a negative prognostic factor increasing the risk of recurrence of DTC (39–41). *In vitro* studies with animal tissues show a distinct increase in the proliferation rate of transformed follicular cells induced by recombinant human TSH (3, 42). Subacute TSH rise in DTC patients, lasting up to 4–6 weeks, which is connected with thyroxine withdrawal, may also result in the induction of proliferation of cancer cells. The increase of serum TSH after rhTSH administration is much shorter, thus, it may have fewer negative consequences (9, 10, 21). Further studies are needed to confirm this hypothesis.

The patients with a high risk of progression during thyroxine withdrawal, who may benefit from rhTSH therapy, are patients with large lymphonodal involvement (even after extensive surgery), with T4 tumour, and patients with distant metastases. Brain metastases form the strongest indication, followed by bone (particularly skull and vertebral) metastases and mediastinal lymph node metastases. The most often seen localisation of distant metastases in DTC are lung metastases and they should also be included.

In fact, the first published case of the successful use of rhTSH in the treatment of metastatic thyroid cancer was connected with the reluctance to withdraw thyroxine replacement in a patient with a very advanced disseminated cancer disease (25). Previous discontinuing of thyroxine for several weeks resulted in a quick growth of local recurrence, which became visible, and possibly also bone metastases. The stimulation of rhTSH enabled ^{131}I treatment, which was performed with a very high activity of 515 mCi of ^{131}I and resulted in a partial regression of the cancer disease and a distinct improvement of the patient's status and his quality of life. Multiple metastases showed ^{131}I uptake on posttherapeutic scintigrams, which were not visible during the earlier diagnostics performed on thyroxine withdrawal. However, the authors could not ultimately define to what extent the obtained result was due to the high activity of ^{131}I applied. They assumed that the observed ^{131}I trapping was due only to rhTSH, but this may not ultimately be proved as they did not perform a repeated diagnostic study with rhTSH at that time. Nevertheless, the possibility that rhTSH reverted the former lack of ^{131}I trapping is very exciting.

In the disseminated differentiated thyroid carcinoma good results of therapy may be achieved only in these patients in whom ^{131}I trapping ability is preserved and may be shown on a posttherapeutic scintigram (8, 34). There are very few therapeutic possibilities for DTC patients with metastases not concentrating ^{131}I (34). Only rarely may surgical excision be proposed. In most cases chemotherapy is ineffective and radiotherapy may be applied only as palliative treatment. Thyroxine suppressive therapy may be of some worth in reducing the rate of progression but is unable to effect regression of the disease (43). The important question is whether rhTSH will be helpful in these patients. A report by Rudavsky and Freeman indicates such a possibility (25).

From the published reports on the effects of rhTSH aided therapy in DTC we expect a description and evaluation of its efficacy in three levels. First, whether the administration of recombinant hTSH results in good ^{131}I trapping by the tumour, confirmed on a posttherapeutic ^{131}I scintigram. It would be advantageous if this effect could be compared to the results of thyroxine withdrawal, but, in contrast to the diagnostic studies, in the case of radioiodine treatment these studies may not be repeated immediately one after the other. The results of previous ^{131}I treatments and the possible dedifferentiation of tumour cells or disease progression have always to be considered.

The second, more important aspect of the direct evaluation of the results of ^{131}I treatment is brought by a posttherapeutic dosimetry (28, 29). In most centres the results of ^{131}I therapy have been evaluated only qualitatively until now. However, some estimations of the absorbed dose have been published (27, 28, 29) and they are now being more widely applied to bring information on the gain obtained by rhTSH. A very elegant study has been published recently by Rotman-Pikielny et al. (27), who estimated the dose absorbed by ^{131}I concentrating liver metastases treated with the aid of rhTSH. In this study, already mentioned above, the pretherapeutic dosimetry approach resulted in a choice of a minimal effective activity of ^{131}I needed to provide the tumoricidal dose of 80 Gy, as estimated by Maxon (28, 29). The ^{131}I activity given was low (65 mCi) in comparison to the normally used fixed activities. What is very impressive is that it resulted in a distinct regression of the total volume of multiple liver metastases of malignant struma ovarii. This approach may be applied in other studies in order to draw final conclusions on the efficacy of rhTSH in the ^{131}I therapy of DTC.

The third and most important level of the evaluation of the rhTSH significance for ^{131}I therapy of DTC will be the final estimation of remission rate and survival in the treated patients. This may not be expected in the next few years, as we know that long times of observations are needed in DTC to appraise any new treatment modality (34). An additional obstacle is connected with the fact that recombinant TSH is introduced often in patients who have already received some courses of therapy after thyroxine withdrawal and the impact of both types of therapies may not be separated.

Potential advantages of the therapeutic use of rhTSH should not conceal the possible adverse effects. The results of diagnostic studies were rather reassuring, but they may not automatically be widened on therapeutic application. In this context we should indicate the recent report of Vargas et al. (26), who described a hemiplegia complicating the course of rhTSH-aided ^{131}I therapy in

a hypothyroid patient with DTC metastatic to the brain. This patient suffered from secondary hypothyroidism due to a metastatic clival lesion that involved the pituitary gland. 48 h after rhTSH administration, still before radioiodine therapy, they observed a haemorrhage in another brain metastasis causing right-side hemiplegia, which resolved only partially later on. The authors considered a direct effect of rhTSH on tumour growth and on vascular permeability in a previously quiescent metastasis in combination with hypothyroidism-induced coagulopathy. The obtained level of serum TSH was very high (up to more than 500 mU/l), thus a decrease in the metabolism of the recombinant protein was taken into consideration as well. The possibility of up-regulation of TSH receptors was also speculated. The authors cautioned the use of rhTSH in patients with brain metastases who are hypothyroid. In this context we should also mention a case of pathologic vertebral fracturing. Its symptoms started some 12 hours after ^{131}I administration (100 mCi) to an rhTSH pretreated patient (23). The incident caused paraplegia. Simultaneously, the loss of ^{131}I uptake in the metastatic vertebra was observed. Thus, we assume that it was not caused by ^{131}I therapy per se. However, an independent event, not causatively related to rhTSH administration, may not be excluded.

In conclusion, the final results of recombinant human TSH application for ^{131}I therapy of differentiated thyroid carcinoma are probably a matter of time, but at present we should evaluate the efficacy of rhTSH from a shorter perspective. When we compare the stimulation with endogenous TSH obtained by thyroxine withdrawal to the administration of recombinant TSH during thyroxine therapy, we should stress the comparable results of ^{131}I - and thyroglobulin-based follow up, the presence of euthyroid status during the follow-up examinations and radioiodine therapy, and finally the short duration of TSH rise which obviously decreases the risk of complications and may decrease the risk of cancer progression — although particularly this last effect requires more clinical evidence.

References

- Mazzaferri EL, Jhiang SM. Long-term impact of initial surgical and medical therapy on papillary and follicular thyroid cancer. *Am J Med* 1994; 97: 418–28.
- Jarząb B, Kalembe B, Handkiewicz Junak D, Włoch J, Roskosz J. Radioiodine Treatment of Differentiated Thyroid Carcinoma in Children and Young Adults: a Multivariate Analysis. Congress of the European Association of Nuclear Medicine 1999, OS-111.
- Ladenson PW. Strategies for thyrotropin use to monitor patients with treated thyroid carcinoma. *Thyroid* 1999; 9: 429–433.
- Colzani RM, Alex S, Fang SL, Braverman LE, Emerson CH. The effect of recombinant human thyrotropin (rhTSH) on thyroid function in mice and rats. *Thyroid* 1998; 8: 797–801.
- Grossmann M, Szkudlinski MW, Dias JA, et al. Site-directed mutagenesis of amino acids 33-44 of the common alpha-subunit reveals different structural requirements for heterodimer expression among the glycoprotein hormones and suggests that cyclic adenosine 3',5'-monophosphate production and growth promotion are potentially dissociable functions of human thyrotropin. *Mol Endocrinol* 1996; 10: 769–779.
- Grossmann M, Weintraub BD, Szkudlinski MW. Novel insights into the molecular mechanisms of human thyrotropin action: structural, physiological, and therapeutic implications for the glycoprotein hormone family. *Endocr Rev* 1997; 18: 476–501.
- Lazar V, Schlumberger M. Decreased NIS expression in 40 of 43 thyroid carcinoma and in 20 of 24 solid adenomas, increased Glut-1-gene expression in some malignant thyroid tumours. *J Clin Endocrinol Metab* 1999; 84: 3228–3234.
- Maxon HR. Detection of residual and recurrent thyroid cancer by radioiodine imaging. *Thyroid* 1999; 9: 443–446.
- Ladenson PW, Braverman LE, Mazzaferri EL, et al. Comparison of administration of recombinant human thyrotropin with withdrawal of thyroid hormone for radioactive iodine scanning in patients with thyroid carcinoma. *N Engl J Med* 1997; 337: 888–896.
- Haugen BR, Pacini F, Reiners C, et al. A comparison of recombinant human thyrotropin and thyroid hormone withdrawal for the detection of thyroid remnant or cancer. *J Clin Endocrinol Metab* 1999; 84: 3877–3885.
- Venkataraman GM, Yatin M, Marcinek R, Ain KB. Restoration of iodide uptake in dedifferentiated thyroid carcinoma: relationship to human Na⁺/I⁻-symporter gene methylation status. *J Clin Endocrinol Metab* 1999; 84: 2449–2457.
- Schlumberger M, Baudin E. Serum thyroglobulin determination in the follow-up of patients with differentiated thyroid carcinoma. *Eur J Endocrinol* 1998; 138: 249–252.
- Kukulska A, Gubala E, Deja R, et al. Receiver-Operator Analysis on Thyroglobulin Estimation During Endogenous TSH Stimulation in Patients with Differentiated Thyroid Cancer “IV European Congress of Endocrinology” 1998, P326.
- Dow KH, Ferrell BR, Anello C. Quality-of-life changes in patients with thyroid cancer after withdrawal of thyroid hormone therapy. *Thyroid* 1997; 7: 613–619.
- Dow KH, Ferrell BR, Anello C. Balancing demands of cancer surveillance among survivors of thyroid cancer. *Cancer Pract* 1997; 5: 289–295.
- Thotakura NR, Desai RK, Bates LG, Cole ES, Pratt BM, Weintraub BD. Biological activity and metabolic clearance of a recombinant human thyrotropin produced in Chinese hamster ovary cells. *Endocrinology* 1991; 128: 341–348.
- Szkudlinski MW, Thotakura NR, Bucci I, et al. Purification and characterization of recombinant human thyrotropin (TSH) isoforms produced by Chinese hamster ovary cells: the role of sialylation and sulfation in TSH bioactivity. *Endocrinology* 1993; 133: 1490–1503.
- Weintraub BD, Szkudlinski MW. Development and in vitro characterization of human recombinant thyrotropin. *Thyroid* 1999; 9: 447–450.
- Hussain A, Zimmerman CA, Boose JA, et al. Large scale synthesis of recombinant human thyrotropin using methotrexate amplification: chromatographic, immunological, and biological characterization. *J Clin Endocrinol Metab* 1996; 81: 1184–1188.
- Hershman JM. Recombinant human thyrotropin. *Thyroid* 1999; 9: 419–420.
- Meier CA, Braverman LE, Ebner SA, et al. Diagnostic use of recombinant human thyrotropin in patients with thyroid carcinoma (phase I/II study). *J Clin Endocrinol Metab* 1994; 78: 188–196.
- Wareet al: SF-36 Health Survey: Manual and Interpretation Guide. Boston: Health Inst, New England Medical Center 1993.
- Jarząb B, Roskosz J, Gawkowska-Suwińska M, et al. Recombinant human TSH for the treatment of differentiated thyroid cancer metastatic to the spine. In press.
- Roskosz J, Turska M, Gawkowska-Suwińska M, Handkiewicz Junak D, Jarząb B. The use of recombinant human TSH in the treatment of disseminated thyroid cancer. This volume.
- Rudavsky AZ, Freeman LM. Treatment of scan-negative, thyroglobulin-positive metastatic thyroid cancer using radioiodine ^{131}I and recombinant human thyroid stimulating hormone. *J Clin Endocrinol Metab* 1997; 82: 11–14.
- Vargas GE, UY H, Bazan C, Guise TA, Bruder JM. Hemiplegia after thyrotropin alfa in a hypothyroid patient with thyroid carcinoma metastatic to the brain. *J Clin Endocrinol Metab* 1999; 84: 3867–3871.

27. Rotman-Pikielny P, Reynolds JC, Barker WC, Yen PM, Skarulis MC, Sarlis NJ. Recombinant human thyrotropin for the diagnosis and treatment of a highly functional metastatic struma ovarii. *J Clin Endocrinol Metab* 2000; 85: 237–244.
28. Maxon HR 3d, Englaro EE, Thomas SR, et al. Radioiodine-131 therapy for well-differentiated thyroid cancer — a quantitative radiation dosimetric approach: outcome and validation in 85 patients. *J Nucl Med* 1992; 33: 1132–1136.
29. Maxon HR, Thomas SR, Samaratunga RC. Dosimetric considerations in the radioiodine treatment of macrometastases and micrometastases from differentiated thyroid cancer. *Thyroid* 1997; 7: 183–187.
30. Ringel MD, Ladenson PW. Diagnostic accuracy of 131I scanning with recombinant human thyrotropin versus thyroid hormone withdrawal in a patient with metastatic thyroid carcinoma and hypopituitarism. *J Clin Endocrinol Metab* 1996; 81: 1724–1725.
31. Colleran KM, Burge MR. Isolated thyrotropin deficiency secondary to primary empty sella in a patient with differentiated thyroid carcinoma: an indication for recombinant thyrotropin. *Thyroid* 1999; 9: 1249–1252.
32. Risse JH, Grunwald F, Bender H, Schuller H, Van Roost D, Biersack HJ. Recombinant human thyrotropin in thyroid cancer and hypopituitarism due to sella metastasis. *Thyroid* 1999; 9: 1253–1256.
33. Masiukiewicz US, Nakchbandi IA, Stewart AF, Inzucchi SE. Papillary thyroid carcinoma metastatic to the pituitary gland. *Thyroid* 1999; 9: 1023–1027.
34. Mazzaferri EL. An overview of the management of papillary and follicular thyroid carcinoma. *Thyroid* 1999; 9: 421–427.
35. Ramirez L, Braverman LE, White B, Emerson CH. Recombinant human thyrotropin is a potent stimulator of thyroid function in normal subjects. *J Clin Endocrinol Metab* 1997; 82: 2836–2839.
36. Goldberg LD, Ditchek NT. Thyroid carcinoma with spinal cord compression. *JAMA* 1981; 245: 953–954.
37. Datz FL. Cerebral edema following iodine-131 therapy for thyroid carcinoma metastatic to the brain. *J Nucl Med* 1986; 27: 637–640.
38. Holmquest DL, Lake P. Sudden hemorrhage in metastatic thyroid carcinoma of the brain during treatment with iodine-131. *J Nucl Med* 1976; 17: 307–309.
39. Pujol P, Daures JP, Nsakala N, Baldet L, Bringer J, Jaffiol C. Degree of thyrotropin suppression as a prognostic determinant in differentiated thyroid cancer. *J Clin Endocrinol Metab* 1996; 81: 4318–4323.
40. Cooper DS, Specker B, Ho M, et al. Thyrotropin suppression and disease progression in patients with differentiated thyroid cancer: results from the National Thyroid Cancer Treatment Cooperative Registry. *Thyroid* 1998; 8: 737–744.
41. Bohm J, Kosma VM, Eskelinen M, et al. Non-suppressed thyrotropin and elevated thyroglobulin are independent predictors of recurrence in differentiated thyroid carcinoma. *Eur J Endocrinol* 1999; 141: 460–467.
42. Sagartz JE, Jhiang SM, Tong Q, Capen CC. Thyroid-stimulating hormone promotes growth of thyroid carcinomas in transgenic mice with targeted expression of the ret/PTC1 oncogene. *Lab Invest* 1997; 76: 307–318.
43. Burmeister LA. Thyroid hormone in the treatment of thyroid cancer: rationale and regimen. *Curr Opin Endocrinol Diabetes* 1999; 6: 282–286.