

Jacek Calik

Department of Clinical Oncology/Chemotherapy, Lower Silesian Oncology Centre, Wrocław

Effectiveness of nivolumab in an elderly patient with metastatic *BRAF*-negative melanoma originating from the anal region

Address for correspondence:

Dr n. med. Jacek Calik
Oddział Onkologii Klinicznej/Chemioterapii
Dolnośląskiego Centrum Onkologii
pl. Hirszfelda 12, 53–413 Wrocław
Phone: +48 502 479 582
e-mail: calik.j@dco.com.pl

Oncology in Clinical Practice
2017, Vol. 13, No. 6, 308–310
DOI: 10.5603/OCP.2017.0032
Translation: lek. Maciej Kawecki
Copyright © 2017 Via Medica
ISSN 2450–1654

ABSTRACT

High serum concentration of lactate dehydrogenase (LDH) is associated with poor prognosis in patients with metastatic cutaneous melanoma. Herein, we present a case of a 92-year-old patient with metastatic melanoma and negative prognostic factors treated with anti-PD-1 antibody nivolumab. The therapy yielded excellent clinical results: significant regression of metastatic lesions and improvement in the patient's performance status. The presented case confirms previously reported observations regarding high clinical activity and acceptable safety profile of nivolumab in elderly patients.

Key words: melanoma, senior age, anti-PD-1, nivolumab

Oncol Clin Pract 2017; 13, 6: 308–310

Introduction

Malignant melanoma is a malignancy originating from melanocytes. Skin is the most common site of melanoma, although possible locations also include mucosal membranes, eyeball (choroid, ciliary body, iris), or central nervous system [1, 2]. Primary location of melanoma in the anal region is a scarcity because probably most of the melanomas in this region arise from skin without previous exposure to sunlight radiation (non-chronic sun damage; non-CSD). Usually, this subtype of melanoma is associated with more aggressive course of the disease than cutaneous melanoma linked to chronic sun damage [3].

Case report

We present a case of 92-year-old male, without comorbidities other than history of arterial hypertension, in whom cutaneous melanoma of the anal region was excised on 19 December 2012. Histopathological examination confirmed the diagnosis of cutaneous

melanoma, with Breslow's depth 2.3 mm, Clark's level stage IV, and mitotic index 3/mm². Chest X-ray and abdominal ultrasound examination showed no signs of metastatic spread. The patient underwent wide local excision and sentinel lymph node biopsy (SLNB) on 19 February 2013, without the presence of melanoma within the excised scar and within two evaluated sentinel lymph nodes. Afterwards, the patient remained under regular clinical surveillance. In April 2014 the presence of suspicious infiltration in the rectum was detected and examination from a specimen obtained via endoscopy for suspected presence of melanoma. On 14 May 2014 abdominoperineal resection of the rectum with a formation of colostomy was performed. The pathology report of postoperative material confirmed the presence of melanoma infiltrates in the rectum and the presence of metastases in one out of five excised perirectal lymph nodes. In January 2016 new metastatic lesions were found in the groins and the patient underwent bilateral inguinal lymphadenectomy. Melanoma metastases were confirmed in seven out of 10 lymph nodes examined from the left groin and in four of six

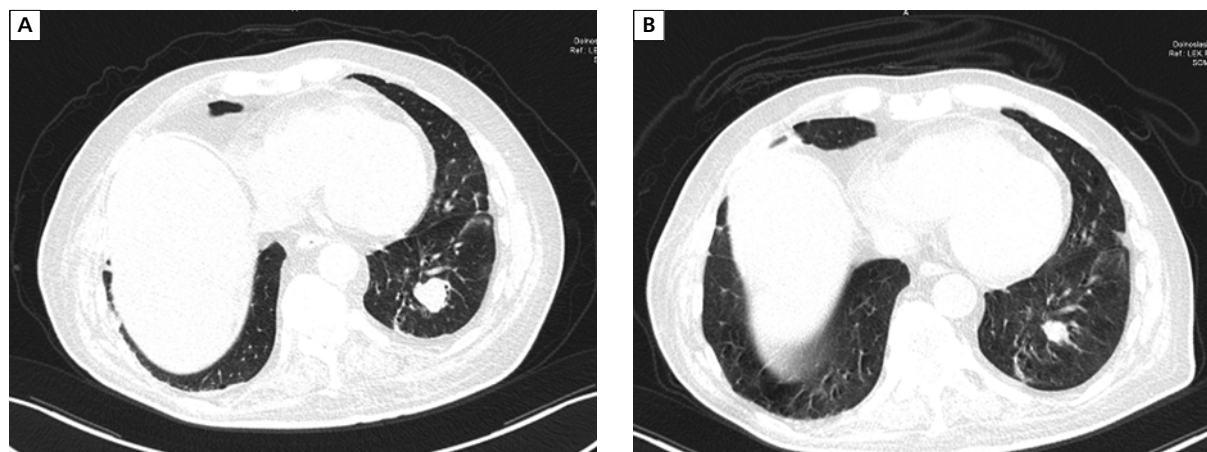


Figure 1. Lung metastasis before (A) and 3 months after initiation of nivolumab (B)

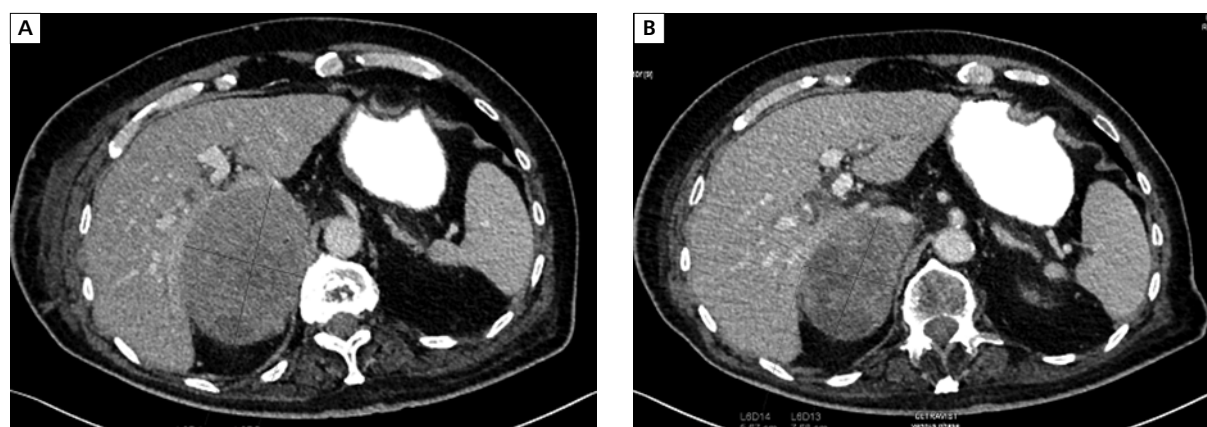


Figure 2. Right adrenal metastasis before (A) and 3 months after initiation of nivolumab (B)

lymph nodes from the right groin. Due to the presence of melanoma infiltrates within capsules of excised lymph nodes, both inguinal regions were irradiated with 36 Gy in nine fractions as an adjuvant therapy.

The patient remained under observation until April 2017, when a follow-up abdomen CT scan showed the presence of a metastatic lesion in the adrenal gland, lymph nodes along the iliac vessels, and recurrence in the rectum. Additionally, chest CT scan revealed numerous metastases in both lungs, up to 2.5 cm in diameter, and brain CT scan showed no signs of central nervous system metastases. Molecular analyses from previously obtained material excluded the presence of targetable *BRAF* mutation.

Therefore, immunotherapy with nivolumab was initiated. The patient received first dose of nivolumab on 27 April 2017 and fortnightly afterwards on a regular basis. At the time of therapy introduction, laboratory analyses showed leukopaenia of $2.12 \times 10^3/\mu\text{L}$, neutropaenia of $1.18 \times 10^3/\mu\text{L}$, highly elevated serum LDH level of 890 U/L (with upper limit of 240 U/L), and liver enzymes over 1.5 times above the upper limit of normal. Further laboratory analyses done during therapy showed nor-

malisation of blood and biochemical parameters, which correlated with improvement in the patient's performance status. First control CT scans performed on the 25th of July 2017 demonstrated regression of pulmonary lesions diameters (Fig. 1), as well as partial regression of metastasis in right adrenal gland (Fig. 2) and regression of lesion in rectum (Fig. 3). Treatment tolerance was well and the patient currently continues treatment with nivolumab.

Summary

Cutaneous melanoma can be effectively treated with anti-PD-1 antibodies in elderly patients, even in the presence of negative prognostic factors such as elevated serum LDH concentration. Available literature reports suggest non-inferior outcomes with use of immunotherapy in patients aged over and under 70 years old [4, 5]. The presented case represents an excellent example of safe and effective treatment of an elderly patient with cutaneous melanoma. Currently, immunotherapy remains the treatment-of-choice in metastatic *BRAF*-negative melanoma [2, 6, 7].

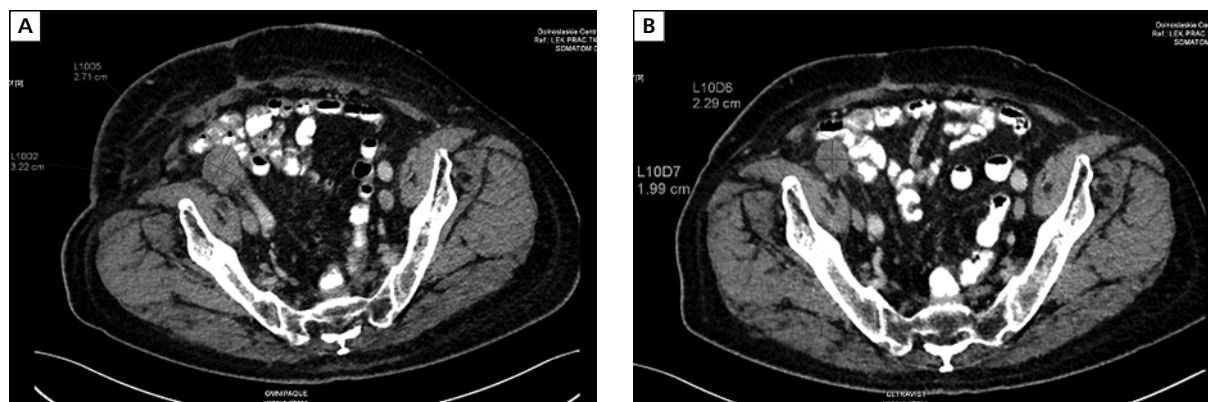


Figure 3. Metastases along iliac vessels before (A) and 3 months after initiation of nivolumab (B)

References

1. Brudnik U, Wojas-Pelc A, Branicki W. Genetyczne uwarunkowania czerniaka. *Post Dermatol Alergol.* 2006; 1: 21–25.
2. Ruka W, Nowecki Z, Rutkowski P. Czerniaki skóry u dorosłych monografia. Medipage, Warszawa 2005.
3. Scolyer RA, Long GV, Thompson JF. Evolving concepts in melanoma classification and their relevance to multidisciplinary melanoma patient care. *Mol Oncol.* 2011; 5(2): 124–136, doi: [10.1016/j.molonc.2011.03.002](https://doi.org/10.1016/j.molonc.2011.03.002), indexed in Pubmed: [21482206](https://pubmed.ncbi.nlm.nih.gov/21482206/).
4. Callahan MK, Wolchok JD. At the bedside: CTLA-4- and PD-1-blocking antibodies in cancer immunotherapy. *J Leukoc Biol.* 2013; 94(1): 41–53, doi: [10.1189/jlb.1212631](https://doi.org/10.1189/jlb.1212631), indexed in Pubmed: [23667165](https://pubmed.ncbi.nlm.nih.gov/23667165/).
5. Elias R, Morales J, Rehman Y, et al. Immune Checkpoint Inhibitors in Older Adults. *Curr Oncol Rep.* 2016; 18(8): 47, doi: [10.1007/s11912-016-0534-9](https://doi.org/10.1007/s11912-016-0534-9), indexed in Pubmed: [27287329](https://pubmed.ncbi.nlm.nih.gov/27287329/).
6. Krzakowski M, Warzocha K. Zalecenia postępowania diagnostyczno-terapeutycznego w nowotworach złośliwych. *Via Medica, Gdańsk* 2013: 422.
7. Mackiewicz J, Kwinta Ł. Nowe terapie celowane stosowane u chorych na czerniaka uogólnionego. *Współczesna Onkologia.* 2010; 14(1): 15–22.
8. Rutkowski P. Nowotwory złośliwe skóry. *Via Medica, Gdańsk* 2014.