

**Kamila Patrycja Kidrycka<sup>1</sup>, Justyna Burzyńska-Śliwowska<sup>1</sup>, Rafał Maksim<sup>2</sup>, Andrzej Namiot<sup>4</sup>, Marek Z. Wojtukiewicz<sup>4</sup>, Ewa Sierko<sup>2, 4</sup>**

<sup>1</sup>Institute of Diagnostic Imaging of the Oncology Centre in Białystok, Poland

<sup>2</sup>Radiotherapy Institute of the Oncology Centre in Białystok, Poland

<sup>3</sup>Institute of Anatomy, Białystok Medical University, Poland

<sup>4</sup>Department of Oncology, Białystok Medical University, Poland

# Angiosarcoma — a malignant neoplasm secondary to radiotherapy for breast cancer in a female patient following breast-conserving treatment — a case report

## Address for correspondence:

Dr hab. n. med. Ewa Sierko  
 Klinika Onkologii,  
 Uniwersytet Medyczny w Białymstoku  
 e-mail: ewa.sierko@iq.pl

Oncology in Clinical Practice  
 2019, Vol. 15, No. 4, 217–222  
 DOI: 10.5603/OCP.2019.0012  
 Translation: dr Elżbieta Stelmaszczyk  
 Copyright © 2019 Via Medica  
 ISSN 2450–1654

## ABSTRACT

Angiosarcoma is a rare malignant neoplasm, accounting for 1–2% of all sarcomas. The main cause of developing secondary angiosarcoma is radiotherapy. We analysed the case of a 52-year-old woman with breast cancer, who had undergone breast-conserving therapy. Four years after finishing treatment, she was diagnosed with secondary angiosarcoma in the irradiated area. The patient underwent a mastectomy. The disease relapsed six months after the operation in form of local recurrence, as well as liver and lung metastases. The patient's condition gradually deteriorated despite treatment (chemotherapy and symptomatic management). The patient died due to cardiorespiratory failure nine months after the diagnosis of secondary malignancy.

**Key words:** angiosarcoma, breast cancer, chemotherapy, secondary malignant neoplasm, radiotherapy

Oncol Clin Pract 2019; 15, 4: 217–222

## Introduction

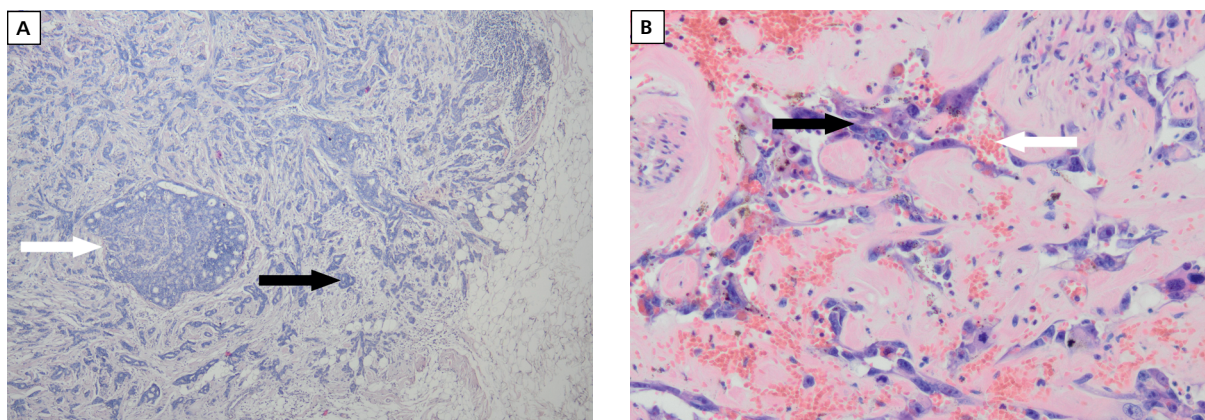
The incidence of sarcomas in Poland is estimated at 2/100,000 per year; 1–2% of them are angiosarcomas (AS) [1, 2], which are soft tissue sarcomas stemming from the endothelial cells of blood or lymphatic vessels [3]. The most common locations of this tumour are the head, breast, and the limbs [4]. These neoplasms may occur as primary tumours, with no influence of external factors, or as secondary tumours — usually following radiotherapy (RT). The latter constitute about 0.5–5% of all sarcomas [5, 6]. Although the secondary AS of the breast is very rare and constitutes about 0.9 per 1000 cases of malignant neoplasms of the breast, they are an important clinical issue because they are characterised by a poor prognosis. It is estimated that their number

will grow due to the higher incidence of breast cancer and the use of RT in breast-conserving treatment [7–9].

Below, we present the case of a 52-year-old female breast cancer patient who had previously undergone breast-conserving therapy with a radical goal. Four years after finishing the above treatment, an AS with a high grade of malignancy was diagnosed in the RT area.

## Case report

A 47-year-old woman came in for mammography (MMG) in November 2012, which showed a lesion of increased density with malignant characteristics (BI-RADS 5), about 19 mm in size, in the upper exterior quadrant of the left breast, within 2 cm of the areola.



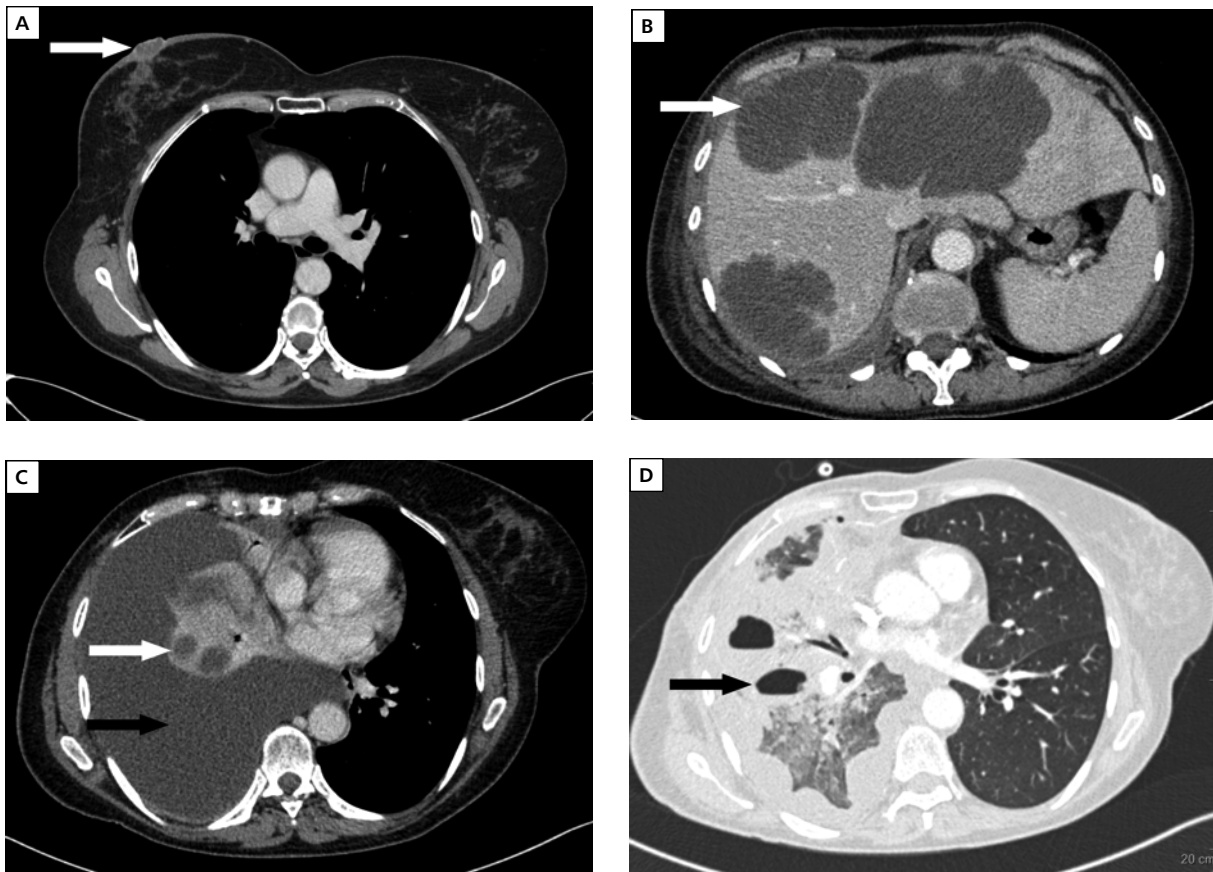
**Figure 1.** Pathology images of right breast tumour **A.** G2 Duct carcinoma (black arrow) and a lesion of non-invasive duct carcinoma (white arrow) (4× magnification). **B.** Angiosarcoma with a high malignancy level — pathological vascular fissures (white arrow) lined with abnormal neoplastic cells (black arrow) (20× magnification)

In an ultrasonographically (USG) controlled fine-needle biopsy of the above-mentioned lesion, the presence of malignant cells was confirmed. In the same month, the patient underwent breast-conserving surgery (excision of the upper external quadrant along with the sentinel lymph node). In a surgical pathology test, metastases to the sentinel lymph node were detected, and a decision was made to excise the remaining axillary lymph nodes. The lesion was excised completely — macroscopically as well as microscopically. In a post-operative pathology examination, the presence of invasive grade 2 (G2) ductal carcinoma (Figure 1A) was detected, with estrogen receptor (ER) expression in 80% of the tumour cells, and progesterone receptor (PR) expression in 90% of the cells, but no human epidermal growth factor receptor 2 (HER2) expression was found and Ki-67 cell proliferation marker was present in 5% of the tumour cells. Distally, focal lesions of ductal carcinoma *in situ* (DCIS) were present. Metastases to one of the eight excised lymph nodes were detected. The clinical stage of the disease was marked as pT2N1M0.

The patient received four cycles of adjuvant chemotherapy (AC regimen — doxorubicin and cyclophosphamide) from January 2013 until March 2013, with subsequent adjuvant hormonal therapy with tamoxifen at a daily dose of 20 mg (beginning in March 2013). From April 2013 until June 2013, the patient was treated with postoperative radiotherapy for the area of the right breast, in radiation conditions of × 4MV, × 6MV up to a total dose of 50 Gy/2 Gy/in 25 fractions. For the post-operative area, the total dose was raised to 66 Gy/2 Gy/in 33 fractions. During radiotherapy, an acute cutaneous post-radiation reaction occurred with a G2 intensity in the RTOG scale, which healed after a month's time.

In August of 2013, after the acute reaction had healed, redness and swelling of the skin of the right

breast appeared again, and remained throughout the time during which routine examinations were conducted. On imaging — MMG and USG — performed outside of our hospital, no evidence of recurrent disease was detected. In July 2017, four years after completing radiotherapy, a cyanotic lesion on the skin of the right breast appeared, along with a small ulceration in the proximity of the nipple. Antibiotics and anti-coagulants were prescribed. Due to the continuing presence of the above-mentioned lesions, in December of 2017 samples were taken from the ulcerated lesion near the nipple (Figure 2A). Pathology examination revealed AS — a malignant neoplasm secondary to radiotherapy (Figure 1B). Computed tomography (CT) scans showed no evidence of distal metastases. The patient underwent mastectomy in January 2018. In July 2018, on imaging done outside of our hospital, metastases to the lungs and liver were shown. On examination upon hospital admission, traits of local recurrence were observed in the form of lumps in the scar from the right-side mastectomy. In August 2018, half a year after the surgery, the patient underwent palliative chemotherapy (ADIC regimen — doxorubicin and dacarbazine). After the first cycle of this treatment, laboratory testing showed anaemia and G3 neutropaenia. Treatment with granulocyte growth factor was applied, along with symptomatic treatment, and the patient's condition improved. Within the same month, due to increasing dyspnea and recurring fluid in the pleural cavity (after draining the right pleural cavity twice), and clinical recurrence, a control CT scan was performed. The test showed local recurrence, metastases to the lungs and liver, a significant amount of fluid in the pleural cavity, and fungal lesions in the lungs (Figure 2B, C, D). In order to lessen the symptoms, talc pleurodesis was performed. In September 2018, in an angio-CT scan of the thorax, a sub-segmental pulmonary embolism was detected, along with progression of local infiltration and



**Figure 2.** Angiosarcoma in a 53-year-old female patient, 4 years after completion of radical treatment of breast cancer (breast-conserving surgery, radiotherapy, chemotherapy). Computed tomography following contrast administration (venous phase). **A.** Tumour of right nipple-surrounding area (white arrow). Testing conducted previous to treatment (January 2018). **B.** Cystic metastases of angiosarcoma to the liver (white arrow), Testing conducted after chemotherapy (August 2018). **C.** Cystic metastases to the lungs (white arrow) and free flood in the pleural cavity (black arrow). Test conducted after chemotherapy (August 2018). **D.** Fungal cavities in the right lung (black arrow) — lung window. Testing conducted after chemotherapy (September 2018)

enlargement of fungal lesions in the lungs. The patient was given anti-fungal treatment and the best possible symptomatic treatment. Despite treatment, the patient's state gradually worsened, and in September 2018 she died due to cardiorespiratory insufficiency.

## Discussion

Angiosarcomas are very rare tumours, characterised by a high level of malignancy [10]. Factors predisposing towards the development of AS are: previous radiotherapy, exposure to polyvinyl chloride, arsenic, and thorium dioxide, chronic swelling (described as Steward-Trewes syndrome in related literature), and probably exposure to UV radiation (especially cutaneous sarcomas of the head) [4, 10–16]. No co-occurrence with genetic syndromes has been proven, although 3% of patients

with AS are diagnosed with Ollier's disease, Maffucci disease, von Recklinghausen syndrome, retinoblastoma, or xeroderma pigmentosum [4, 13, 17–19].

In a retrospective study, Kirova YM et al. [20] showed that of 13,472 patients who underwent radiotherapy due to early breast cancer, 35 developed sarcomas (48% — 12 patients had breast AS and 1 patient was found to have AS of thoracic region). The cumulated risk of RT-induced sarcoma has been calculated to be 0.27% after 10 years, and 0.48% 15 years after treatment with radiation. The standardised incidence ratio (SIR) for sarcomas in patients with breast cancer, who previously underwent radiation therapy, has been calculated at 10.2; however, in women who did not receive RT, the SIR amounts to 1.3. Yap et al. [7] also observed an increase in sarcoma incidence in the area submitted to radiation. Among them, AS amounted to 56.8% of cases. However, in those who did not undergo RT, only

5.7% developed this malignancy. In a study by Huang et al. [21], an increased incidence of soft-tissue sarcomas was also confirmed (especially AS), in patients who had undergone RT due to breast cancer. The standardised incidence factor in the case of AS secondary to RT has been estimated at 26.2, and 2.1 in women who were not treated with RT.

It is thought that the highest incidence of radiation-induced AS is in patients undergoing treatment for breast cancer of lymphoma [7, 21, 22]. The latency period from completion of RT to the development of breast AS varies from 3 to 25 years [15, 23–26]. The pathological mechanism of RT's influence on the development of AS is not fully known yet. It suggests that radiation dosages above 50 Gy cause cellular apoptosis, and doses below 50 Gy cause DNA damage and instability. Sarcomas often occur on the area surrounding the irradiated body part, where doses may vary [23, 24]. Attempts at modifying the radiation dosage, volume of the body space being irradiated, and the total RT time in breast cancer patients are being made in order to lower the risk of recurrent disease, as well as the occurrence of late-onset radiation complications [27–29].

A primary breast AS usually occurs in women aged 30–50 years as a lump of the breast, whereas the secondary AS usually develops in women aged over 60 years as a cutaneous lesion (a blue-cherry colour lump, swelling, erythematous patches) [15, 16, 26].

On imaging (USG, MMG), sarcomas of the breast give nonspecific symptoms — usually a thickening and swelling of the skin, similar to the lesions present in most women who undergo breast-conserving therapy and supplementary radiotherapy. This causes a delay in diagnosis and treatment. In the case of suspicion of a breast AS, the best imaging test is MRI [9, 30, 31]. The final diagnosis of AS is made based on the results of pathological testing [32, 33].

The tumours being discussed — besides a high rate of local recurrences — are characterised by a relatively high rate of distal metastases and are associated with poor prognosis. The most important prognostic factors related to poor outcomes are: the diameter of the tumour, the depth of infiltration, positive surgical margins, the presence of metastases, or local recurrence after surgical resection [23, 34, 35]. The most common sites of distal metastases are the lungs [16, 36], but liver, cecum, tonsillar, cheek, oral cavity, and heart metastases are also documented. [37–40].

The only chance of cure in patients with secondary AS is when R0 margins are achieved during surgery [41, 42]. In a case series of 14 patients observed for 12 years, a non-radical resection of the tumour was associated with rapid local recurrence and poor prognosis. The

average survival time of patients who had undergone extensive surgery amounted to 42 months, when compared to six months in people who did not achieve R0 margins [24]. However, in a study by Seinen et al. [23], in 14 out of 24 patients who underwent a mastectomy, a surgical margin free of malignancy was achieved, when compared to two out of seven patients who underwent a tumour resection with a macroscopic margin equal to or greater than 2 cm. Only 3 women underwent an extensive resection of the area subjected to radiation, and in 2 of these patients the surgical margin was free of tumour cells. Despite achieving R0 margins in these patients, in about 2/3 of these patients local recurrence took place, and the median survival specific to the disease was 37 months.

In the case of AS, RT may be considered, although most radiation oncologists are not very willing to apply it to an area which was previously irradiated. Some authors claim that hyper-fractionated adjuvant RT after surgery may be a promising method of secondary AS treatment. [43–45].

So far, there has been a lack of unequivocal data regarding adjuvant chemotherapy in this indication [4, 17, 46, 47]. The most effective agents are doxorubicin and ifosfamide [48]. Some studies have proven that simultaneous treatment with neoadjuvant chemotherapy and hyperthermia in patients with poor prognostic soft tissue sarcoma results in better survival [49].

Currently, the greatest hope in treating sarcoma patients is based on the molecular biology evolution. Bevacizumab, sorafenib, and pazopanib were studied among other agents [50, 51]. A varied response to treatment with sorafenib and bevacizumab was found [51–53]. In the case of pazopanib, an improvement in progression-free survival was found; however, the effectiveness of the drug may be limited due to the sarcoma's acquisition of immunity to a given therapy [54, 55]. Anti-angiogenic treatment may play a role in some soft tissue therapy, which is why further research is necessary for the planning of effective therapeutic regimens [51, 52].

In conclusion, malignant neoplasm secondary to RT — an AS with a high level of malignancy — developed just four years after irradiation. The disease course was aggressive — just a month after surgical resection due to AS, local recurrence appeared, along with metastases to the lungs and liver. The patient survived only nine months after receiving the diagnosis. Studies aimed at identifying factors that amplify the risk of acquiring AS secondarily to RT are needed. Awareness regarding late-onset complications of RT, such as secondary neoplasms, should be raised among doctors who are responsible for patient observation, in order for the earliest possible detection to take place.

## References

- Ducimetière F, Lurkin A, Ranchère-Vince D, et al. Incidence of sarcoma histotypes and molecular subtypes in a prospective epidemiological study with central pathology review and molecular testing. *PLoS One*. 2011; 6(8): e20294, doi: [10.1371/journal.pone.0020294](https://doi.org/10.1371/journal.pone.0020294), indexed in Pubmed: [21826194](https://pubmed.ncbi.nlm.nih.gov/21826194/).
- Jodkiewicz Z, Kozakiewicz B, Roszkowska-Purska K, et al. Angiosarcoma w obszarze napromienianym po 16 latach obserwacji u chorej na raka piersi leczonej oszczędzająco — analiza przypadku. *Nowotwory Journal of Oncology*. 2014; 64(5): 396–400.
- Buehler D, Rice SR, Moody JS, et al. Angiosarcoma outcomes and prognostic factors: a 25-year single institution experience. *Am J Clin Oncol*. 2014; 37(5): 473–479, doi: [10.1097/COC.0b013e31827e4e7b](https://doi.org/10.1097/COC.0b013e31827e4e7b), indexed in Pubmed: [23428947](https://pubmed.ncbi.nlm.nih.gov/23428947/).
- Young RJ, Woll PJ, Staton CA, et al. Angiosarcoma. *Lancet Oncol*. 2010; 11(10): 983–991, doi: [10.1016/S1470-2045\(10\)70023-1](https://doi.org/10.1016/S1470-2045(10)70023-1), indexed in Pubmed: [20537949](https://pubmed.ncbi.nlm.nih.gov/20537949/).
- Arora TK, Terracina KP, Soong J, et al. Primary and secondary angiosarcoma of the breast. *Gland Surg*. 2014; 3(1): 28–34, doi: [10.3978/j.issn.2227-684X.2013.12.03](https://doi.org/10.3978/j.issn.2227-684X.2013.12.03), indexed in Pubmed: [25083491](https://pubmed.ncbi.nlm.nih.gov/25083491/).
- Sheppard DG, Libshitz HI. Post-radiation sarcomas: a review of the clinical and imaging features in 63 cases. *Clin Radiol*. 2001; 56(1): 22–29, doi: [10.1053/crad.2000.0599](https://doi.org/10.1053/crad.2000.0599), indexed in Pubmed: [11162693](https://pubmed.ncbi.nlm.nih.gov/11162693/).
- Yap J, Chuba PJ, Thomas R, et al. Sarcoma as a second malignancy after treatment for breast cancer. *Int J Radiat Oncol Biol Phys*. 2002; 52(5): 1231–1237, indexed in Pubmed: [11955733](https://pubmed.ncbi.nlm.nih.gov/11955733/).
- Thijssens KMJ, van Ginkel RJ, Suurmeijer AJH, et al. Radiation-induced sarcoma: a challenge for the surgeon. *Ann Surg Oncol*. 2005; 12(3): 237–245, doi: [10.1245/ASO.2005.03.041](https://doi.org/10.1245/ASO.2005.03.041), indexed in Pubmed: [15827816](https://pubmed.ncbi.nlm.nih.gov/15827816/).
- Mery CM, George S, Bertagnolli MM, et al. Secondary sarcomas after radiotherapy for breast cancer: sustained risk and poor survival. *Cancer*. 2009; 115(18): 4055–4063, doi: [10.1002/cncr.24462](https://doi.org/10.1002/cncr.24462), indexed in Pubmed: [19526590](https://pubmed.ncbi.nlm.nih.gov/19526590/).
- Buehler D, Rice SR, Moody JS, et al. Angiosarcoma outcomes and prognostic factors: a 25-year single institution experience. *Am J Clin Oncol*. 2014; 37(5): 473–479, doi: [10.1097/COC.0b013e31827e4e7b](https://doi.org/10.1097/COC.0b013e31827e4e7b), indexed in Pubmed: [23428947](https://pubmed.ncbi.nlm.nih.gov/23428947/).
- Fodor J, Orosz Z, Szabó E, et al. Angiosarcoma after conservation treatment for breast carcinoma: our experience and a review of the literature. *J Am Acad Dermatol*. 2006; 54(3): 499–504, doi: [10.1016/j.jaad.2005.10.017](https://doi.org/10.1016/j.jaad.2005.10.017), indexed in Pubmed: [16488303](https://pubmed.ncbi.nlm.nih.gov/16488303/).
- Billings SD, McKenney JK, Folpe AL, et al. Cutaneous angiosarcoma following breast-conserving surgery and radiation: an analysis of 27 cases. *Am J Surg Pathol*. 2004; 28(6): 781–788, indexed in Pubmed: [15166670](https://pubmed.ncbi.nlm.nih.gov/15166670/).
- Penel N, Grosjean J, Robin YM, et al. Frequency of certain established risk factors in soft tissue sarcomas in adults: a prospective descriptive study of 658 cases. *Sarcoma*. 2008; 2008: 459386, doi: [10.1155/2008/459386](https://doi.org/10.1155/2008/459386), indexed in Pubmed: [18497869](https://pubmed.ncbi.nlm.nih.gov/18497869/).
- Berebichez-Fridman R, Deutsch YE, Joyal TM, et al. Stewart-Treves Syndrome: A Case Report and Review of the Literature. *Case Rep Oncol*. 2016; 9(1): 205–211, doi: [10.1159/000445427](https://doi.org/10.1159/000445427), indexed in Pubmed: [27099606](https://pubmed.ncbi.nlm.nih.gov/27099606/).
- Hui A, Henderson M, Speakman D, et al. Angiosarcoma of the breast: a difficult surgical challenge. *Breast*. 2012; 21(4): 584–589, doi: [10.1016/j.breast.2012.01.001](https://doi.org/10.1016/j.breast.2012.01.001), indexed in Pubmed: [22305554](https://pubmed.ncbi.nlm.nih.gov/22305554/).
- Torres KE, Ravi V, Kin K, et al. Long-term outcomes in patients with radiation-associated angiosarcomas of the breast following surgery and radiotherapy for breast cancer. *Ann Surg Oncol*. 2013; 20(4): 1267–1274, doi: [10.1245/s10434-012-2755-y](https://doi.org/10.1245/s10434-012-2755-y), indexed in Pubmed: [23224828](https://pubmed.ncbi.nlm.nih.gov/23224828/).
- Penel N, Marréaud S, Robin YM, et al. Angiosarcoma: state of the art and perspectives. *Crit Rev Oncol Hematol*. 2011; 80(2): 257–263, doi: [10.1016/j.critrevonc.2010.10.007](https://doi.org/10.1016/j.critrevonc.2010.10.007), indexed in Pubmed: [21055965](https://pubmed.ncbi.nlm.nih.gov/21055965/).
- Forman D, Bennett B, Stafford J, et al. Exposure to vinyl chloride and angiosarcoma of the liver: a report of the register of cases. *Br J Ind Med*. 1985; 42(11): 750–753, indexed in Pubmed: [4063218](https://pubmed.ncbi.nlm.nih.gov/4063218/).
- Fury MG, Antonescu CR, Van Zee KJ, et al. A 14-year retrospective review of angiosarcoma: clinical characteristics, prognostic factors, and treatment outcomes with surgery and chemotherapy. *Cancer J*. 2005; 11(3): 241–247, indexed in Pubmed: [16053668](https://pubmed.ncbi.nlm.nih.gov/16053668/).
- Kirova YM, Gambotti L, De Rycke Y, et al. Radiation-induced sarcomas after radiotherapy for breast carcinoma: a large-scale single-institution review. *Cancer*. 2005; 104(4): 856–863, doi: [10.1002/cncr.21223](https://doi.org/10.1002/cncr.21223), indexed in Pubmed: [15981282](https://pubmed.ncbi.nlm.nih.gov/15981282/).
- Huang J, Mackillop WJ. Increased risk of soft tissue sarcoma after radiotherapy in women with breast carcinoma. *Cancer*. 2001; 92(1): 172–180, indexed in Pubmed: [11443624](https://pubmed.ncbi.nlm.nih.gov/11443624/).
- Virtanen A, Pukkala E, Auvinen A. Angiosarcoma after radiotherapy: a cohort study of 332,163 Finnish cancer patients. *Br J Cancer*. 2007; 97(1): 115–117, doi: [10.1038/sj.bjc.6603805](https://doi.org/10.1038/sj.bjc.6603805), indexed in Pubmed: [17519906](https://pubmed.ncbi.nlm.nih.gov/17519906/).
- Seinen JM, Styring E, Verstappen V, et al. Radiation-associated angiosarcoma after breast cancer: high recurrence rate and poor survival despite surgical treatment with R0 resection. *Ann Surg Oncol*. 2012; 19(8): 2700–2706, doi: [10.1245/s10434-012-2310-x](https://doi.org/10.1245/s10434-012-2310-x), indexed in Pubmed: [22466664](https://pubmed.ncbi.nlm.nih.gov/22466664/).
- Jallali N, James S, Searle A, et al. Surgical management of radiation-induced angiosarcoma after breast conservation therapy. *Am J Surg*. 2012; 203(2): 156–161, doi: [10.1016/j.amjsurg.2010.12.011](https://doi.org/10.1016/j.amjsurg.2010.12.011), indexed in Pubmed: [21658671](https://pubmed.ncbi.nlm.nih.gov/21658671/).
- Li GZ, Fairweather M, Wang J, et al. Cutaneous radiation-associated breast angiosarcoma: radicality of surgery impacts survival. *Ann Surg*. 2017; 265(4): 814–820, doi: [10.1097/SLA.0000000000001753](https://doi.org/10.1097/SLA.0000000000001753), indexed in Pubmed: [28267696](https://pubmed.ncbi.nlm.nih.gov/28267696/).
- Morgan EA, Kozono DE, Wang Q, et al. Cutaneous radiation-associated angiosarcoma of the breast: poor prognosis in a rare secondary malignancy. *Ann Surg Oncol*. 2012; 19(12): 3801–3808, doi: [10.1245/s10434-012-2563-4](https://doi.org/10.1245/s10434-012-2563-4), indexed in Pubmed: [22890593](https://pubmed.ncbi.nlm.nih.gov/22890593/).
- Bentzen SM, Agrawal RK, Aird EGA, et al. START Trialists' Group, START Trialists' Group. The UK Standardisation of Breast Radiotherapy (START) Trial B of radiotherapy hypofractionation for treatment of early breast cancer: a randomised trial. *Lancet*. 2008; 371(9618): 1098–1107, doi: [10.1016/S0140-6736\(08\)60348-7](https://doi.org/10.1016/S0140-6736(08)60348-7), indexed in Pubmed: [18355913](https://pubmed.ncbi.nlm.nih.gov/18355913/).
- Bartelink H, Horiot JC, Poortmans PM, et al. Impact of a higher radiation dose on local control and survival in breast-conserving therapy of early breast cancer: 10-year results of the randomized boost versus no boost EORTC 2881-10882 trial. *J Clin Oncol*. 2007; 25: 3259–3265, doi: [10.1200/JCO.2007.11.499.1](https://doi.org/10.1200/JCO.2007.11.499.1).
- Vicini FA, Winter K, Wong J, et al. Initial efficacy results of RTOG 0319: Three dimensional conformal radiation therapy (3D-CRT) confined to the region of the lumpectomy cavity for stage I/II breast carcinoma. *Int J Radiat Oncol Biol Phys*. 2008; 72(1): S3, doi: [10.1016/j.ijrobp.2009.06.067](https://doi.org/10.1016/j.ijrobp.2009.06.067).
- Yang WT, Hennessy BTJ, Dryden MJ, et al. Mammary angiosarcomas: imaging findings in 24 patients. *Radiology*. 2007; 242(3): 725–734, doi: [10.1148/radiol.2423060163](https://doi.org/10.1148/radiol.2423060163), indexed in Pubmed: [17325063](https://pubmed.ncbi.nlm.nih.gov/17325063/).
- O'Neill AC, D'Arcy C, McDermott E, et al. Magnetic resonance imaging appearances in primary and secondary angiosarcoma of the breast. *J Med Imaging Radiat Oncol*. 2014; 58(2): 208–212, doi: [10.1111/1754-9485.12100](https://doi.org/10.1111/1754-9485.12100), indexed in Pubmed: [24112469](https://pubmed.ncbi.nlm.nih.gov/24112469/).
- Hart J, Mandavilli S. Epithelioid angiosarcoma: a brief diagnostic review and differential diagnosis. *Arch Pathol Lab Med*. 2011; 135(2): 268–272, doi: [10.1043/1543-2165-135.2.268](https://doi.org/10.1043/1543-2165-135.2.268), indexed in Pubmed: [21284449](https://pubmed.ncbi.nlm.nih.gov/21284449/).
- Li N, Cusidó MT, Navarro B, et al. Breast sarcoma. A case report and review of literature. *Int J Surg Case Rep*. 2016; 24: 203–205, doi: [10.1016/j.ijscr.2016.04.033](https://doi.org/10.1016/j.ijscr.2016.04.033), indexed in Pubmed: [27281361](https://pubmed.ncbi.nlm.nih.gov/27281361/).
- Morgan MB, Swann M, Somach S, et al. Cutaneous angiosarcoma: a case series with prognostic correlation. *J Am Acad Dermatol*. 2004; 50(6): 867–874, doi: [10.1016/j.jaad.2003.10.671](https://doi.org/10.1016/j.jaad.2003.10.671), indexed in Pubmed: [15153886](https://pubmed.ncbi.nlm.nih.gov/15153886/).
- Maddox JC, Evans HL. Angiosarcoma of skin and soft tissue: a study of forty-four cases. *Cancer*. 1981; 48(8): 1907–1921, indexed in Pubmed: [7197190](https://pubmed.ncbi.nlm.nih.gov/7197190/).
- Nicolas MM, Nayar R, Yeldandi A, et al. Pulmonary metastasis of a post-radiation breast epithelioid angiosarcoma mimicking adenocarcinoma. A case report. *Acta Cytol*. 2006; 50(6): 672–676, doi: [10.1159/000326039](https://doi.org/10.1159/000326039), indexed in Pubmed: [17152281](https://pubmed.ncbi.nlm.nih.gov/17152281/).
- Tateishi U, Yamaguchi U, Seki K, et al. Bone and soft-tissue sarcoma: preoperative staging with fluorine 18 fluorodeoxyglucose PET/CT and conventional imaging. *Radiology*. 2007; 245(3): 839–847, doi: [10.1148/radiol.2453061538](https://doi.org/10.1148/radiol.2453061538), indexed in Pubmed: [18024454](https://pubmed.ncbi.nlm.nih.gov/18024454/).
- Allison KH, Yoder BJ, Bronner MP, et al. Angiosarcoma involving the gastrointestinal tract: a series of primary and metastatic cases. *Am J Surg Pathol*. 2004; 28(3): 298–307, indexed in Pubmed: [15104292](https://pubmed.ncbi.nlm.nih.gov/15104292/).
- Bar R, Netzer A, Ostrovsky D, et al. Abrupt tonsillar hemorrhage from a metastatic hemangiosarcoma of the breast: case report and literature review. *Ear Nose Throat J*. 2011; 90(3): 116–120, indexed in Pubmed: [21412741](https://pubmed.ncbi.nlm.nih.gov/21412741/).
- Baum JK, Levine AJ, Ingold JA. Angiosarcoma of the breast with report of unusual site of first metastasis. *J Surg Oncol*. 1990; 43(2): 125–130, indexed in Pubmed: [2406508](https://pubmed.ncbi.nlm.nih.gov/2406508/).

41. Lindford A, Böhlring T, Vaalavirta L, et al. Surgical management of radiation-associated cutaneous breast angiosarcoma. *J Plast Reconstr Aesthet Surg.* 2011; 64(8): 1036–1042, doi: [10.1016/j.bjps.2011.02.014](https://doi.org/10.1016/j.bjps.2011.02.014), indexed in Pubmed: [21377947](https://pubmed.ncbi.nlm.nih.gov/21377947/).
42. Al-Benna S, Poggemann K, Steinau HU, et al. Diagnosis and management of primary breast sarcoma. *Breast Cancer Res Treat.* 2010; 122(3): 619–626, doi: [10.1007/s10549-010-0915-y](https://doi.org/10.1007/s10549-010-0915-y), indexed in Pubmed: [20480227](https://pubmed.ncbi.nlm.nih.gov/20480227/).
43. Feigenberg SJ, Mendenhall NP, Reith JD, et al. Angiosarcoma after breast-conserving therapy: experience with hyperfractionated radiotherapy. *Int J Radiat Oncol Biol Phys.* 2002; 52(3): 620–626, indexed in Pubmed: [11849782](https://pubmed.ncbi.nlm.nih.gov/11849782/).
44. Palta M, Morris CG, Grobmyer SR, et al. Angiosarcoma after breast-conserving therapy: long-term outcomes with hyperfractionated radiotherapy. *Cancer.* 2010; 116(8): 1872–1878, doi: [10.1002/cncr.24995](https://doi.org/10.1002/cncr.24995), indexed in Pubmed: [20162708](https://pubmed.ncbi.nlm.nih.gov/20162708/).
45. Mark RJ, Poen JC, Tran LM, et al. Angiosarcoma. A report of 67 patients and a review of the literature. *Cancer.* 1996; 77(11): 2400–2406, doi: [10.1002/\(SICI\)1097-0142\(19960601\)77:11<2400::AID-CNCR32>3.0.CO;2-Z](https://doi.org/10.1002/(SICI)1097-0142(19960601)77:11<2400::AID-CNCR32>3.0.CO;2-Z), indexed in Pubmed: [8635113](https://pubmed.ncbi.nlm.nih.gov/8635113/).
46. Fayette J, Martin E, Piperno-Neumann S, et al. Angiosarcomas, a heterogeneous group of sarcomas with specific behavior depending on primary site: a retrospective study of 161 cases. *Ann Oncol.* 2007; 18(12): 2030–2036, doi: [10.1093/annonc/mdm381](https://doi.org/10.1093/annonc/mdm381), indexed in Pubmed: [17974557](https://pubmed.ncbi.nlm.nih.gov/17974557/).
47. Abraham JA, Hornicek FJ, Kaufman AM, et al. Treatment and outcome of 82 patients with angiosarcoma. *Ann Surg Oncol.* 2007; 14(6): 1953–1967, doi: [10.1245/s10434-006-9335-y](https://doi.org/10.1245/s10434-006-9335-y), indexed in Pubmed: [17356953](https://pubmed.ncbi.nlm.nih.gov/17356953/).
48. Patel SR, Vadhan-Raj S, Burgess MA, et al. Results of two consecutive trials of dose-intensive chemotherapy with doxorubicin and ifosfamide in patients with sarcomas. *Am J Clin Oncol.* 1998; 21(3): 317–321, indexed in Pubmed: [9626808](https://pubmed.ncbi.nlm.nih.gov/9626808/).
49. Issels RD, Lindner LH, Verweij J, et al. European Organization for the Research and Treatment of Cancer-Soft Tissue and Bone Sarcoma Group and the European Society for Hyperthermic Oncology. Effect of neoadjuvant chemotherapy plus regional hyperthermia on long-term outcomes among patients with localized high-risk soft tissue sarcoma: the EORTC 62961-ESHO 95 randomized clinical trial. *JAMA Oncol.* 2018; 4(4): 483–492, doi: [10.1001/jamaoncol.2017.4996](https://doi.org/10.1001/jamaoncol.2017.4996), indexed in Pubmed: [29450452](https://pubmed.ncbi.nlm.nih.gov/29450452/).
50. Forscher C, Mita M, Figlin R. Targeted therapy for sarcomas. *Biologics.* 2014; 8: 91–105, doi: [10.2147/BTT.S26555](https://doi.org/10.2147/BTT.S26555), indexed in Pubmed: [24669185](https://pubmed.ncbi.nlm.nih.gov/24669185/).
51. Young RJ, Woll PJ. Anti-angiogenic therapies for the treatment of angiosarcoma: a clinical update. *Memo.* 2017; 10(4): 190–193, doi: [10.1007/s12254-017-0365-x](https://doi.org/10.1007/s12254-017-0365-x), indexed in Pubmed: [29250195](https://pubmed.ncbi.nlm.nih.gov/29250195/).
52. Ray-Coquard IL, Domont J, Tresch-Bruneel E, et al. Paclitaxel Given Once Per Week With or Without Bevacizumab in Patients With Advanced Angiosarcoma: A Randomized Phase II Trial. *J Clin Oncol.* 2015; 33(25): 2797–2802, doi: [10.1200/JCO.2015.60.8505](https://doi.org/10.1200/JCO.2015.60.8505), indexed in Pubmed: [26215950](https://pubmed.ncbi.nlm.nih.gov/26215950/).
53. D'Adamo DR, Dickson MA, Keohan ML, et al. Phase II study of sorafenib in patients with metastatic or recurrent sarcomas. *J Clin Oncol.* 2009; 27(19): 3133–3140, doi: [10.1200/JCO.2008.20.4495](https://doi.org/10.1200/JCO.2008.20.4495), indexed in Pubmed: [19451436](https://pubmed.ncbi.nlm.nih.gov/19451436/).
54. Sleijfer S, Ray-Coquard I, Papai Z, et al. Pazopanib, a multikinase angiogenesis inhibitor, in patients with relapsed or refractory advanced soft tissue sarcoma: a phase II study from the European organisation for research and treatment of cancer-soft tissue and bone sarcoma group (EORTC study 62043). *J Clin Oncol.* 2009; 27(19): 3126–3132, doi: [10.1200/JCO.2008.21.3223](https://doi.org/10.1200/JCO.2008.21.3223), indexed in Pubmed: [19451427](https://pubmed.ncbi.nlm.nih.gov/19451427/).
55. Jagiello-Wieczorek E, Świtaj T, Jagielska B, et al. Pazopanib as new therapeutic option in therapy of advanced soft tissue sarcoma. *Onkol. Prak. Klin.* 2014; 10: 24–31.