

Termination of pacemaker-mediated tachycardia by a critically timed atrial extrasystole

S. Serge Barold¹, Roland Stroobandt², Frederic Van Heuverswyn², Bengt Herweg¹

¹Florida Heart Rhythm Institute, Tampa, Florida, USA

²Heart Center, University Hospital of Ghent, Ghent, Belgium

Pacemaker-mediated tachycardia (PMT) also called endless loop tachycardia is a macro-reentrant dual chamber pacemaker tachycardia conceptually similar to spontaneous reentrant supraventricular tachycardias (atrioventricular [AV] node reentrant tachycardia and orthodromic reciprocating tachycar-

dia). These spontaneous and PMTs share common mechanisms for initiation and termination by means of single critically timed atrial and ventricular extrasystoles [1–3]. Although it is well-known that a critically timed ventricular extrasystole can terminate PMT, it is strange that termination by a criti-

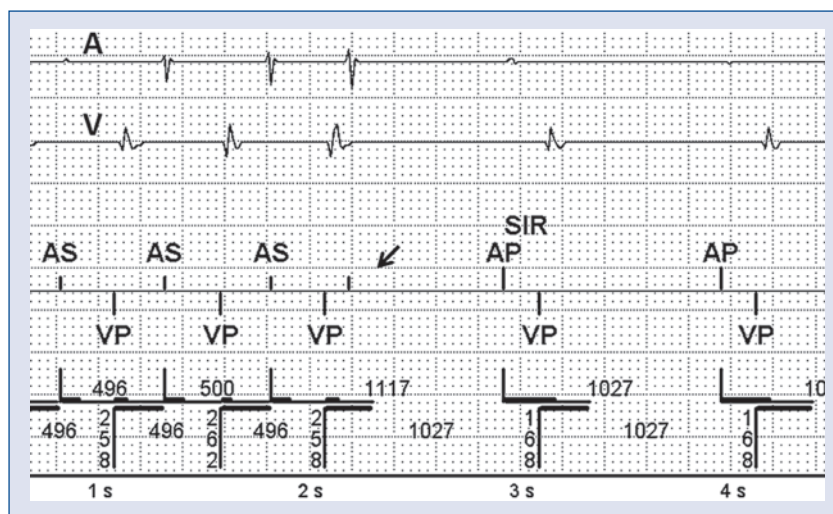


Figure 1. Termination of pacemaker-mediated tachycardia (PMT) by an atrial extrasystole. The tracing shows the simultaneously recorded atrial electrogram on top (A), and ventricular electrogram (V). The calibration for the atrial electrogram was 0.8 mm/mV. The device event markers are shown below the electrograms. In the marker recording, the vertical upward deflections represent atrial events, and the vertical downward deflections represent ventricular events. The beginning of this PMT was not captured in the stored memory. (Figure 2 shows an example of same PMT recorded at a different time). The device detects an atrial extrasystole in the postventricular refractory period (generating an unlabeled marker without symbolic designation). The atrial electrogram confirms the prematurity of the atrial extrasystole and its close resemblance to the configuration of the other atrial electrograms indicates that the signal or deflection is not artifactual. The prevailing sensor indicated interval is 1027 ms. The atrial paced event (AP) in the atrial electrogram are attenuated in this tracing and were mostly attenuated in the other stored recordings. The first atrial sensed event (AS) is associated with an attenuated atrial electrogram which occurred occasionally in the other stored recordings and they were probably caused by changes in body position. In any case, the interpretation of the recordings remains valid even if some kind of device malfunction interfered with the recording of the atrial electrogram. The two horizontal lines of varying thickness depict the duration of the refractory and blanking periods with the atrial intervals above the ventricular ones; VP — ventricular paced event; SIR — sensor-induced rate.

Address for correspondence: S. Serge Barold, MD, Florida Heart Rhythm Institute, Tampa, Florida, USA, tel: 813 891 1922, e-mail: ssbarold@aol.com

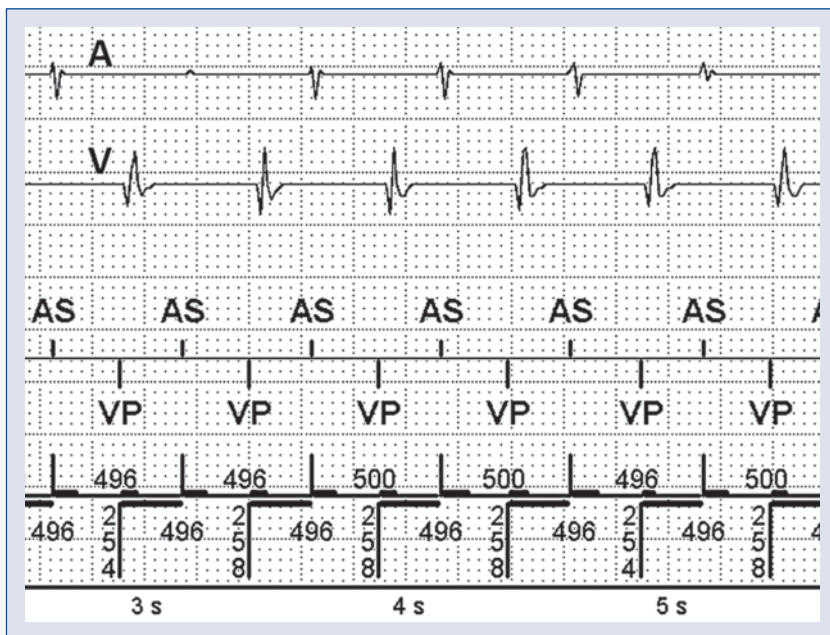


Figure 2. Pacemaker-mediated tachycardia. Same arrangement as in Figure 1. See Figure 1 and text for details.

cally timed atrial extrasystole has rarely been reported but predictable electrophysiologically [3]. In this respect, the previously reported case of PMT termination by an atrial extrasystole was interpreted indirectly by using only the telemetered marker channel in contrast to the case herein where the diagnosis was certain on the basis of the telemetered atrial electrogram (Figs. 1, 2). The PMT (rate about 120 ppm) occurred in a patient with a DDDR ICD (Current Accel DR 2215-36, St. Jude Medical, Sylmar, California) with the following parameters: lower rate 50 ppm, sensor on, upper tracking rate = sensor-driven upper rate 120 ppm (upper rate interval = 500 ms), paced AV delay 170 ms, sensed AV delay 130 ms, and prevailing postventricular atrial refractory period (PVARP) 235 ms (Figs. 1, 2). The pacing and lead impedances were stable and normal. In our patient, retrograde ventriculoatrial conduction was always constant at 240–250 ms at various ventricular pacing rates. Atrial depolarization from the atrial extrasystole fell within the unblanked portion of the PVARP where it was detected by the atrial channel, but could

not start an AV delay (Fig. 1). In this way, the atrial extrasystole preempted the expected atrial activation so that retrograde ventriculoatrial conduction from the ventricular paced beat encountered atrial myocardial refractoriness (from the extrasystole). Therefore ventriculoatrial conduction was abolished [3]. This sequence is similar to the termination of spontaneous AV node reentrant tachycardia and orthodromic reciprocating by an atrial extrasystole.

Conflict of interest: none declared

References

1. Frumin H, Furman S. Endless loop tachycardia started by an atrial premature complex in a patient with a dual chamber pacemaker. *J Am Coll Cardiol*, 1985; 5: 707–710.
2. Barold SS. Timing cycles and operational characteristics of pacemakers. In: Ellenbogen K, Kay N, Wilkoff B eds. *Clinical cardiac pacing and defibrillation*. 2nd Ed. W.B. Saunders, Philadelphia, PA 2000: 727–825.
3. Barold SS. Termination of endless loop tachycardia by an atrial extrasystole. *Pacing Clin Electrophysiol*, 2001; 24: 250–251.