

Typical atrial flutter with atypical flutter wave morphology due to abnormal interatrial conduction

Tadanobu Irie, Yoshiaki Kaneko, Tadashi Nakajima, Akihiro Saito, Masaki Ota, Toshimitsu Kato, Takafumi Iijima, Mio Tamura, Hiroaki Kobayashi, Toshio Ito, Mamoru Manita, Masahiko Kurabayashi

Department of Medicine and Biological Science, Gunma University
Graduate School of Medicine, Maebashi, Gunma, Japan

Abstract

We report a case of typical counterclockwise atrial flutter (AFL) with conduction block from right to left atrium along the coronary sinus (CS) musculature, confirmed by discontinuous CS activation sequence during pacing near the ostium and differential right atrial pacing. AFL was associated with an atypical flutter wave morphology, due to the detour of the activation wavefront from right to left atrium via alternate interatrial electrical connections, such as Bachmann's bundle, the interatrial septum, or both. (Cardiol J 2011; 18, 4: 450–453)

Key words: atrial flutter, flutter wave, interatrial connection, diagnostic pacing, coronary sinus musculature

Introduction

Typical atrial flutter (AFL) is a macro-re-entrant tachycardia rotating counterclockwise (CCW) in the right atrial (RA) wall and across the tricuspid annulus (TA)-inferior vena cava (IVC) isthmus. During ongoing AFL, the left atrium (LA) is activated from the RA over one or more interatrial connections such as the coronary sinus (CS) musculature, Bachmann's bundle and the interatrial septum [1, 2]. The LA activation sequence is a major determinant of the characteristic saw tooth-like morphology of AFL, with predominantly negative polarity of the flutter waves in the inferior and V6 leads of the surface electrocardiogram (ECG), and positive waves in lead V1 [3]. We describe a patient presenting with a typical CCW rotation of AFL and conduction block through the CS ostial interatrial connection, producing an atypical morphology of the AFL waves.

Case report

A 75 year-old woman was referred to our hospital for catheter ablation of paroxysmal AFL. The 12-lead ECG during tachycardia showed negative flutter waves in leads II, III, aVF and V5–V6, and positive flutter waves in V1–V2, similar to those observed in typical CCW AFL, although of unusually low amplitude in all leads (Fig. 1A). After having given written informed consent, the patient underwent electrophysiological study. A 7 F decapolar electrode (Irvine Biomedical, Irvine, CA, USA) with 5-mm inter-electrode spacing was placed in the CS from the right subclavicular vein, and positioned with its proximal poles (CS 9–10) at the ostium and distal poles (CS 1–2) in a distal, left lateral position confirmed by injection of contrast material during fluoroscopy. A 7 F, 20-pole Halo catheter (Irvine Biomedical, Irvine, CA, USA) with 2-20-2 mm inter-electrode spacing, was placed

Address for correspondence: Yoshiaki Kaneko, MD, PhD, Department of Medicine and Biological Science, Gunma University Graduate School of Medicine, 3-39-22 Showa, Maebashi, Gunma, 371-8511 Japan, fax: +81 27 220 8158, e-mail: kanekoy@gunma-u.ac.jp

Received: 21.11.2010

Accepted: 10.01.2011

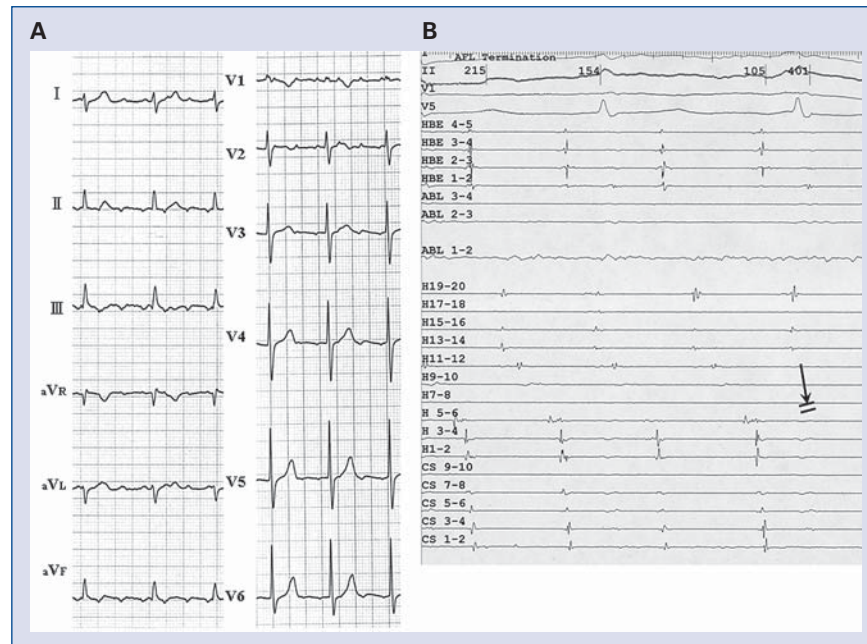


Figure 1. Surface and intracardiac electrocardiographic recordings during ongoing atrial flutter; **A.** Low-amplitude flutter wave on 12-lead electrocardiogram; **B.** Linear ablation in the inferior vena cava (IVC)-tricuspid annulus (TA) isthmus terminated atrial flutter (AFL), which ended with the atrial electrogram in H11–12 (solid arrow and double line), indicating that the line of ablation was between H11–12 and H13–14; I, II, V1, V5 — surface electrocardiographic leads; HBE4–5 to HBE1–2 — proximal to distal His-bundle recordings; ABL1–2 and 3–4 — distal and proximal ablation catheter recordings; H19–20 to H1–2 — proximal to distal Halo catheter recordings; CS9–10 to CS1–2 — proximal to distal coronary sinus recordings.

along the TA, with the distal electrodes (H1–2) placed in the mid segment of the CS, and the H5–H6 electrodes at the ostium of the CS. A quadri-polar electrode catheter was placed in the His-bundle region. The atrial activation along the TA during ongoing tachycardia at a cycle length of 268 ms was CCW, and entrainment pacing from the IVC-TA isthmus, anterolateral or septal wall along the TA, showed a post-pacing interval equal to the tachycardia cycle length, confirming the diagnosis of typical CCW AFL. Recording of atrial activation along the CS was proximal to distal, with a short interval between the proximal and distal atrial deflections (Fig. 1B). Linear radiofrequency ablation blocked conduction across the IVC-TA isthmus, terminated AFL, and restored sinus rhythm (Fig. 1B). Differential pacing from the low septal and low lateral RA confirmed the creation of bidirectional isthmus block.

To test the hypothesis that the low AFL waves amplitude and atypical atrial activation sequence along the CS recordings during apparently typical CCW AFL was due to LA propagation of the wavefront modified by abnormal conduction across inter-

atrial connections, we paced alternatively from the CS ostium and from the right side of the interatrial septum in search of interatrial conduction at the ostium of the CS. During pacing from near the ostium of the CS, the wavefront propagating from the isthmus to the lateral RA was blocked at the IVC-TA isthmus line of ablation, while the wavefront propagating from the isthmus to the CS was blocked at the proximal CS (Fig. 2A), suggesting that conduction across the interatrial electrical connections at the ostium of the CS was blocked. Furthermore, the interval measured from the pacing spike to the mid CS (H1–2), distal to the site of the presumed conduction block, was 75 ms (Fig. 2A), whereas during pacing from the interatrial septum, the conduction interval from pacing spike to the mid CS (H1–2) was 30 ms (Fig. 2B). Therefore, although the anatomical distance between each pacing site and the mid CS (H1–2) was nearly identical (Fig. 2C), the conduction time between the CS ostium and mid CS (H1–2) was longer than between the interatrial septum and mid CS (H1–2), strengthening the suggestion of an absence of interatrial connection at the ostium of the CS.

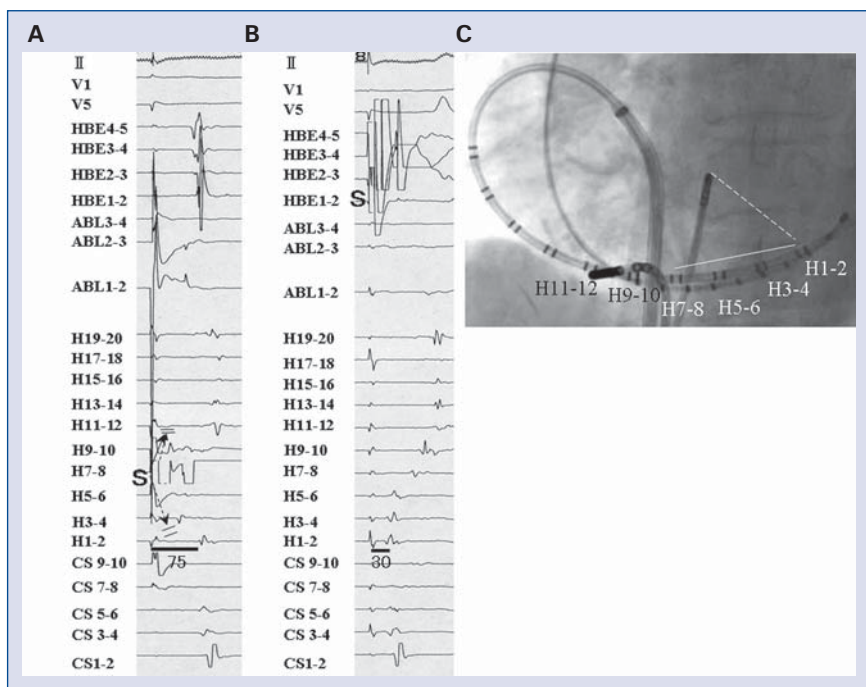


Figure 2. Intracardiac electrograms during pacing from near the ostium of the coronary sinus (CS) (A) and right-sided interatrial septum (B). Catheter position during pacing from near the ostium of the CS and right-sided interatrial septum, in left anterior oblique fluoroscopic view (C); A. During pacing from near the ostium of the CS (H7–8), the wavefront propagating in an isthmus-to-lateral-left atrium direction (solid arrow) was interrupted at the isthmus line of ablation, between H9–10 and H11–12, and the free wall of the right atrium, recorded from H11–12 to H19–20, was activated with a delay. The wavefront propagated in an isthmus-to-CS direction (dashed arrow) was interrupted between H3–4 and H1–2 in the proximal CS. Horizontal bars and numbers indicate the conduction times measured from the pacing spike (S) to the atrial deflection in the mid CS (H1–2); B. Pacing from HBE1–2, on the right side of the interatrial septum, near the bundle of His; C. Solid and dashed lines show the nearly identical distances between the pacing sites, H7–8 and HBE1–2, and the mid CS (H1–2); abbreviations are as in Figure 1.

Discussion

In this patient, who presented with typical CCW AFL and atypical flutter wave morphology, conduction block across the interatrial connection near the ostium of the CS was confirmed by: 1) pacing near the ostium while recording activation between the IVC-TA isthmus and the mid CS; and 2) pacing alternatively from the CS ostium and from the right side of the interatrial septum, sites that are nearly equidistant from the mid CS.

These pacing maneuvers respectively showed: 1) block of wavefront propagation at the CS ostium toward the distal CS; and 2) a distinctly longer conduction time between ostium and mid CS than between the interatrial septum and mid CS, despite the nearly equal anatomical distance between each pacing site and the mid CS.

Previous anatomical studies have shown that the CS musculature is continuous with the RA at the ostium and is connected to the LA myocardium by multiple muscular strands [4]. In recent clinical

studies of the earliest site of LA activation during sinus rhythm, Bachmann’s bundle and the CS musculature were found to play a major role in the right to left interatrial activation [5, 6]. However, the delayed activation of the CS does not systematically indicate conduction block over the CS musculature, since during sinus rhythm the infero-medial RA, including the ostium of the CS and its muscular fibers, is often activated late. In fact, in some cases of delayed activation of the CS during sinus rhythm, pacing from the ostium of the CS only can unmask the transeptal propagation of the wavefront from RA to LA over the CS musculature [7]. Thus, activation mapping in the LA during sinus rhythm, as performed in previous studies [5, 6], cannot confirm the existence of true conduction block over the CS musculature. To the best of our knowledge, there has been no previous description of the electrophysiological characteristics diagnostic of conduction block over the CS musculature in humans.

During ongoing typical CCW AFL, the LA is an ‘innocent bystander’ activated predominantly

from the CS ostium, and its activation sequence determines the flutter waves' morphology [3]. Zrenner et al. [8] reported a case of typical CCW AFL where the ablation of the CS ostial area during ongoing AFL changed the flutter waves' polarity without changing the RA activation sequence. Ashino et al. [9] reported two patients with typical CCW AFL in whom spontaneous changes in the LA activation sequence produced marked changes in the flutter wave polarity without changes in the RA activation sequence. Yan et al. [10] observed an atypical flutter wave morphology in a significant subset of patients with typical CCW AFL, associated with atypical activation of the CS musculature. These reports suggested that alterations in the interatrial connections play a role in the genesis of atypical manifestations of typical CCW AFL, although they, in contrast to our own observations, did not show the presence of conduction block over these connections.

Conclusions

The atypical morphology of the flutter waves and fused CS activation observed in our case of apparently typical CCW AFL can be explained by a detour of the activation wavefront from RA to LA via alternate interatrial connections, such as Bachmann's bundle, the interatrial septum, or both.

Acknowledgements

The authors do not report any conflict of interest regarding this work.

References

1. Rodriguez LM, Timmermans C, Nabar A, Hofstra L, Wellens HJ. Biatrial activation in isthmus-dependent atrial flutter. *Circulation*, 2001; 104: 2545–2550.
2. Marine JE, Korley VJ, Obioha-Ngwu O et al. Different patterns of interatrial conduction in clockwise and counterclockwise atrial flutter. *Circulation*, 2001; 104: 1153–1157.
3. Oshikawa N, Watanabe I, Masaki R et al. Relationship between polarity of the flutter wave in the surface ECG and endocardial atrial activation sequence in patients with typical counterclockwise and clockwise atrial flutter. *J Interv Card Electrophysiol*, 2002; 7: 215–223.
4. Chauvin M, Shah DC, Haïssaguerre M, Marcellin L, Brechenmacher C. The anatomic basis of connections between the coronary sinus musculature and the left atrium in humans. *Circulation*, 2000; 101: 647–652.
5. Lemery R, Birnie D, Tang AS et al. Normal atrial activation and voltage during sinus rhythm in the human heart: An endocardial and epicardial mapping study in patients with a history of atrial fibrillation. *J Cardiovasc Electrophysiol*, 2007; 18: 402–408.
6. Tapanainen JM, Jurkko R, Holmqvist F et al. Interatrial right-to-left conduction in patients with paroxysmal atrial fibrillation. *J Interv Card Electrophysiol*, 2009; 25: 117–122.
7. Lemery R, Soucie L, Martin B, Tang AS, Green M, Healey J. Human study of biatrial electrical coupling: Determinants of endocardial septal activation and conduction over interatrial connections. *Circulation*, 2004; 110: 2083–2089.
8. Zrenner B, Ndrepepa G, Karch M, Schneider M, Schmitt C. Block of the lower interatrial connections: insight into the sources of electrocardiographic diversities in common typical atrial flutter. *Pacing Clin Electrophysiol*, 2000; 23: 917–920.
9. Ashino S, Watanabe I, Okumura Y, Okubo K, Saito S. Change in atrial flutter morphology — insight into the sources of electrocardiographic variants in common atrial flutter. *Pacing Clin Electrophysiol*, 2007; 30: 1023–1026.
10. Yan SH, Cheng WJ, Wang LX, Chen MY, Hu HS, Xue M. Mechanisms of atypical flutter wave morphology in patients with isthmus-dependent atrial flutter. *Heart Vessels*, 2009; 24: 211–218.