

A rare form of trifascicular block with intermittent complete atrioventricular block in a patient with Chagas disease

Francisco Femenia¹, Alejandro Cuesta², Arce Mauricio¹

¹Unidad de Arritmias, Departamento de Cardiología, Hospital Español de Mendoza, Argentina

²Servicio de Cardiología, Hospital de Clínicas, Facultad de Medicina, UDELAR, Montevideo, Uruguay

Abstract

Trifascicular block, which consists of impaired conduction in the three main fascicles of the ventricular conduction system, may progress to high-grade or complete atrioventricular block. Exceptionally, it is possible to register in the same patient paroxysmal alternating atrioventricular block and bilateral bundle branch block. This is the electrocardiogram of a male, 60 year-old patient coming from an endemic area, with positive serology for Chagas disease, with the exclusively dromotropic form (there are no signs of cardiac muscle involvement), manifest by repetitive pre-syncope and syncope episodes. (Cardiol J 2009; 16, 6: 582–584)

Key words: trifascicular block, complete atrioventricular block

Electrocardiographic description

This is the 12-lead electrocardiogram (ECG) of a 60 year-old male, from a Chagas disease endemic area and with positive serology for Chagas disease. He presented with exclusively dromotropic form (there are no signs of cardiac muscle involvement), only symptomatic by repetitive pre-syncope and syncopal episodes. The baseline 12-lead ECG (Fig. 1A) shows a probable intraventricular trifascicular block by the association of first-degree atrioventricular (AV) block (PR interval \geq 210 ms), complete right bundle branch block (RBBB) and left posterior fascicular block (LPFB).

In the presence of first-degree AV block, the dromotropic disorder cannot be precisely located (i.e. in the AV node, supra-His, or in the intraventricular conduction system, intra or infra-His). In the latter, the PR interval prolongation (first-degree AV block) occurs by partial dromotropic impediment in the left anterior fascicle (LAF) [1]. The

term ‘trifascicular block’ should be used to designate cases in which RBBB with left anterior fascicular block (LAFB) and LPFB are observed in the same patient. The diagnosis of possible trifascicular block is suggested in patients with bifascicular block and incomplete AV block, in which the His bundle electrogram shows prolongation of the HV interval [2].

During 24-hour Holter monitoring, the patient presented pre-syncope and syncope, and correlation with paroxysmal complete AV block and alternating bundle branch block, suggesting a severe involvement of the intraventricular conduction (Fig. 1B). Two different QRS morphologies can be observed in the Holter recording. The first beat of the first strip and the last three beats of the second strip have the same morphology and conduction disorder as the 12-lead ECG. The rest of the QRS complexes have left bundle branch block morphology that could be explained by two different mechanisms. It could be due to an alternating bundle

Address for correspondence: Francisco Femenia, MD, Unidad de Arritmias, Departamento de Cardiología, Hospital Español de Mendoza, Argentina, Av. San Martín 965, Godoy Cruz, Mendoza, Argentina, CP: 5501, tel./fax: 54 261 4490341, e-mail: femeniafavier@hotmail.com

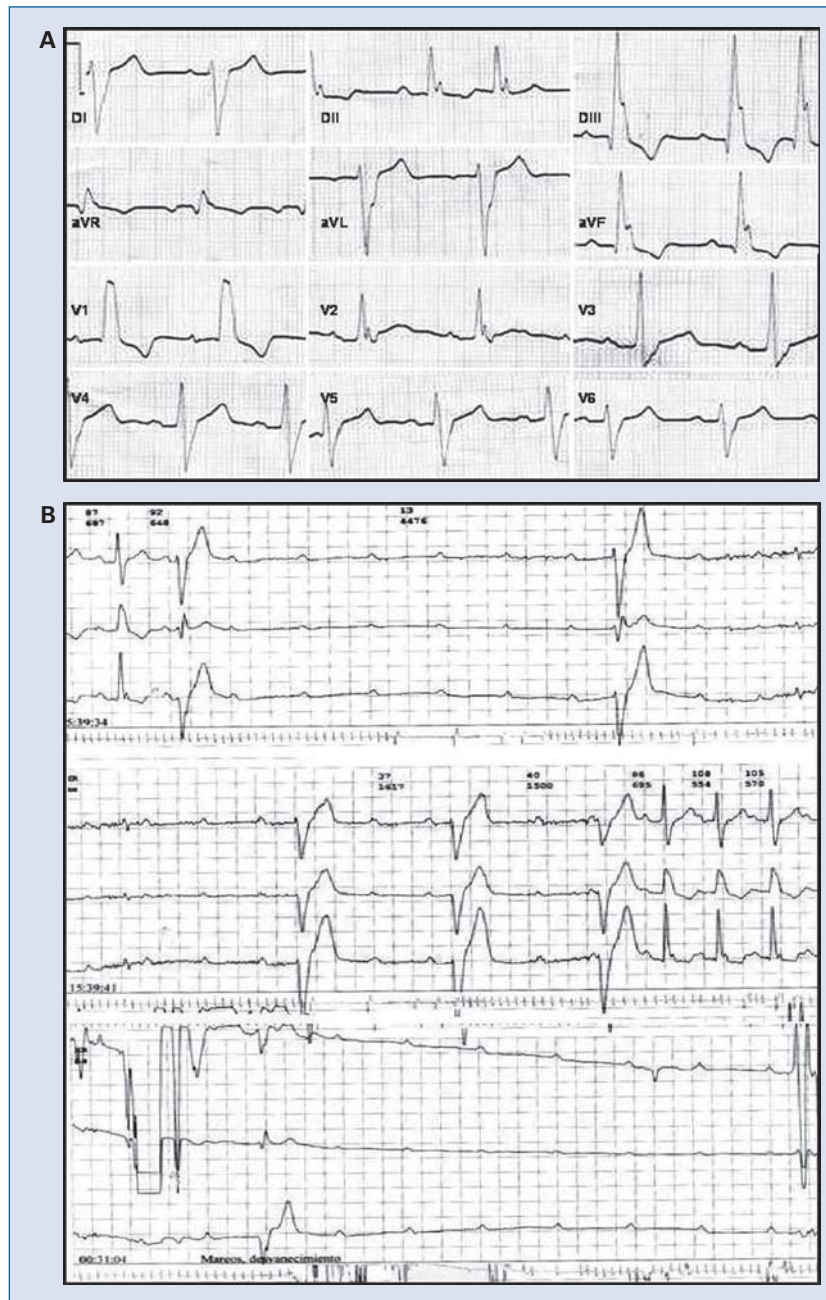


Figure 1. A. Electrocardiograms description: First-degree atrioventricular (AV) block: PR interval of 260 ms. Several typical criteria of left posterior fascicular block are present: right axis deviation (frontal plane axis $+140^\circ$), rS type complexes in DI and aVL, qR pattern in DII, DIII and aVF, notch in the descending limb of the R wave in inferior leads, voltage of R DIII $>$ DII, R wave in DIII $>$ 15 mm, R-peak time or intrinsic deflection in aVF \geq 45 ms. Complete right bundle branch block: QRS duration $>$ 120 ms, monophasic R wave in V1, intrinsic deflection in V1 $>$ 70 ms, ventricular repolarization (ST-T) opposite to greater final deflection of QRS with asymmetrical T wave, final broad S wave in left leads I, aVL, V5 and V6 with a duration greater than 40 ms; **B.** Holter description: Paroxysmal complete AV block with several P waves not followed by ventricular complexes. After several seconds, a very slow and irregular ventricular rhythm appears with a wide QRS complex different from the original. Escape rhythm: No portion of the supra-hissian tissue or the left anterior fascicle was able to establish an escape rhythm so as to maintain the QRS morphology. These different complexes have a left bundle branch block (LBBB) morphology. They can be originated at any place of the Purkinje system of the right ventricle. In this case, the rhythm should be slow but regular. They can be originated in some P waves conducted to the ventricles with LBBB. In this case, the patient is showing an alternating bundle branch block. And so AV block due to trifascicular block can be concluded. Both explanations means there is severe damage to the intraventricular conduction system.

branch block, or it could also be a very unstable and slow rhythm escape coming from the distal right ventricle. Both explanations imply severe damage to the intraventricular specific conduction system, and a permanent pacemaker should be implanted.

Points to ponder

In patients with chronic Chagasic heart disease, there are forms of the disease that affect almost exclusively the electrical conduction system. These are the so-called “exclusively dromotropic forms” [3]. Immunoregulation alterations may be, in part, the cause of this disorder [4], as well as microvascular dysfunction with myocardial ischemia and alterations in the autonomous nervous system [5]. The ECG allows recognizing the alterations originated by the vulnerability of the specialized conduction tissue and correlates very well with the long term prognosis of the disease. The right bundle and the anterior fascicle of the left bundle are the most vulnerable ones. They are affected in more than 50% of cases of chronic Chagasic heart disease [1]. The posterior fascicle of the left branch (LPF) is affected very rarely (< 3%), and its damage indicates a worse prognosis as a result of larger myocardial damage. It usually evolves into complete AV block, located in the infra-His region [6]. The reasons why the LAF is more affected than the LPF are: **anatomical**: smaller diameter (LAF: 3 mm, LPF: 6 mm) and greater extension (LAF: 35 mm, LPF: 30 mm); **electrophysiological**: as a consequence of its greater extension and lesser diameter, the depolarization and repolarization of LAF is slower than LPF; **vascular**: LPF is always irrigated

by the two systems of the anterior descending artery and right coronary artery; and **topographic**: the LPF runs through a more protected area, with less pressure mechanic impact.

Patients with positive serology for Chagas disease who have intraventricular conduction abnormalities have a worse prognosis [6]. It has never been demonstrated that the presence of a LPFB results in higher risk. Considering the aforementioned differences between LPF and LAF, it remains as attractive hypothesis.

Acknowledgements

The authors do not report any conflict of interest regarding this work.

References

1. Elizari MV, Acunzo RS, Ferrero HM. Hemiblocks revisited. *Circulation*, 2007; 115: 1154–1163.
2. Friedman HH. Diagnostic electrocardiography and vectorcardiography. Chapter 11: Ventricular conduction defects. 3rd Ed. McGraw-Hill Book Company, New York 1985: 219.
3. Dubner S, Schapachnik E, Riera AR et al. Chagas disease: State-of-the-art diagnosis and management. *Cardiol J*, 2008; 15: 493–504.
4. Rosenbaum MB, Chiale PA, Schejtman D et al. Antibodies to beta-adrenergic receptors disclosing agonist-like properties in idiopathic dilated cardiomyopathy and Chagas' heart disease. *J Cardiovasc Electrophysiol*, 1994; 5: 367–375.
5. Morris SA, Tanowitz MB, Wittner M et al. Pathophysiological insights into the myocardial pathology of Chagas disease. *Circulation*, 1990; 82: 1900–1909.
6. Barbosa EC, Ginefra P, da Rocha PJ et al. Significance of prolonged PR interval in patients with His bundle branch block, bifascicular type. *Arq Bras Cardiol*, 1991; 56: 355–358.