

Electrocardiographical clues to a mechanism of pre-syncope

William F. McIntyre¹, Martin S. Green²

¹Queen's University, Kingston, Ontario, Canada

²University of Ottawa Heart Institute, Ottawa, Ontario, Canada

Electrocardiography description

This is the case of a 73 year-old female who presented to clinic complaining of pre-syncope. A 24-hour Holter monitor revealed multiple episodes of 2–2.5 s pauses associated with non-conducted P waves (Fig. 1). Careful examination of the

rhythm strip revealed high-frequency, low-amplitude signal during and immediately prior to the pauses. This high-frequency low-amplitude signal was particularly marked during the pause. The PR interval was observed to lengthen slightly in the beats prior to the pause and there was slight slowing of the sinus rate.

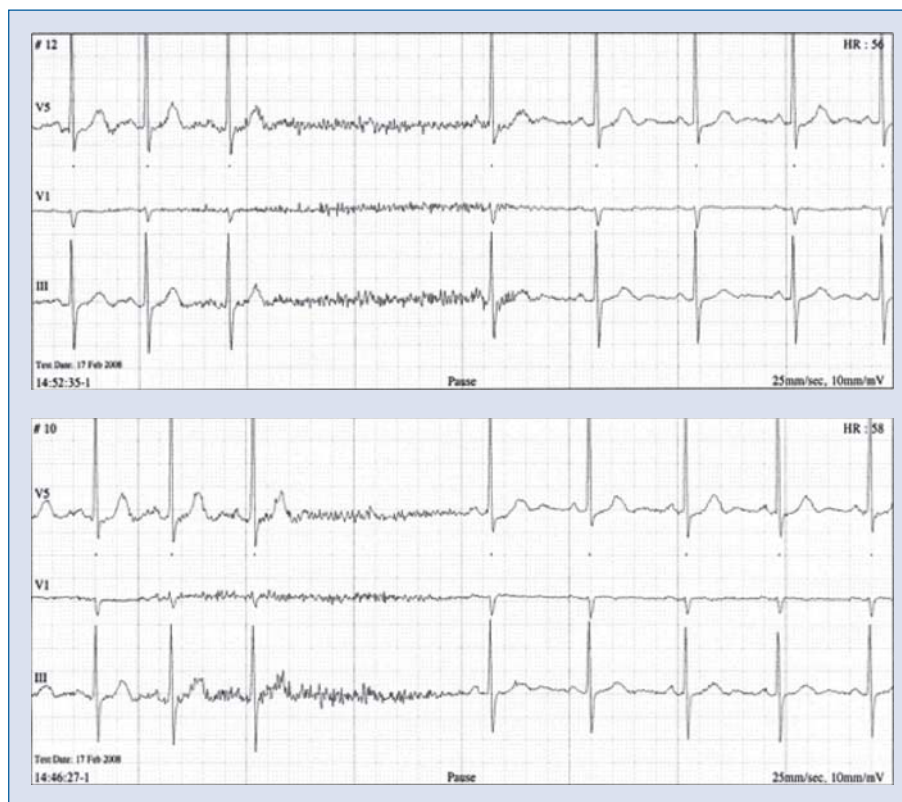


Figure 1. Holter monitor electrocardiogram strips from a patient with pre-syncope. Note the rapid, sharp, low-amplitude signal during and immediately prior to the pause.

Address for correspondence: Dr. Martin Green, MD, Professor of Medicine (Cardiology), University of Ottawa Heart Institute, 40 Ruskin, Ottawa, ON, K1Y 4W7, Canada, tel: 613 761 4820, fax: 613 761 4549, e-mail: mgreen@ottawaheart.ca

Points to ponder

The high-frequency low-amplitude signal is likely due to muscle activity, which is accompanied by an increase in vagal tone, leading to inhibition of the atrio-ventricular (AV) node. This vagal input manifests on the electrocardiography as a lengthening of the PR interval progressing to AV block [1].

Careful history revealed that this 60 pack-year smoker experienced frequent coughing spells, which could be correlated to her symptomatic events.

Cough syncope is a recognized phenomenon where coughing spells have been related to syncope and/or pre-syncope events. Although the exact pathophysiology is unclear, changes in vagal tone [1], neural reflexes [2] and intrathoracic pressure [3] have been implicated in mechanisms of brain hypoperfusion leading to syncope. It is suggested that this patient's coughing spells were

causing AV node inhibition, leading to pauses and AV block.

We wish to highlight the importance of careful examination of the timing of the muscle 'artifact' in suggesting a mechanism for this AV nodal block.

Acknowledgements

The authors do not report any conflict of interest regarding this work.

References

1. Zyśko D, Gajek J, Koźluk E, Mazurek W. Electrocardiographic characteristics of atrioventricular block induced by tilt testing. *Europace*, 2009; 11: 225–230.
2. Benditt DG, Samniah N, Pham S et al. Effect of cough on heart rate and blood pressure in patients with "cough syncope". *Heart Rhythm*, 2005; 2: 807–813.
3. Dhar R, Duke RJ, Sealey BJ. Cough syncope from constrictive pericarditis: A case report. *Can J Cardiol*, 2003; 19: 295–296.