

Multiple coronary-left ventricular fistulae associated with apical hypertrophic cardiomyopathy: Coronary angiogram compared to coronary scan and cardiac magnetic resonance scan

François Roubille^{1*}, Antoine Micheau^{2*}, Hélène Vernhet-Kovacsik²

¹Cardiology Department, Arnaud de Villeneuve University Hospital, Montpellier, France

²Cardiovascular Imagery Department, Arnaud de Villeneuve University Hospital, Montpellier, France

We report the case of a 74 year-old woman admitted for coronary angiogram because of widespread electrocardiographic repolarization abnormalities. Her past medical history was mainly paroxysmic atrial fibrillation. Her cardiovascular risk factors were age and smoking.

Echocardiography revealed apical left ventricular hypertrophy. Physical examination was normal.

Surprisingly, the coronary angiogram revealed multiple fistulae from both left and right coronary system (Fig. 1A, B). These fistulae were so deve-

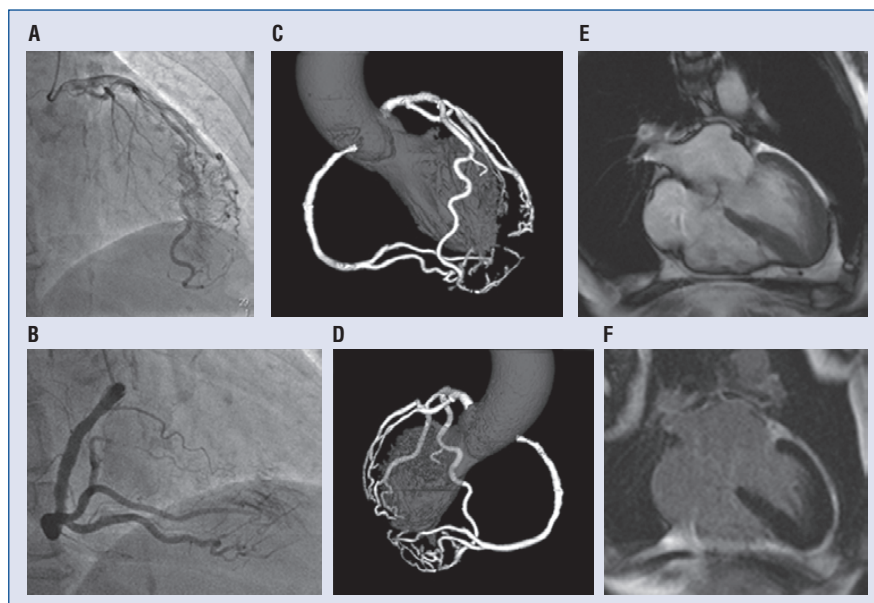


Figure 1. **A.** Coronary angiogram: multiple fistulae originating from the left coronary system (right anterior oblique projection); **B.** Coronary angiogram: multiple fistulae originating from the right coronary system (right anterior oblique projection); **C.** Coronary scan: multiple fistulae originating from both left and right coronary system (right anterior oblique projection); **D.** Coronary scan: multiple fistulae originating from both left and right coronary system; **E.** Magnetic resonance scan (cine-loop) showing apical hypertrophic cardiomyopathy; **F.** Magnetic resonance scan (late-enhancement): no late enhancement was noticed on left ventricle.

Address for correspondence: Dr. François Roubille, MD, PhD, Arnaud de Villeneuve University Hospital, Cardiology Department, 371 Avenue du doyen Gaston GIRAUD, 34295 Montpellier, France, e-mail: f-roubille@chu-montpellier.fr

*Both authors have provided equal contribution to this work.

Received: 21.02.2011

Accepted: 30.05.2011

loped that a pseudo-left ventricle angiogram could be performed. A coronary scan confirmed these conclusions (Fig. 1C, D). A magnetic resonance scan evidenced apical hypertrophy (Fig. 1E). This magnetic resonance scan showed neither infarct nor fibrosis (no late enhancement (Fig. 1F).

We present here a rare case of multiple coronary artery-left ventricular fistulae, associated with apical hypertrophic cardiomyopathy with electrocardiographic abnormalities. This feature has been all the more rarely described, as more than 75% do

not lead to any symptoms. Most fistulae are congenital, but others can be induced by myocardial infarct. Here, apical hypertrophic cardiomyopathy could be involved in microcirculation abnormalities, although the physiopathology is not well understood.

Acknowledgements

The authors do not report any conflict of interest regarding this work.