

## Long term observation of thin-cap fibroatheroma by optical coherence tomography

Paweł Tyczyński<sup>1,2</sup>, Cristina Moreno-Ambroj<sup>1</sup>, Liviu Ghilencea<sup>1</sup>,  
Anna Barbara Witkowska<sup>1</sup>, Carlo Di Mario<sup>1,3</sup>

<sup>1</sup>The Royal Brompton Hospital, London, UK

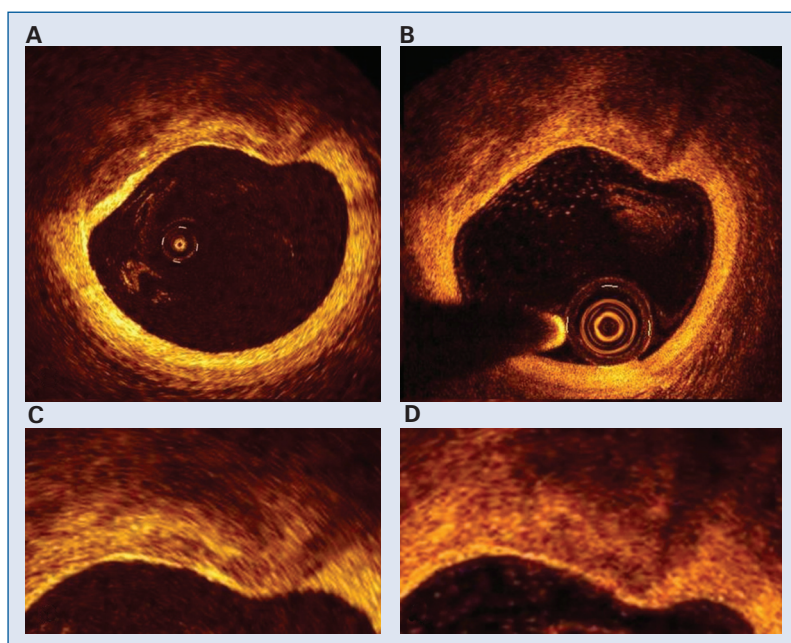
<sup>2</sup>Institute of Cardiology, Warsaw, Poland

<sup>3</sup>Imperial College, London, UK

Plaque rupture with subsequent formation of occlusive thrombus accounts for about 70% of cases of acute coronary syndrome (ACS). Plaques characterized by a thin fibrous cap ( $< 65 \mu\text{m}$ ) overlying a large lipid rich necrotic core have been associated with ACS in *in-vivo* and post-mortem studies and referred to as thin-cap fibroatheroma (TCFA) [1]. As a less prevalent finding, TCFA has also been identified in non-culprit arteries of ACS patients and in stable angina patients [2]. There is limited information about the natural history of this phenomenon.

Neither conventional angiography nor intravascular ultrasound have sufficient resolution to detect TCFA. Optical coherence tomography (OCT), with its near-microscopic resolution, is able to detect TCFA and offers detailed insight into its morphology.

We present a patient with non-insulin dependent diabetes mellitus and stable angina pectoris where OCT detected TCFA in the left circumflex artery during the initial OCT examination (Fig. 1A), nine months after drug eluting stent implantation in a more distal segment. Total cholesterol was



**Figure 1.** **A.** An eccentric, lipid rich plaque with evidence of necrotic core and an overlying  $40 \mu\text{m}$  thick fibrous cap at 2 o'clock and calcific deposits at 11–12 o'clock (image from M3 optical coherence tomography model); **B.** Unchanged plaque morphology at 15 months follow-up (image from C7 optical coherence tomography model); **C, D.** Magnification of the "A" and "B" images.

**Address for correspondence:** Prof. Carlo Di Mario, MD, PhD, FRCP, Consultant Cardiologist, Royal Brompton Hospital, Sydney Street, London SW3 6NP, UK, tel: +44 (0) 207 3518616, fax: +44 (0) 207 3518104, e-mail: C.DiMario@rbht.nhs.uk

3.7 mMol/L under treatment with 40 mg of atorvastatin. Repeat OCT images 15 months later showed no changes in fibrous cap thickness or lipidic plaque morphology in corresponding cross-sections (Fig. 1B). These images suggest that TCFA can remain stable over time under good pharmacological control of risk factors including cholesterol.

### Acknowledgements

The authors do not report any conflict of interest regarding this work.

Dr Paweł Tyczyński, trainee at the Institute of Cardiology in Warsaw, was the recipient of the training fellowship 2008 of the European Association of Percutaneous Cardiovascular Interventions.

### References

1. Virmani R, Burke AP, Farb A, Kolodgie FD. Pathology of the vulnerable plaque. *J Am Coll Cardiol*, 2006; 47: C13–C18.
2. Rodriguez-Granillo GA, Garcia-Garcia HM, Mc Fadden EP et al. In vivo intravascular ultrasound-derived thin-cap fibroatheroma detection using ultrasound radiofrequency data analysis. *J Am Coll Cardiol*, 2005; 46: 2038–2042.