

T wave oversensing and low percentage of biventricular pacing in cardiac resynchronization therapy

Antonio O. Luque Lezcano, Jose Manuel Porres Aracama,
Vicente Urbistondo Ayestaran, Francisco Garcia Urrea

Hospital Donostia Arrhythmia Unit, Intensive Care Department, Donostia, Spain

Abstract

The success of cardiac resynchronization therapy (CRT) depends on a high percentage of ventricular pacing. We present the electrocardiography and electrograms of a patient who underwent an implantable cardioverter-defibrillator (ICD) with CRT implantation showing a low percentage of ventricular pacing as a result of T wave oversensing of paced QRS. The patient showed no clinical improvement.

We suggest finding a good sensitivity of F waves in induced ventricular fibrillation during ICD implantation in order to overcome the harm of possible oversensing. (Cardiol J 2009; 16, 6: 580–581)

Key words: cardiac resynchronization therapy, T wave oversensing

Cardiac resynchronization therapy (CRT) is a proven and established therapy for patients with chronic heart failure who fulfil the requirements defined in the Guides of Cardiac Pacing and Cardiac Resynchronization and in the Guides of Diagnosis and Treatment of Acute and Chronic Heart Failure.

The essential argument for this therapy consists of the dyssynchrony shown in the cardiac mechanical cycle of these patients. The different segments of the muscular walls forming the left ventricle contract and relax in a dyssynchronous way. This circumstance, together with the dilated cardiomyopathy and depressed left ventricular function, provokes a remodelling of the myocardium that accelerates the process of heart failure.

Cardiac resynchronization therapy tries to slow, or even reverse, the dilation process of the heart by means of pacing from two different points, typically the apex of the right ventricle and the lateral wall of the left ventricle. The aim of these devices is a percentage of ventricular pacing approaching 100%.

We present the case of a 56 year-old man with non-ischemic dilated cardiomyopathy and chronic heart failure. He had undergone placement of an

implantable cardioverter-defibrillator (ICD) with CRT three months previously.

He came to the hospital for an ICD follow-up with seemingly no clinical improvement. Electrocardiography showed a 100 pm rate sinus rhythm with two alternant QRS complexes, each one preceded by his own PR, 100 and 160 ms (Fig. 1). When the device was interrogated, the mark channel and electrograms showed atrial sense (AS), atrial sense in refractory period (AR), sensed ventricles of different morphology (VS) and biventricular paced ventricles (BV). If we looked at the recorded trace carefully we could easily say that all the atrial electrograms had identical morphology. Ventricular electrograms, though, alternated in morphology. Surprisingly in the mark channel there was a BV-VS-VS cycle. The first mark fits the first QRS morphology corresponding to biventricular pacing. The third mark fits the second QRS morphology (sensed ventricle). The second mark shows a T wave oversensing of the paced QRS (Fig. 1) [1]. This oversensing was interpreted by the ICD as ventricular extrasistolia. The following AS falls within the postventricular atrial refractory period and is

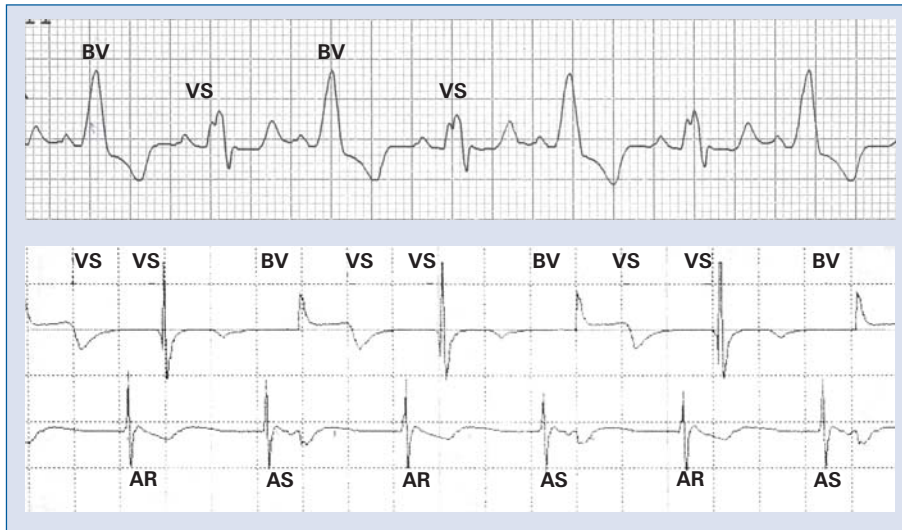


Figure 1. Electrograms showing T wave oversensing (BV-VS-VS). P wave sensed in refractory period (AR) followed by sensed ventricle (2nd VS). On top ECG registration.

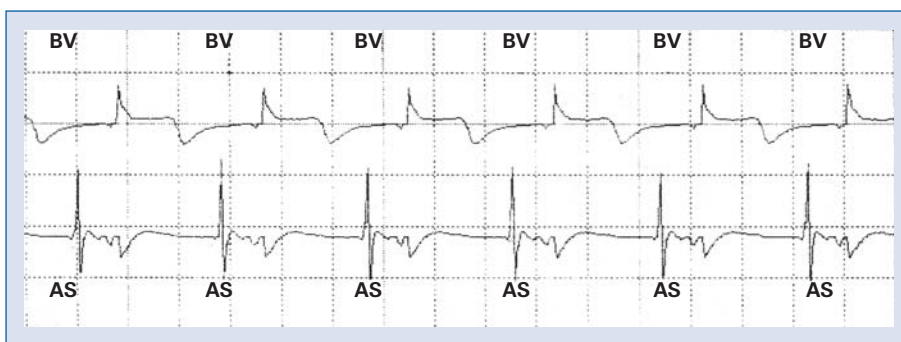

Figure 2. Electrograms showing sensed A waves (AS) followed by normal biventricular pacing.

sensed as a refractory event (AR). The next ventricular paced is withheld, resulting in a sensed ventricle with native PR. This proves that for most of the day the patient alternated ventricular pacing and sensed QRS, in spite of the fact that the programmed sensed AV is 100 ms [2].

By lowering the ventricular sensing from 0.3 to 0.6 mV (sensed R 14 mV; programmed ventricular sense for measurement of the defibrillation threshold 0.8 mV) [3], T wave oversensing was overcome and every sensed P wave was followed by biventricular pacing (Fig. 2) [4, 5].

Conclusion: oversensing of the T wave in carriers of a cardiac resynchronization therapy device can provoke a low percentage of ventricular pacing and therefore a failure in the electrical treatment for chronic heart failure.

We suggest finding good sensitivity values during ICD implantation in order to overcome possible troubleshooting related to oversensing.

Acknowledgements

The authors do not report any conflict of interest regarding this work.

References

1. Manolis AG, Chatzis DG, Kouvelas K, Kyriakides ZS. Partial inhibition of ongoing antitachycardia pacing sequence due to T-wave oversensing. *PACE*, 2008; 31: 780–781.
2. Koul AK, Keller S, Clancy JF, Lampert R, Batsford WP, Rosenfeld LE. Hypercalcemia induced T wave oversensing leading to loss of biventricular pacing and inappropriate ICD shocks. *PACE*, 2004; 27: 681–683.
3. Porres JM, Brugada J, Marco P, Garcia F, Azcarate B. T wave oversensing by a cardioverter defibrillator implanted in a patient with the Brugada syndrome. *PACE*, 2004; 27: 1563–1565.
4. Silver JS, Gray ME, John RM. Strategy to eliminate inappropriate shocks secondary to T-wave oversensing in a biventricular ICD. *PACE*, 2009, 32: 134–136.
5. van Erven L, Schalij MJ. Troubleshooting implantable cardioverter-defibrillator related problems. *Heart*, 2008; 94: 649–660.