

# Malignant atrial fibrillation in the Wolff-Parkinson-White syndrome

S. Serge Barold

Division of Cardiology, University of South Florida College of Medicine and Tampa General Hospital,  
Tampa, Florida, USA

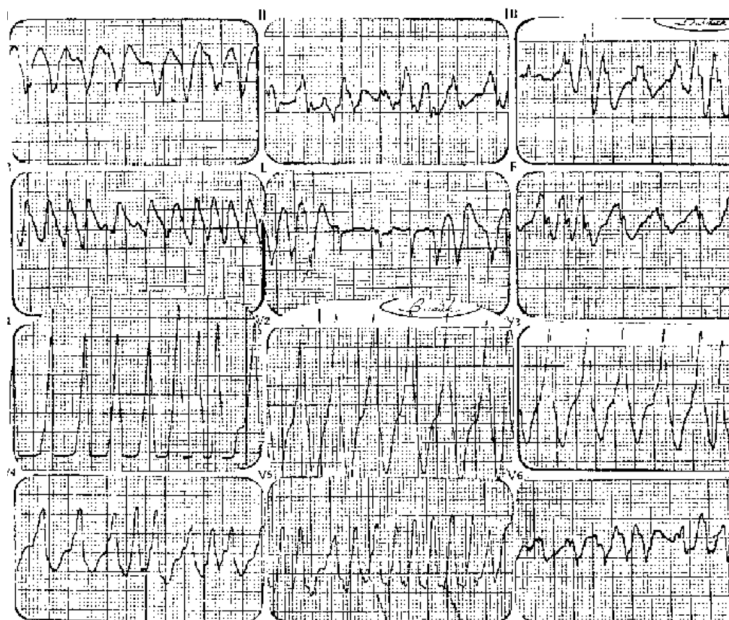


Figure shows an ECG recorded before any therapy in a previously healthy and asymptomatic 45 year-old man who presented with near-syncope and hypotension. The chaotic pattern consisting of a markedly irregular rapid ventricular rate and changing configuration of the QRS complexes is characteristic of atrial fibrillation in the Wolff-Parkinson-White (WPW) syndrome. The gross overall disorganization rules out polymorphic ventricular tachycardia. At times, the ventricular rate exceeds 300/min, and even reaches about 350/min when the pattern cannot be clearly distinguished from ventricular

flutter. Ventricular rates of 350 bpm (R-R intervals  $\leq 190$  ms) have been reported in WPW patients in similar situations. Such patients are at risk of sudden death from ventricular fibrillation. Most of the QRS complexes in the ECG are wide and represent exclusive ventricular depolarization via the accessory pathway. Lead aVL shows one quite narrow QRS complex possibly due to ventricular activation through the normal pathways. Other relatively narrow QRS complexes in lead aVL represent ventricular fusion of normal activation and that coming from the accessory pathway (see the first complex in lead III). During ventricular depolarization from the accessory pathway the QS complexes in leads I and aVL and the dominant R wave in the right precordial leads suggest the presence of a left lateral accessory pathway. The changing morphology of the QRS complexes in lead V6 may indicate conduction via another accessory pathway. This point is important

Address for correspondence: S. Serge Barold, MD  
 5806 Mariner's Watch Drive, Tampa, FL 33615, USA  
 Fax: 813 891 1908  
 e-mail [ssbarold@aol.com](mailto:ssbarold@aol.com)

because WPW patients who develop ventricular fibrillation have a higher incidence of multiple accessory pathways. Treatment was immediate cardioversion with restoration of sinus rhythm whereupon the ECG showed the characteristic pattern of WPW syndrome. An electrophysiologic study revealed a single left lateral pathway with a very short effective refractory period of 190 ms.

The patient underwent successful ablation of the single accessory pathway and he has remained well for over 15 years. This observation demonstrates the risk of sudden death related to an accessory pathway with a very short effective refractory period. Sudden death from ventricular fibrillation is occasionally the first manifestation of the WPW syndrome.