

# QT interval prolongation and torsades de pointes in a patient undergoing treatment with vorinostat: A case report and review of the literature

Donald R. Lynch Jr.<sup>1</sup>, Jeffrey B. Washam<sup>2</sup>, L. Kristin Newby<sup>3</sup>

<sup>1</sup>Johns Hopkins Department of Medicine, Baltimore, MD, USA

<sup>2</sup>Cardiac Care Unit, Duke Heart Center, Duke University Medical Center, Durham, NC, USA

<sup>3</sup>Division of Cardiovascular Medicine, Duke Clinical Research Institute, Duke University Medical Center, Durham, NC, USA

## Abstract

*Vorinostat is a histone deacetylase inhibitor used in the treatment of recurrent or persistent cases of cutaneous T-cell lymphoma (CTCL). A retrospective review of 116 patients from phase I and II clinical trials who had a baseline and at least one subsequent ECG revealed that four patients had Grade 2 and one patient had Grade 3 QTc interval prolongation; however, a MEDLINE search found no reported cases of torsades de pointes (TdP) in patients treated with vorinostat. We describe the case of a 49 year-old male with a history of CTCL actively undergoing treatment with vorinostat. During day 1 of hospitalization, he developed a pulseless polymorphic ventricular tachycardia requiring resuscitation. He was found to have a QTc of 826 ms. Following correction of potassium and magnesium, QTc gradually decreased and no further ventricular arrhythmia was noted. Other factors implicated in this case included concurrent sertraline and doxepin therapy (both drugs have been associated with the development of TdP in overdose). The mechanism of development of TdP in this patient is postulated to be related to vorinostat use in combination with hypokalemia and concomitant treatment with medications associated with QTc prolongation. This case highlights the importance of post-market surveillance. (Cardiol J 2012; 19, 4: 434–438)*

**Key words:** QTc prolongation, torsades de pointes, vorinostat (Zolinza)

## Case report

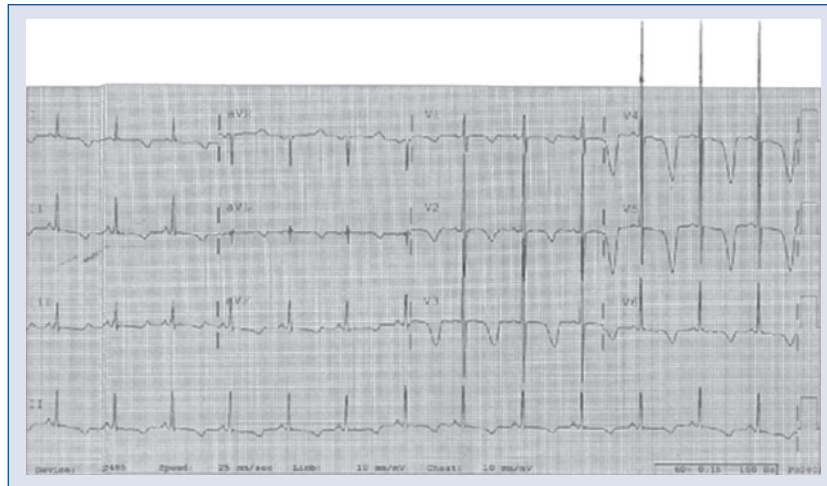We report the case of a 49 year-old African American man with a history of cutaneous T-cell lymphoma (CTCL), liver disease, renal insufficiency, hemolytic anemia, and right hepatic lobe hemangioma who was admitted to hospital with a four-day history of hematemesis, hematochezia, and a syncope episode. Prior to admission, he was being treated with vorinostat (Zolinza<sup>®</sup>) for CTCL and took his last dose on the day prior to admission.

Electrocardiogram (ECG) on admission (Fig. 1) demonstrated sinus rhythm at a rate of 79 with a QTc interval of 826 ms and T-wave inversions throughout the precordial and limb leads. QRS duration was 60 ms. A comparison ECG from 48 months prior to admission (Fig. 2) demonstrated normal sinus rhythm at a rate of 62 with a QTc interval of 400 ms. Admission laboratory tests were notable for BUN 36 mg/dL, serum creatinine 1.7 mg/dL, glucose 174 mg/dL, D-dimer 3.49 µg/L, hemoglobin 7.2 mg/dL, and platelet count 2000/mm<sup>3</sup>.

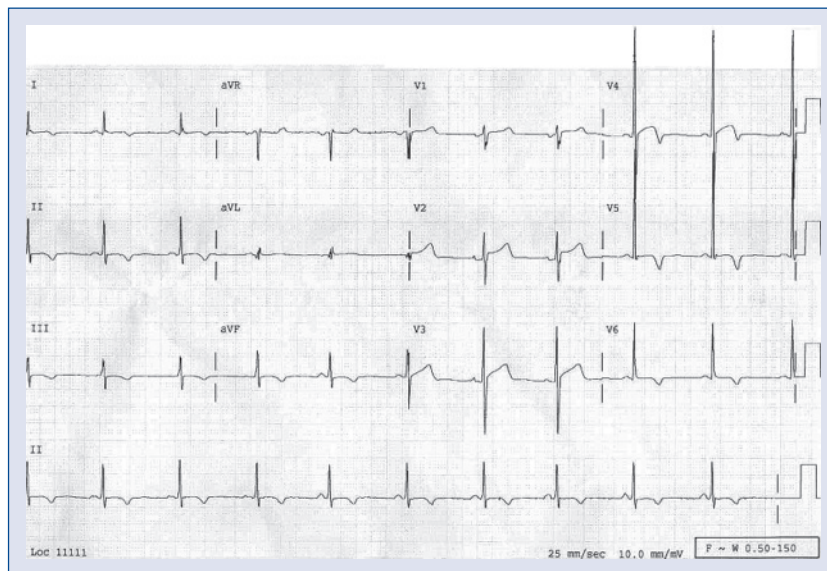
**Address for correspondence:** Jeffrey B. Washam, Pharm D, Duke Heart Center, Box 3943 Duke University Medical Center, Durham, NC 27710, USA, tel: 919 681 3286, fax: 919 681 2960, e-mail: [washa002@mc.duke.edu](mailto:washa002@mc.duke.edu)

Received: 31.03.2011

Accepted: 30.05.2011



**Figure 1.** Admission electrocardiogram demonstrating QTc interval of 826 ms.

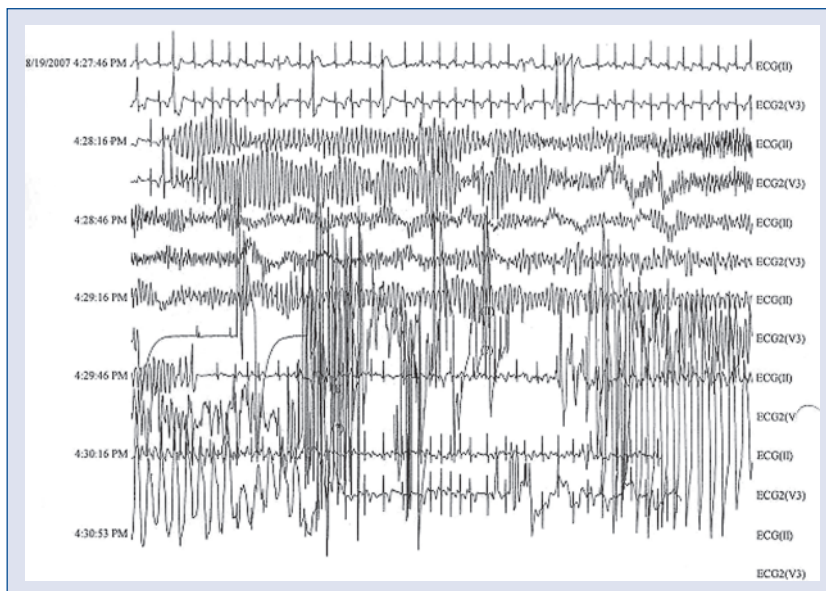


**Figure 2.** Electrocardiogram two years prior to current admission, demonstrating QTc interval of 400 ms.

An echocardiogram in March 2007 had demonstrated normal ejection fraction (> 55%); trivial aortic regurgitation, tricuspid and mitral regurgitation; and trivial pericardial effusion. Medications prior to admission included: hydrochlorothiazide 25 mg daily, NPH and regular insulin, doxepin 25 mg at bedtime, sertraline 100 mg daily, naproxen sodium as needed for pain, oxycodone as needed for pain and vorinostat (Zolinza®) 400 mg daily.

On day one of hospitalization, the patient developed a pulseless polymorphic ventricular tachycardia (shown in Fig. 3). A code was called during which the patient spontaneously reverted to sinus

rhythm after brief cardiopulmonary resuscitation (< 1 min) and without the need for defibrillation or external pacing. Magnesium (2 g intravenously) was given immediately. Potassium, which was 3.1 mmol/L on morning laboratory assessment approximately 9.5 h prior to the episode of TdP, was also supplemented. The patient was transferred to the cardiac care unit (CCU) for overnight observation and closer monitoring, and there was no recurrence of torsade de pointes (TdP) during the remainder of the hospitalization. Upon transfer to the CCU, doxepin and sertraline were discontinued. The patient's QTc interval initially decreased to 514 ms follow-



**Figure 3.** Electrocardiogram demonstrating polymorphic ventricular tachycardia noted on telemetry when patient was found to be pulseless.

ing normalization of serum potassium to 4.9 mmol/L. However, by day 4, the QTc interval remained stable but prolonged at 559 ms. Serial cardiac markers (troponin T and creatine kinase-MB) were negative. An echocardiogram, obtained shortly after arrival at the CCU, demonstrated enlargement of the previously documented pericardial effusion with respiratory flow variation, but there were no clinical signs of tamponade. Left ventricular function was unchanged from the previous echocardiogram.

## Discussion

### QT interval prolongation and occurrence of torsade de pointes

It is known that acquired QT interval prolongation, as in the case of drug-induced long QT syndrome, is associated with increased risk of TdP. This is an important issue in patient care as this rhythm is unstable and may degenerate to ventricular fibrillation and subsequent sudden cardiac death. The importance of this is exemplified by the observation that QT interval prolongation and TdP are among the commonest reasons for the restriction of use or removal of prescription medications from the United States market [1]. A number of medications are known to prolong the QT interval, including: antiarrhythmics, gastrointestinal promotility agents, antimicrobials, antipsychotics, antidepressants, and other miscellaneous medications such as methadone. In some cases, QTc interval

prolongation may be dose-dependent, while in others, potassium channel blockage and subsequent development of TdP may occur at any dosage [2]. However, it should be noted that most patients on QT interval-prolonging medications never develop TdP, and most patients with prolonged QT interval do not progress to TdP.

### Vorinostat and QT interval prolongation

Vorinostat is a targeted antineoplastic agent approved by the United States Food and Drug Administration (FDA) in October 2006 for the treatment of cutaneous manifestations of CTCL in patients with progressive, persistent, or recurrent disease on therapy or after trials of two systemic therapies [3]. Vorinostat (suberoylanilide hydroxamic acid — SAHA) is a member of a class of histone deacetylase inhibitors (HDAC), which specifically inhibit the activity of the enzymes HDAC1, HDAC2, HDAC3, and HDAC6. During phase I study of intravenous SAHA, one patient experienced an acute myocardial event and died; this was later attributed to myocardial infarction unrelated to study medication. This occurred during the one week observation period following completion of three weeks of SAHA (900 mg/m<sup>2</sup>) [4]. Reportedly, ECGs demonstrated no changes from baseline and no electrolyte abnormalities were noted. Nonetheless, an additional four patients were enrolled within the same cohort to examine the cardiac effects of the drug. ECGs performed before, during, and

after treatment revealed only non-specific ST-segment changes. No cardiac dysrhythmias were reported in this study. Subsequently, the oral preparation of SAHA was tested in a second phase I study. A total of 73 patients were treated, each of whom underwent baseline testing including ECG and further cardiac workup as needed. Additionally, follow-up testing, including ECGs, were performed weekly before each cycle of treatment (for a total of up to eight weeks). Of the patients in this phase I trial, 34% developed mild to moderate dyspnea without other cardiac symptoms or ECG findings. Serial ECGs demonstrated non-specific ST-segment and QT interval changes, which were not further defined [5].

Patients in a phase II trial of oral vorinostat for treatment of refractory CTCL underwent ECGs at baseline and every three weeks while on study drug for up to 67 weeks. Two participants died during the study as a result of progression of disease and sepsis, but there were no reported cases of sudden cardiac death, clinically significant ECG changes, or adverse cardiac events [6]. A phase IIb study of oral vorinostat for treatment of progressive, recurrent, or persistent stage IIB or higher mycosis fungoides/Sezary syndrome (MF/SS) found that the commonest drug-related adverse experiences were gastrointestinal (diarrhea, nausea, dysgeusia, weight loss, vomiting, constipation), constitutional (fatigue, anorexia), and hematological. The most serious adverse event occurring in more than one of the 74 patients was a thrombotic event. ECGs were performed at baseline and after four weeks of therapy. Electrocardiographic changes between baseline and four weeks were noted in 15 patients, ten of whom had documented cardiovascular disease at baseline or documented baseline ECG abnormalities. Three patients had QTc interval prolongation; one with Grade 2 ( $> 470$ – $500$  ms or  $> 60$  ms increase above baseline) and two with Grade 1 ( $> 450$ – $470$  ms) QTc interval prolongation. No cardiac symptoms were noted; therefore, no vorinostat dosage modifications or discontinuation were required [7]. In a retrospective analysis of the phase I and phase II studies, 116 patients had a baseline and at least one follow-up ECG. Four patients had Grade 2 ( $> 470$ – $500$  ms or increase of  $> 60$  ms above baseline) and one patient had Grade 3 ( $> 500$  ms) QTc interval prolongation. In 49 non-CTCL patients from three other clinical trials in which complete evaluation of the QT interval was performed, two had QTc intervals of  $> 500$  ms and one had QTc interval prolongation of  $> 60$  ms.

### Other factors associated with QT interval prolongation

In addition to vorinostat, the patient we present was also receiving other drugs with the potential to prolong the QT interval. Our patient was using doxepin at low dose (25 mg at bedtime) for sleep. One study of ECG effects of doxepin (mean daily dosage at six weeks  $169 \pm 42$  mg) and fluoxetine in patients with major depression found that doxepin increased heart rate ( $69 \pm 12$  to  $81 \pm 13$  bpm;  $p = 0.0003$ ) and prolonged the QTc interval (from  $417 \pm 36$  to  $439 \pm 28$  ms;  $p < 0.03$ ) based on measurements from signal-averaged ECGs. However, no significant change in QRS or QTc durations were noted with either drug on blinded review of 12-lead ECG measurements [8]. In overdose, doxepin has been associated with significant QT interval prolongation and TdP, which responded well to treatment with physostigmine [9, 10]. Our patient was also receiving sertraline 100 mg daily, which has been shown to prolong the QT interval [11], and has been associated with the development of TdP in overdose [12]. It is unlikely that either doxepin or sertraline at the doses used by our patient can account for the marked QTc interval prolongation we observed.

Hypokalemia is a well known risk factor for drug-induced long QT syndrome [13]. Paradoxical reduction of the delayed rectifier K<sup>+</sup> current may occur with low extracellular potassium concentrations via enhanced inactivation or enhanced competitive block by sodium. Normalization of the QT interval occurs following correction of potassium levels to high-normal values. Our patient's QTc interval had decreased to 559 ms by day 4 of hospitalization following discontinuation of vorinostat, doxepin and sertraline and normalization of serum potassium.

### Summary

Drug-induced QTc interval prolongation is associated with increased risk of the development of TdP. In this case, an association was seen between the administration of oral vorinostat and subsequent QTc interval prolongation, which although greatly improved over the course of hospitalization, persisted despite correction of hypokalemia and discontinuation of other agents with the potential to prolong the QTc interval. In addition, transient potential life-threatening TdP was noted in our patient. At the time this report was written, the patient had not undergone a second trial of vorinostat therapy. Therefore, the interaction is classified as possible



based on the Naranjo ADR probability scale [14]. Thus, it seems reasonable to consider close monitoring for ECG changes, avoidance of other agents with the potential to prolong the QT interval, and careful electrolyte management among patients receiving vorinostat therapy. It is expected that as more insight is gained through continued use of vorinostat, the association observed in this case may be more accurately defined.

In conclusion, we report the first known case of TdP in a patient treated with vorinostat with concomitant sertraline and doxepin therapy and mild hypokalemia. These findings highlight the need for periodic monitoring of electrolytes and ECGs in patients receiving vorinostat, as recommended in the prescribing information. An attempt should also be made to avoid concurrent use of medications known to prolong the QT interval in patients receiving vorinostat.

**Conflict of interest:** none declared

## References

1. Lasser KE, Allen PD, Woolhandler SJ, Himmelstein DU, Wolfe SM, Bor DH. Timing of new black box warnings and withdrawals for prescription medications. *JAMA*, 2002; 287: 2215–2220.
2. Gupta A, Lawrence AT, Krishnan K, Kavinsky CJ, Trohman RG. Current concepts in the mechanisms and management of drug-induced QT prolongation and torsades de pointes. *Am Heart J*, 2007; 153: 891–899.
3. Mehnert JM, Kelly WK. Histone deacetylase inhibitors: Biology and mechanism of action. *Cancer J*, 2007; 13: 23–29.
4. Kelly WK, Richon VM, O'Connor O et al. Phase I clinical trial of histone deacetylase inhibitor: Suberoylanilide hydroxamic acid administered intravenously. *Clin Cancer Res*, 2003; 9: 3578–3588.
5. Kelly WK, O'Connor OA, Krug LM et al. Phase I study of an oral histone deacetylase inhibitor, suberoylanilide hydroxamic acid, in patients with advanced cancer. *J Clin Oncol*, 2005; 23: 3923–3931.
6. Duvic M, Talpur R, Ni X et al. Phase 2 trial of oral vorinostat (suberoylanilide hydroxamic acid, SAHA) for refractory cutaneous T-cell lymphoma (CTCL). *Blood*, 2007; 109: 31–39.
7. Olsen EA, Kim YH, Kuzel TM et al. Phase IIb multicenter trial of vorinostat in patients with persistent, progressive, or treatment refractory cutaneous T-cell lymphoma. *J Clin Oncol*, 2007; 25: 3109–3115.
8. Baker B, Dorian P, Sandor P et al. Electrocardiographic effects of fluoxetine and doxepin in patients with major depressive disorder. *J Clin Psychopharmacol*, 1997; 17: 15–21.
9. Alter P, Tontsch D, Grimm W. Doxepin-induced torsades de pointes tachycardia. *Ann Intern Med*, 2001; 135: 384–385.
10. Strasberg B, Coelho A, Welch W, Swiryn S, Bauernfeind R, Rosen K. Doxepin induced torsades de pointes. *Pacing Clin Electrophysiol*, 1982; 5: 873–877.
11. Isbister GK, Bowe SJ, Dawson A, Whyte IM. Relative toxicity of selective serotonin reuptake inhibitors (SSRIs) in overdose. *J Toxicol Clin Toxicol*, 2004; 42: 277–285.
12. de Boer RA, van Dijk TH, Holman ND, van Melle JP. QT interval prolongation after sertraline overdose: A case report. *BMC Emerg Med*, 2005; 5: 5.
13. Kannankeril PJ, Roden DM. Drug-induced long QT and torsades de pointes: Recent advances. *Curr Opin Cardiol*, 2007; 22: 39–43.
14. Naranjo CA, Busto U, Sellers EM et al. A method for estimating the probability of adverse drug reactions. *Clin Pharmacol Ther*, 1981; 30: 239–245.