

Congenital absence of the pericardium: A rare cause of right ventricular dilatation and levoposition of the heart

Erkan İlhan¹, Şennur Ünal Dayı¹, Tolga Sinan Güvenç¹, Servet Altay¹,
Memduh Dursun², Erdiñç Hatipsoylu¹, Gülşah Tayyareci¹

¹Department of Cardiology, Dr. Siyami Ersek Cardiovascular and Thoracic
Surgery Training and Research Hospital, Istanbul, Turkey

²Department of Radiology, Istanbul Faculty of Medicine, Istanbul University, Turkey

Abstract

Congenital absence of the pericardium is a rare cardiac defect with variable clinical presentations and is usually discovered incidentally. The pathology may lead to serious complications such as incarceration of cardiac tissue, myocardial ischemia, aortic dissection or valvular insufficiency. Diagnosis is not difficult so long as some tips are remembered. We present the cases of two patients with congenital absence of left pericardium. (Cardiol J 2012; 19, 4: 408–411)

Key words: congenital absence of the pericardium, levoposition

Introduction

Congenital absence of the pericardium (CAP) is a rare cardiac defect with a wide spectrum of clinical presentation. Sudden death, incarceration of cardiac tissue, myocardial ischemia and aortic dissection are the most serious complications. Awareness of some clues to the pathology related to chest X-ray and transthoracic echocardiography (TTE) will increase the number of patients diagnosed with this condition. We present two patients with complete absence of left side of the pericardium, of whom levoposition of the heart and right ventricular dilatation were the first presenting findings.

Case reports

Case 1

A 26 year-old man with no past medical history was admitted to the cardiology department complaining of a non-exertional stabbing chest pain.

ECG showed incomplete right bundle branch block and poor precordial R wave progression and minimal ST segment elevation in leads V1–V3 (Fig. 1). Physical examination was normal. Chest X-ray showed leftward position of the heart, flattening and elongation of the left heart border and a lucent area between the aorta and pulmonary artery (Fig. 2). On TTE, the right ventricle seemed enlarged and the pathognomonic appearance of a ‘teardrop heart’ could be seen (Fig. 3). There was also paradoxical septal motion of the interventricular septum. Therefore the patient was diagnosed with CAP. Thorax computed tomography (CT) and cardiac magnetic resonance imaging (MRI) confirmed the diagnosis and documented the extent of pathology (Figs. 4, 5). Stress echocardiography excluded possible pendulum-like motion of the heart.

Case 2

A 58 year-old woman with no past medical history was admitted to the cardiology department

Address for correspondence: Dr. Erkan İlhan, Dr. Siyami Ersek Cardiovascular and Thoracic Surgery Training and Research Hospital, Department of Cardiology, Istanbul, Turkey, tel: +90 5054365384, fax: +90 2164183317, e-mail: erkan.ilhan@yahoo.com.tr

Received: 15.12.2010

Accepted: 10.01.2011

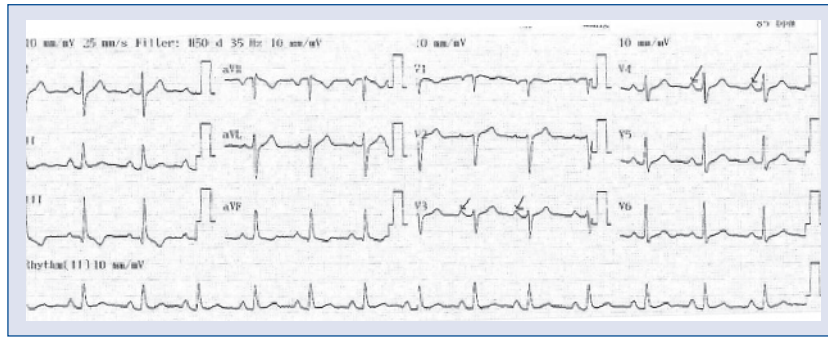

Figure 1. 12-lead ECG showing relatively prominent P-waves in the mid-precordial leads (arrows).

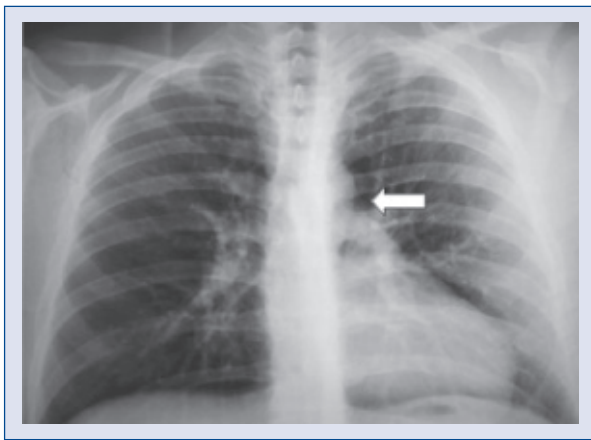


Figure 2. Chest radiograph showing leftward position of the heart, flattening and elongation of left heart border (so-called 'Snoopy sign'), and a lucent area between the aorta and pulmonary artery due to lung interposition (white arrow).

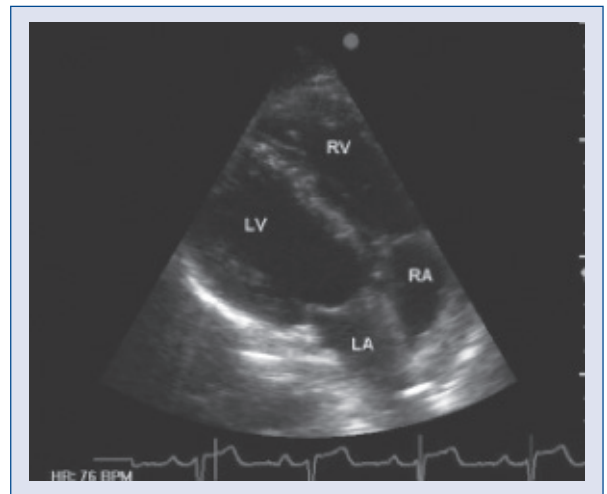


Figure 3. Transthoracic echocardiogram apical four-chamber view showing lateral displacement of the apex and enlarged right ventricle; LA — left atrium; LV — left ventricle; RA — right atrium; RV — right ventricle.

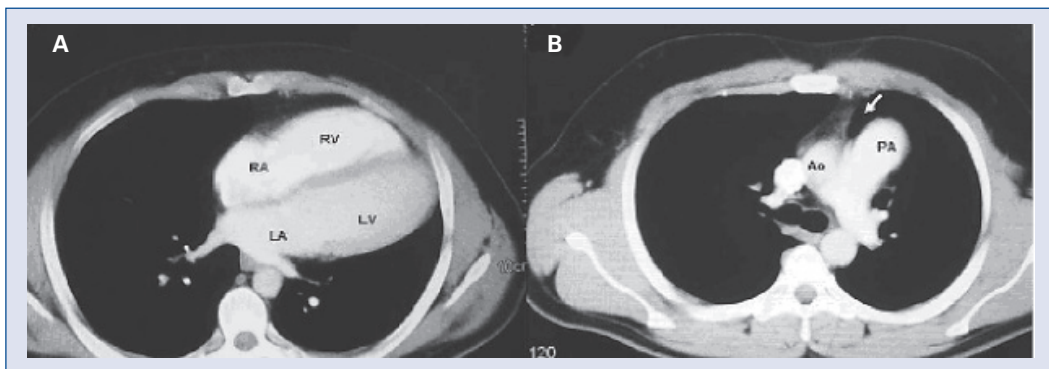


Figure 4. **A.** Transverse thorax computed tomography (CT) image showing dilatation of the right ventricle and levoposition; **B.** Transverse thorax CT image at the level of the aorto-pulmonary window showing interposition of lung tissue between the aorta and main pulmonary artery (arrow) which is pathognomonic for absence of pericardium in this region; LA — left atrium; LV — left ventricle; RA — right atrium; RV — right ventricle; Ao — aorta; PA — pulmonary artery.

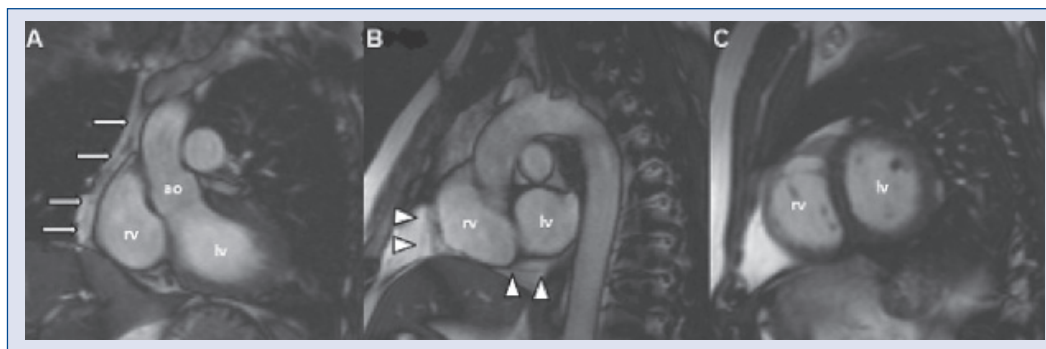


Figure 5. A. Left ventricular outflow tract view of cardiac magnetic resonance imaging (MRI) showing pericardium at periphery of right ventricle (arrows); B. Short axis MRI frames of heart base showing thin pericardium (arrowheads). C. There is no pericardium on midventricular frames; ao — aorta; lv — left ventricle; rv — right ventricle.

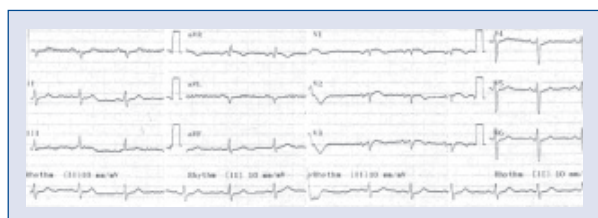

Figure 6. 12-lead ECG of the patient.

complaining of stinging chest pain. ECG showed poor precordial R wave progression, right axis deviation and minimal ST segment elevation in leads V1–V3 (Fig. 6). Physical examination was normal. Chest radiography revealed leftward position of the heart, flattening and elongation of left heart border (the ‘Snoopy sign’), and a lucent area between the aorta and pulmonary artery due to lung interposition (Fig. 7). Echocardiography revealed an extremely laterally displaced heart with poor echo window. Cardiac CT showed extreme levoposition of the heart, absence of the left pericardium and interposition of lung tissue between the aorta and main pulmonary artery (Fig. 8).

Discussion

Congenital absence of the pericardium is an uncommon cardiac defect with variable clinical presentations and is usually discovered incidentally, during operations or post mortem [1]. CAP may be isolated or accompany other defects or syndromes [2–4]. It can vary from partial to complete absence and is found more often on the left than on the right side [5, 6]. Although complete absence of the entire pericardium or absence of the whole left or right side usually has an excellent prognosis [7, 8], all types of CAP can lead to serious com-

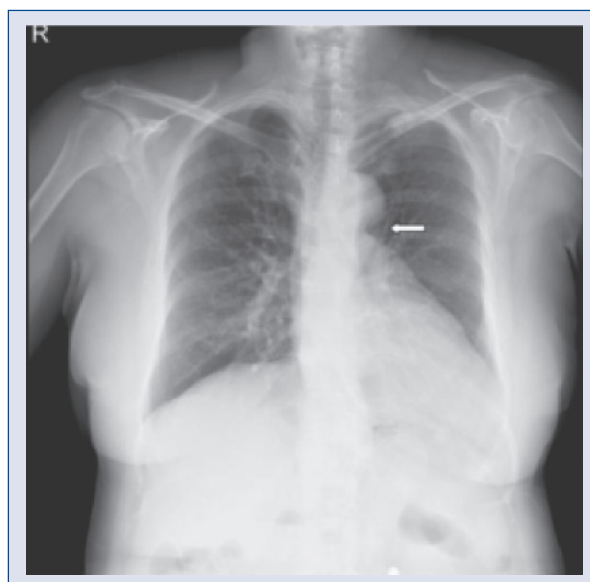


Figure 7. Chest radiograph showing leftward position of the heart, flattening and elongation of left heart border (so-called ‘Snoopy sign’), and a lucent area between the aorta and pulmonary artery due to lung interposition (white arrow).

plications such as incarceration of cardiac tissue, myocardial ischemia, aortic dissection or valvular insufficiency. Therefore detection of this malformation is clinically important [6, 8–11]. The functional capacity of our patients was normal and we did not detect any compression of the great arteries, coronary arteries or incarceration of cardiac structures. So, we adopted a conservative approach.

The ECG may reveal bradycardia, right bundle branch block, poor R-wave progression secondary to leftward displacement of the precordial transitional zone, and prominent P-waves in the mid-

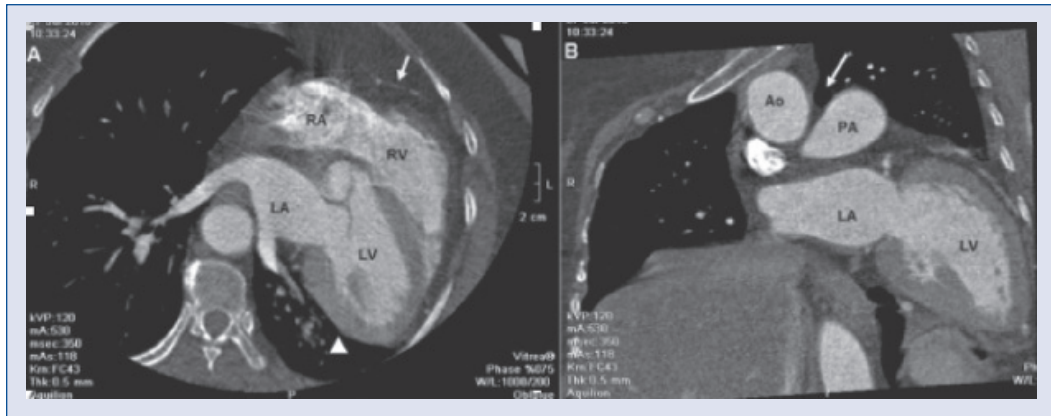


Figure 8. **A.** Cardiac computed tomography showing extreme levoposition of the heart, thin pericardium covering the right side of the heart (arrow) but absence of the left pericardium (arrowhead); **B.** Interposition of lung tissue between the aorta and main pulmonary artery (arrow) at the level of the aorto-pulmonary window; RA — right atrium; RV — right ventricle; LA — left atrium; LV — left ventricle; PA — pulmonary artery; Ao — aorta.

precordial leads that indicate right atrial overload [7]. However, TTE is the main tool when this diagnosis is suspected [12]. The characteristic echocardiographic features of this entity are unusual echocardiographic windows, cardiac hypermobility, abnormal ventricular septal motion and an abnormal swinging motion of the heart [7]. Detection of one of these should suggest a diagnosis of CAP. In our cases, the diagnosis was suggested by levoposition of the heart with laterally displaced parasternal windows, and a ‘teardrop heart’ secondary to the absence of normal tethering and shaping forces applied by the normal pericardium.

Normally, the aortopulmonary window is covered by the pericardium, and absence of the pericardium at this region allows interposition of lung tissue between the aorta and the main segment of the pulmonary artery. Although chest X-ray may show some evidence, CT or MRI defines the aortopulmonary window clearly [13, 14]. MRI provides excellent images of the entire pericardium and MRI is a useful diagnostic tool for establishing the extent of pericardial defect [15].

Complete cases require no intervention unless complications occur. Patients with debilitating symptoms may benefit from pericardioplasty [1]. However, in partial defects, when herniation occurs or is threatened, extension of the defect by pericardiectomy/pericardioplasty may be performed. Excision of the left atrial appendage may be necessary if it herniates.

In conclusion, congenital absence of the pericardium should be suspected when the characteristic echocardiographic features are present.

Conflict of interest: none declared

References

- Gatzoulis MA, Munk MD, Merchant N, Van Arsdell GS, McCrindle BW, Webb GD. Isolated congenital absence of the pericardium: Clinical presentation, diagnosis, and management. *Ann Thorac Surg*, 2000; 69: 1209–1215.
- Abbas AE, Appleton CP, Liu PT, Sweeney JP. Congenital absence of the pericardium: Case presentation and review of literature. *Int J Cardiol*, 2005; 98: 21–25.
- Dias RR, Albuquerque JM, Pereira AC et al. Holt-Oram syndrome presenting as agenesis of the left pericardium. *Int J Cardiol*, 2007; 114: 98–100.
- Chiariello M, Indolfi C, Condorelli M. Congenital absence of the pericardium associated with atrial septal defect and sick sinus syndrome. *Int J Cardiol*, 1984; 5: 527–530.
- Lau KW, Ding ZP. Partial pericardial defect. *Circulation*, 1998; 97: 1992.
- Finet G, Bozio A, Friehe JP, Cordier JF, Celard P. Herniation of the left atrial appendage through a congenital partial pericardial defect. *Eur Heart J*, 1991; 12: 1148–1149.
- Connolly HM, Click RL, Schattner TT, Seward JB, Tajik AJ. Congenital absence of the pericardium: Echocardiography as a diagnostic tool. *J Am Soc Echocardiogr*, 1995; 8: 87–92.
- Van Son JA, Danielson GK, Schaff HV, Mullany CJ, Julsrud PR, Breen JF. Congenital partial and complete absence of the pericardium. *Mayo Clin Proc*, 1993; 68: 743–747.
- Nisanoglu V, Erdil N, Battaloglu B. Complete left-sided absence of the pericardium in association with ruptured type A aortic dissection complicated by severe left hemothorax. *Tex Heart Inst J*, 2005; 32: 241–243.
- Nguyen DQ, Wilson RF, Bolman RM 3rd, Park SJ. Congenital pericardial defect and concomitant coronary artery disease. *Ann Thorac Surg*, 2001; 72: 1371–1373.
- Misthos P, Neofotistos K, Drosos P, Kokotsakis J, Lioulis A. Paroxysmal atrial fibrillation due to left atrial appendage herniation and review of the literature. *Int J Cardiol*, 2009; 133: e122–e124.
- Nakashima D, Nakaboh A, Shinozuka T et al. A congenital absence of the pericardium diagnosed by echocardiography. *Int J Cardiol*, 2007; 118: e89–e91.
- Wang ZJ, Reddy GP, Gotway MB, Yeh BM, Hettis SW, Higgins CB. CT and MR imaging of pericardial disease. *Radiographics*, 2003; 23: 167–180.
- Jacob JL, Souza Júnior AS, Parro Júnior A. Absence of the left pericardium diagnosed by computed tomography. *Int J Cardiol*, 1995; 47: 293–296.
- Yamano T, Sawada T, Sakamoto K, Nakamura T, Azuma A, Nakagawa M. Magnetic resonance imaging differentiated partial from complete absence of the left pericardium in a case of leftward displacement of the heart. *Circ J*, 2004; 68: 385–388.