

Sudden unexpected death in an adolescent with epilepsy: All roads lead to the heart?

Kylvia G.F.D. Pinto¹, Fulvio A. Scorza², Ricardo M. Arida³, Esper A. Cavalheiro²,
Luciana D. Martins¹, Helio R. Machado¹, Américo C. Sakamoto¹, Vera C. Terra¹

¹Centro de Cirurgia de Epilepsia (CIREP), Departamento de Neurociências e Ciências do Comportamento, Faculdade de Medicina de Ribeirão Preto, Universidade de São Paulo, Ribeirão Preto, São Paulo, Brazil

²Disciplina de Neurologia Experimental, Universidade Federal de São Paulo/
/Escola Paulista de Medicina (UNIFESP/EPM), São Paulo, Brazil

³Departamento de Fisiologia, Universidade Federal de São Paulo/
/Escola Paulista de Medicina (UNIFESP/EPM), São Paulo, Brazil

Abstract

The incidence of sudden unexpected death in epilepsy (SUDEP) has been estimated from 0.5–1.4/1,000 person-years in people with treated epilepsy, and 9/1,000 person-years in candidates for epilepsy surgery. Potential risk factors for SUDEP include: age, early onset of epilepsy, duration of epilepsy, uncontrolled seizures, seizure type and winter temperatures. The arrhythmogenic side-effect of antiepileptic drugs and seizures may increase the risk of SUDEP. In this report, we describe a patient with prolonged post-ictal tachycardia in EEG video recordings with a typical case of SUDEP: a 16-year-old boy with medically intractable complex partial seizures. Magnetic resonance imaging revealed left mesial temporal sclerosis. During non-invasive video-EEG monitoring, the patient presented a post-ictal heart rate increased for five hours. Two months after video-EEG, he died from SUDEP during a tonic-clonic secondary generalized seizure. The possibility of cardiac involvement in the pathogenesis of SUDEP has been suggested by many studies. Evaluation of this patient with EEG-video monitoring, including measurement of heart rate, contributed to an identification of ictal tachycardia that may have played a role in the SUDEP. Premature mortality seems to be increased in patients with epilepsy, and cardiac abnormalities may be a possible cause of SUDEP. (Cardiol J 2011; 18, 2: 194–196)

Key words: sudden death, epilepsy, EEG, heart

Introduction

Sudden unexpected death in epilepsy (SUDEP) is defined as sudden, unexpected, witnessed or unwitnessed, non-traumatic and non-drowning deaths in patients with epilepsy, with or without evidence of a seizure and excluding documented

status epilepticus, in which a post-mortem examination does not reveal a toxicological or anatomical cause of death [1]. The incidence of SUDEP has been estimated from 0.5–1.4/1,000 person-years in people with treated epilepsy, and 9/1,000 person-years in candidates for epilepsy surgery [2]. Potential risk factors for SUDEP include: age, early on-

Address for correspondence: Dr. Vera Cristina Terra, Centro de Cirurgia de Epilepsia, Departamento de Neurociências e Ciências do Comportamento, Faculdade de Medicina de Ribeirão Preto, Universidade de São Paulo, Ribeirão Preto, São Paulo, Brasil, CEP 14048-900, tel: 55 (16) 3602-2613, fax: 55 (16) 3633-0760, e-mail: v.c.terra@rnp.fmrp.usp.br

Received: 24.10.2009

Accepted: 04.01.2010

set of epilepsy, duration of epilepsy, uncontrolled seizures, seizure type and winter temperatures [3, 4]. The potential arrhythmogenic side-effect of antiepileptic drugs and seizures has also been suspected to increase the risk of SUDEP [5]. In this report, we describe a patient with prolonged post-ictal tachycardia in EEG video recordings who proved to be a typical SUDEP case.

Case history

A 16 year-old boy with normal neurodevelopment had had suffering medically intractable epileptic seizures since the age of five. His seizures consisted of abdominal auras followed by gestural automatisms, with occasional secondary generalization. Magnetic resonance imaging revealed left mesial temporal sclerosis. The patient was taking carbamazepine (1,200 mg/day), phenobarbital (200 mg/day) and clobazam (40 mg/day), but was still suffering from two to three seizures per week.

During non-invasive video-EEG monitoring, the patient presented three complex partial seizures, with seizure onset characterized by left temporal theta rhythm. One of the seizures was followed by a secondarily tonic-clonic generalization. No abnormalities in electrocardiogram (ECG) were found. Heart rate (HR) analysis showed a baseline bradycardia of 42 bpm. One minute after seizure termination, HR increased to 119 bpm and a tachycardia of 92 bpm persisted for five hours. Eight hours after the seizure ended, the patient was asymptomatic and had an HR of 77 bpm (Fig. 1). The patient was referred to a cardiologist for clinical investigation. However, two months after the video-EEG, he died during a tonic-clonic secondary generalized seizure. The patient was in a good state of health and a post-mortem examination did not reveal any cardiac abnormality. The cause of death was considered as SUDEP.

Discussion

The possibility of cardiac involvement in the pathogenesis of SUDEP has been suggested by many studies. For instance, antiepileptic drugs may induce lengthening of the ECG Q-T interval, combined with a mild pro-arrhythmic effect of epileptic seizure discharges, and consequent transient cardiac instability leading to arrhythmic death [1]. Similarly, some studies have demonstrated that patients with frontal lobe epilepsy presented interictally faster heart rates attributed to lower parasympathetic drive, which might contribute to the higher incidence

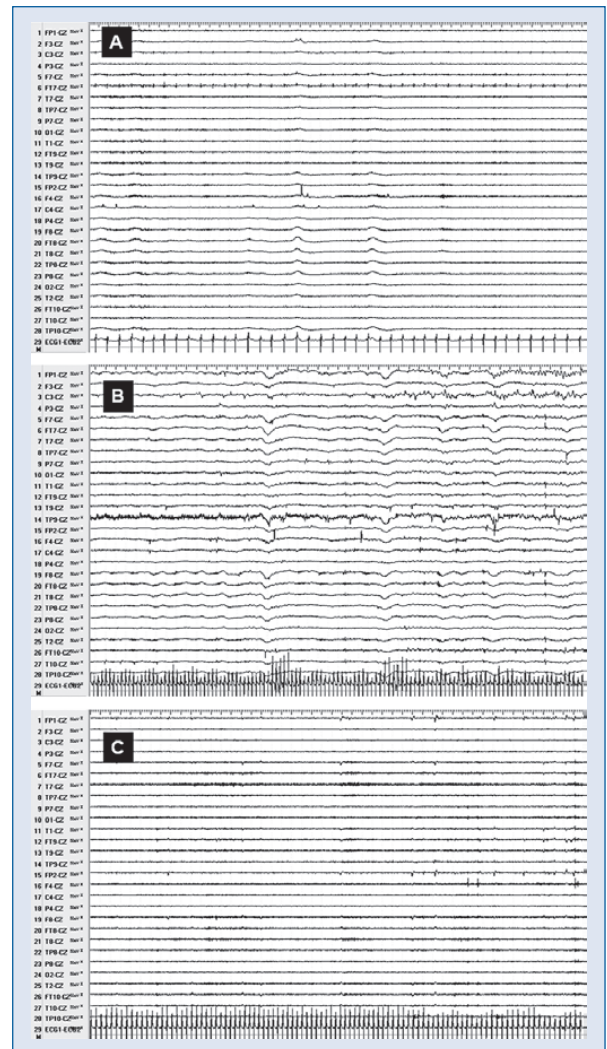


Figure 1. A. Normal wake-up EEG showing baseline heart rate one minute before seizure onset; B. Post-ictal EEG one minute after seizure end, with a significant increase of heart rate; C. Late post-ictal EEG (five hours after seizure end) showing a maintained increase in heart rate when compared to baseline.

of sudden death [6]. Furthermore, events of ictal bradycardia or asystole may be very relevant in epilepsy patients presenting ictal falls and could be a potential contributor to heart rate variability in some SUDEP cases. Sympathetic activity increases (while parasympathetic activity decreases) after seizures, suggesting that SUDEP could be triggered by cardiac arrhythmias during or immediately after seizures [2]. Recently, Montepietra et al. [7] reported five patients who developed ischemic ECG changes following seizures, some of them with post-ictal supraventricular tachycardia or atrial fibrillation. This suggests that tachyarrhythmias may con-

tribute to cardiovascular disease in patients with chronic epilepsy that potentially may lead the patient to torsades de pointes. Evaluation of this patient with EEG-video monitoring, including measurement of heart rate, contributed to identify ictal tachycardia that may have played a role in our SUDEP case related here.

Overall, premature mortality seems to be increased in patients with epilepsy, particularly in those with more severe seizures, and it is generally acknowledged that cardiac abnormality is the very probable cause of SUDEP.

Finally understanding the mechanisms behind SUDEP will be the key to prevention. In the mean time, it seems reasonable to assume that the best way to minimize the risk of SUDEP is effective seizure control [8]. Moreover, we believe that the neurologist should be aware of SUDEP and cardiovascular investigation should be recommended to search for abnormalities of HR or ischemic events. In the same way, strategies such as taking a detailed cardiovascular history, looking for cardiovascular disease, symptoms, cardiovascular risk factors and prior cardiac findings (electrocardiogram and echocardiogram) should be developed by a cardiologist or a general practitioner.

Acknowledgements

The authors do not report any conflict of interest regarding this work.

Financial support: FAPESP, CInAPCe-FAPESP, INCT/MCT and CNPq.

References

1. Nashef L. Sudden unexpected death in epilepsy: terminology and definitions. *Epilepsia*, 1997; 38: S6–S8.
2. Timmings PL. Sudden unexpected death in epilepsy: Is carbamazepine implicated? *Seizure*, 1998; 7: 289–291.
3. Ficker DM, So EL, Shen WK et al. Population-based study of the incidence of sudden unexplained death in epilepsy. *Neurology*, 1998; 51: 1270–1274.
4. Hallioglou O, Okuyaz C, Mert E, Makharoblidze K. Effects of antiepileptic drug therapy on heart rate variability in children with epilepsy. *Epilepsy Res*, 2008; 79: 49–54.
5. Ryvlin P, Montavont A, Kahane P. Sudden unexpected death in epilepsy: From mechanisms to prevention. *Curr Opin Neurol*, 2006; 19: 194–199.
6. Scorza FA, de Albuquerque M, Arida RM, Cavalheiro EA. Sudden unexpected death in epilepsy: Are winter temperatures a new potential risk factor? *Epilepsy Behav*, 2007; 10: 509–510.
7. Montepietra S, Cattaneo L, Granella F et al. Myocardial infarction following convulsive and nonconvulsive seizures. *Seizure*, 2009; 18: 379–381.
8. Tomson T, Nashef L, Ryvlin P. Sudden unexpected death in epilepsy: Current knowledge and future directions. *Lancet Neurol*, 2008; 7: 1021–1031.