

Propafenone overdose: Cardiac arrest and full recovery

Beata Woźakowska-Kapłon^{1, 2}, Alicja Stępień-Walek¹

¹1st Clinical Department of Cardiology, Swietokrzyskie Centre of Cardiology, Kielce, Poland

²Faculty of Health Studies, University of Humanities and Science in Kielce, Poland

Abstract

Intoxication caused by propafenone is very rare, and there are no known detailed epidemiological studies. We present the clinical manifestation of severe propafenone intoxication, successfully treated in a 17 year-old male. He was brought to the Intensive Care Unit after he had taken 3.0 g propafenone. The main clinical findings included: sudden cardiac arrest, coma, hypotension, left ventricular failure, bradycardia, sinoatrial block, atrioventricular junctional or/and ventricular tachycardia. During the treatment, transient heart pacing was performed and catecholamines were administered by means of continuous intravenous infusion of pressure doses as well as of infusion liquids. Cessation of toxic signs four hours after admission to hospital was observed. This relatively rare, fully symptomatic intoxication with propafenone deserved to be presented due to the drug's common usage in the treatment of dysrhythmia and life-threatening symptoms of overdosing. The course of the disease was dramatic and the patient survived only thanks to quick resuscitation, artificial ventilation, transient heart pacing, acidosis treatment and administration of pressure doses of catecholamines. (Cardiol J 2010; 17, 6: 619–622)

Key words: intoxication, propafenone, cardiological complications

Introduction

Intoxication with pharmaceuticals ingested in attempted suicides is frequently treated in intensive care units. A significant number of fatal suicides are related to intoxication with chemical agents and drugs which are mostly psychoactive. Cases of intoxication with propafenone are much rarer. We present cardiological complications in a 17 year-old male who ingested 3.0 g of propafenone in a suicide attempt.

Case report

A 17 year-old male, a student at a secondary comprehensive school, was brought to the Intensive Care Unit of a regional hospital in the second hour after a sudden circulatory arrest due to cardiac asystole. He had taken 10 tablets of propafenone (Rythmonorm 300 mg) in a suicide attempt; however this information was disclosed only on the third day of treatment. Before admission to hospital, the patient felt acute abdominal pain and then experi-

Address for correspondence: Beata Woźakowska-Kapłon, MD, PhD, 1st Clinical Department of Cardiology, Swietokrzyskie Centre of Cardiology, Grunwaldzka 45, 25–736 Kielce, Poland, tel./fax: +48 41 367 13 96, e-mail: bw.kaplon@gmail.com

Received: 4.10.2009

Accepted: 18.10.2009

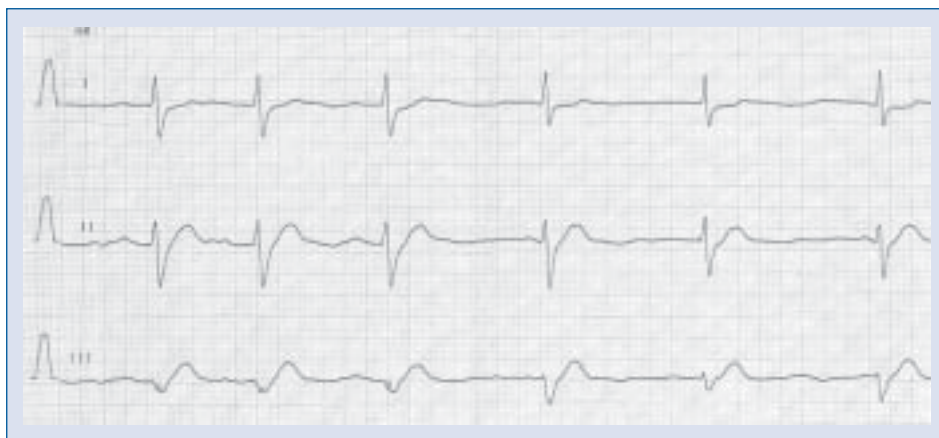

Figure 1. Sinus bradycardia (PQ 280–360 ms, QRS complexes 200–220 ms), transient sinus arrest or atrioventricular block 2:1. Atrioventricular junctional rhythm 43 bpm. Periodic isorhythmic dissociation.

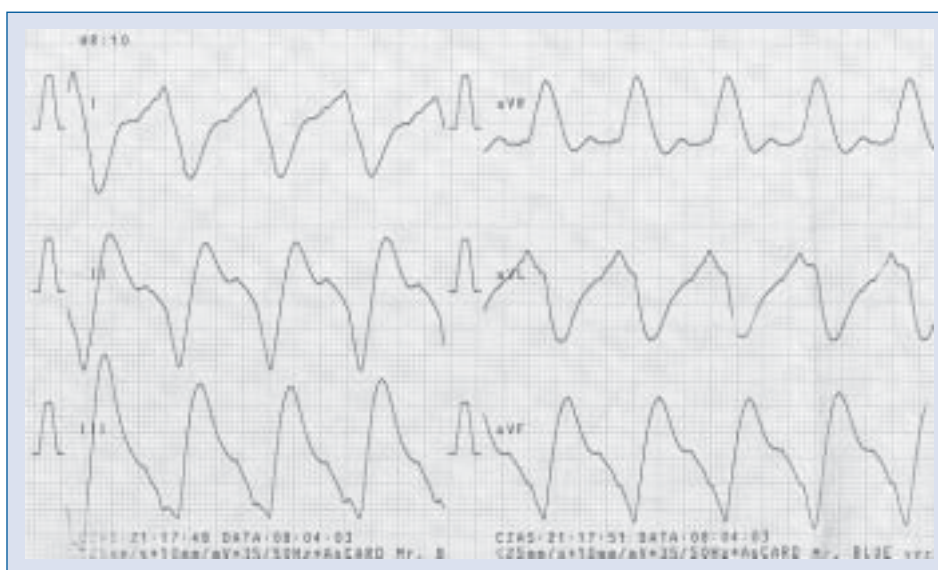


Figure 2. Wide QRS complex (400 ms) tachycardia 83 bpm: ventricular tachycardia or junctional tachycardia with aberrant intraventricular conduction.

enced a short loss of consciousness at home and then again, due to the sudden circulatory arrest, at the hospital's reception room. After a 30-minute resuscitation, the electrical and hemodynamic action of the heart was restored. On arrival at the Intensive Care Unit, the patient was in a critical condition. He was unconscious, respiratorily insufficient, intubated and artificially ventilated. Wide and symmetrical pupils reacted poorly to light. Thready pulse was detected in carotid and femoral arteries. There were no traumatic changes in the head. Cyanosis of the distal parts of limbs was present. The patient presented severe hypotonia, the arterial

blood pressure was 70/30 mm Hg. The heart rate was 40 bpm and quiet cardiac sounds were heard. Electrocardiography examination (ECG) detected sinus bradycardia with first-degree atrioventricular block (PQ 280 ms), periodically with sinoatrial block 2:1 or sinus node suppression with atrioventricular junctional rhythm of a rate 43 bpm and QRS complexes 200–220 ms (Fig. 1). Intermittent isorhythmic dissociation with junctional rhythm slightly faster than sinus rhythm 42–43 bpm was observed. In the following minutes, a tachycardia of 80–85 bpm appeared, with greatly widened QRS complexes of 400 ms (Fig. 2), which could be inter-

preted as atrioventricular junctional tachycardia with aberrant intraventricular conduction or ventricular tachycardia. Echocardiography examination performed at bedside showed severe hypokinesia and significantly lowered ejection fraction of 20%. Temporary heart pacing (70 bpm) was introduced. Medical treatment consisted of 10 mg adrenaline given in boluses and prolonged infusion, dopamine and dobutamine, 3 mg of glucagon, sodium bicarbonate as well as intravenous fluids. After four hours following the administration of catecholamines (dopamine and dobutamine) and heart stimulation the contractility improved and ejection fraction increased to 45% in a repeated echocardiography examination. Laboratory examinations showed transient and slight elevation in activity of transaminases (alanine transaminase 61 U/L and aspartate transaminase 69 U/L) and leucocytosis (11.2 G/L). Blood and urine samples were drawn for toxicological examination. There was no presence of drugs in the urine (opiates, amphetamine, cocaine and marijuana), while barbiturates and benzodiazepines had reached the level above threshold value (barely perceptible). There were no β -blockers in the blood serum. No chromatographic semiquantitative analysis of urine samples for the presence of propafenone metabolites was performed, as there was no information from the patient's family about any possibility of the boy taking this drug. During the following days of treatment, the patient's condition gradually improved: arterial blood pressure became stabilized and the diuresis was normal. The normal sinus rhythm reappeared during the second day of hospital treatment, and on the following day the patient regained consciousness and breathing. On the third day, the patient was separated from the respirator and extubated. The breathing was efficient, the patient gained full mental perceptiveness, and he admitted to an overdose of 10 tablets of propafenone (Rythmonorm 300 mg). Echocardiography showed normal myocardial contractility and ejection fraction was 65%. A 24-hour Holter ECG detected sinus rhythm of average frequency of 68 bpm with no dysrhythmia or conduction disturbances. Psychiatric examination showed neither psychotic disorders nor symptoms of depression. The patient did not have any suicidal thoughts and regarded his attempt as something negative. Adaptation disorders were detected. The patient was discharged in a good condition with the recommendation to continue outpatient treatment in a mental health clinic.

Discussion

Although propafenone is a very frequently used antidysrhythmic drug, intoxications caused by it are very rare and detailed epidemiological studies are not known.

Propafenone is a Vaughan Williams Class Ic antidysrhythmic agent. Propafenone has weak β -blocking effects (structure similar to that of propranolol), and blocks sodium channel both in the activated and inactivated state. It is totally absorbed but its bioavailability is unpredictable because of high first-pass hepatic elimination. It is metabolized into two major metabolites, 5-hydroxypropafenone (active) and norpropafenone. The metabolism of propafenone is genetically determined using the CYP 2D6 enzyme system. People lacking the required enzyme present markedly higher concentrations of propafenone, even at low doses. Poor metabolizers are much more susceptible to therapeutic and toxic effects of the drug. The half-time of the parent compound ranges from two to 12 hours, with a mean of six hours, and with a 10–12-hour range in poor metabolizers [1]. Propafenone prolongs refractoriness and slow sinoatrial node frequency, conduction in the atria and in the atrioventricular node. Because of its type Ic effects, it can aggravate His-Purkinje block. It is effective in treating supraventricular tachycardia and paroxysmal atrial fibrillation [1]. Propafenone has a negative inotropic effect, at least partially due to its beta-adrenergic and calcium channel blocking activity [1]. An overdose of propafenone causes: hypotonia, sleepiness, convulsions, PQ interval prolongation, conduction disorder, life-threatening dysrhythmia, ventricular tachycardia as well as ventricular flutter and fibrillation and cardiac arrest. Cardiovascular disorders in acute overdosing of propafenone constitute one of the major causes of dramatic disease and fatality [2]. Sudden circulatory arrest due to acute intoxication may occur in the mechanisms of asystole, ventricular fibrillation and electromechanical dissociation of the heart. Hemodynamic disorders may constitute both the cause and the outcome of dysrhythmia.

The toxic effects of overdosing propafenone have rarely been described in the literature [3–6]. Our case is worth paying attention to for several reasons. First of all, on the first day the patient's family failed to inform the hospital of the intoxication and therefore no lavage of the stomach was performed. The course of the disease was drama-

tic and the patient survived only thanks to quick resuscitation, artificial ventilation, transient heart pacing, acidosis treatment and administration of intravenous catecholamines. There is no efficient way of eliminating propafenone when overdosed apart from quickly performed lavage of the stomach [2]. A temporary pacing may prove inefficient in the case of severe electrical and mechanical heart depression. The reason for no response to the heart stimulation may be hyperkalemia, hypoxia and acidosis. Typically, in such a situation, intra-aortic counterpulsation should be implemented in order to maintain proper circulation. In the case of our patient, there was no need for such a treatment and there was a significant improvement following temporary pacing and the infusion of adrenaline and catecholamines. Circulatory insufficiency together with decreased peripheral resistance requires the administration of both inotropic positive and vasoconstrictive drugs (dopamine, dobutamine and noradrenaline) with intravenous administration of liquids. The case of our patient points to the fact that even in the case of a structurally healthy heart, a dose of 3 g of propafenone may be lethal. The great dynamics of electrical and hemodynamic changes require prompt action. In the first hours of treatment, our patient suffered from sinus bradycardia, sinus arrest, sinoatrial and atrioventricular block, junctional or ventricular tachycardia and significant disorders of intraventricular conduction (QRS 400 ms). It was impossible, due to intubation and the very serious condition of the patient, to perform electrocardiography from the esophageal electrodes. For this reason, it was difficult to recognize

origin of dysrhythmia strictly. The disorders, together with the ejection fraction reduced to 20%, caused a dramatic decrease in cardiac output, and severe hypotonia including circulatory arrest.

Conclusions

This is a case report of prolonged resuscitation following propafenone overdose resulting in a good outcome as a result of timely and aggressive supportive care.

Acknowledgements

The authors do not report any conflict of interest regarding this work.

References

1. Naccarelli GV, Sager PT, Singh BN. Antiarrhythmic agents. In: Podrid PJ, Kowey PR eds. Cardiac arrhythmias. Mechanisms, diagnosis and management. 2nd Ed. Lippincott-Williams & Wilkins, Philadelphia 2001: 265–301.
2. Benowitz N., Goldschiager N. Cardiac disturbances. In: Haddad L, Shannon M eds. Clinical management of poisoning and drug overdoses. 3rd Ed. Saunders Company, New York 1998: 1181.
3. Baszak J, Drozd J, Chlebus D. Suicidal intoxication with propranolol and propafenone in a 19 year old female. *Kardiol Pol*, 2001; 55: 556–559.
4. Brubacher J. Bicarbonate therapy for unstable propafenone-induced wide complex tachycardia. *Can J Emerg Med*, 2004; 6: 349–356.
5. Clarot F, Goullé JP, Horst M, Vaz E, Lacroix C, Proust B. Case report: Fatal propafenone overdoses. Case reports and a review of the literature. *J Analyt Toxicol*, 2003; 27: 395–399.
6. Kerns W Jr, English B, Ford M. Propafenone overdose. *Ann Emerg Med*, 1994; 24: 98–103.