

# “Cardiac Otalgia”: Acute coronary syndrome masquerading as bilateral ear pain

Mujeeb Sheikh<sup>1</sup>, Satjit Adlakha<sup>1</sup>, Mangeet Chahal<sup>1</sup>,  
Steven Bruhl<sup>1</sup>, Utpal Pandya<sup>1</sup>, Bilal Saeed<sup>2</sup>

<sup>1</sup>Department of Cardiovascular Diseases, The University of Toledo Medical Center, Toledo, OH, USA

<sup>2</sup>Department of Internal Medicine, The University of Toledo Medical Center, Toledo, OH, USA

## Abstract

*Patients presenting with acute coronary syndromes are classically described as having chest pressure with radiation to the left arm. However, pain can be referred to multiple sites including the face, the neck, the abdomen and the contra-lateral arm. We present a case of sudden bilateral ear pain as the sole presentation of acute coronary syndrome in an elderly man. The importance of recognizing these atypical presentations is vital, as outcomes may be worsened as appropriate therapy may be delayed or misdirected. (Cardiol J 2010; 17, 6: 623–624)*

**Key words:** acute coronary syndrome, ear pain

## Introduction

Many patients seeking medical care for various somatic complaints may in fact have an acute coronary syndrome (ACS). These varied presentations can lead the physician away from maintaining a high degree of clinical suspicion for a referred cardiac pain, and can result in a delay in care or mismanagement, ultimately resulting in significant morbidity and mortality. Females, older patients and those with diabetes mellitus or heart failure are a large proportion of the medical population who present in an atypical fashion [1]. We present an interesting case of a patient who was having an ACS, but only complained of bilateral ear pain, an uncommon site of referred cardiac ischemic pain.

## Case report

An 85 year-old male presented to the emergency department with a history of sharp bilateral ear pain as his only complaint. His otoscopic examination was unremarkable and he was given Tylenol for symptomatic relief. He had a known history of

non-obstructive coronary artery disease diagnosed by an elective cardiac catheterization two years ago. The catheterization had revealed a 45% stenosis of the proximal left anterior descending coronary artery and 50% stenosis of proximal left circumflex coronary artery. Given this history, the patient was administered aspirin and sublingual nitroglycerin 35 minutes after presentation, which resolved his ear pain within five minutes. In view of a dramatic response to antianginal medication, an electrocardiogram (ECG) and serial cardiac enzymes were drawn. The ECG revealed normal sinus rhythm and a right bundle branch block with no evidence of ischemia or injury. His initial troponin level was 8.7 ng/mL (normal value < 0.05 ng/mL).

The patient was managed for the diagnosis of non ST segment elevation myocardial infarction with appropriate therapy. Eight hours later, the patient developed atrial fibrillation with rapid ventricular response and hemodynamic instability. Urgent bedside echocardiography revealed moderately reduced left ventricular function and wall motion abnormalities of the anterior septum and

**Address for correspondence:** Bilal Saeed, MD, University of Toledo Medical Center, 3000 Arlington Avenue, MS 1150 Toledo, OH 43614, USA, tel: (567) 277 1862, e-mail: [bilal.saeed@utoledo.edu](mailto:bilal.saeed@utoledo.edu)

Received: 15.10.2009

Accepted: 18.10.2009

posterior wall of left ventricle. Dopamine was administered and cardiac catheterization was offered to the patient. Both the patient and his family decided to pursue comfort measures only. Over the next 24 hours, congestive heart failure ensued and the patient had an asystolic cardiac arrest and expired. An autopsy examination was declined by the family.

### Discussion

Cardiac chest pain is typically described as a precordial or retrosternal pressure with radiation to the ulnar side of the left arm. It can however, be referred to various craniofacial structures including the neck, jaw, tooth, ear, mandible or temporomandibular joint. In a prospective study evaluating referred cardiac chest pain, Kreiner et al. [2] noted craniofacial pain as a sole manifestation of ischemia in 6% (n = 185) of patients. Furthermore, bilateral ear pain was seen only in 11 patients and unilateral ear pain was seen only in two patients.

Cardiac ischemia leads to the excitation of both sympathetic and parasympathetic fibers that transmit pain signals from the heart, allowing for a wide range of clinical presentations in ACS [3]. In addition to carrying visceral (cardiac) afferent fibers, the vagus nerve also supplies the external auditory canal through the nerve of Arnold [4]. Stimulation of these vagal afferent fibers causes spinothalamic neuron excitation in the C1–C3 segments of the spinal cord [5]. The somatic receptor fields for these spinal cord segments are found commonly in the neck, ear and jaw (Fig. 1). These pathways and the connections between the vagal nerve afferents and trigeminal nerve contribute to pain perception in these distributions [6]. However, due to overlapping terminations of afferent neurons and the variations in the individual innervations patterns, ear pain as the sole location of referred cardiac pain is rarely reported in literature [7, 8]. Despite this rarity, physicians should be aware of this presentation and act appropriately to ensure timely and proper care.

### Conclusions

In our patient, the relief of ear pain with aspirin and nitroglycerin lead us to further evaluate for an ACS which, when discovered, had already resulted in delayed therapy. Despite this, we felt that the final outcome would have not been different as our patient and his family declined further intervention and requested comfort care measures only.

We hope that this article highlights the importance of understanding the complex neural intervention of the heart and the many possible presentations

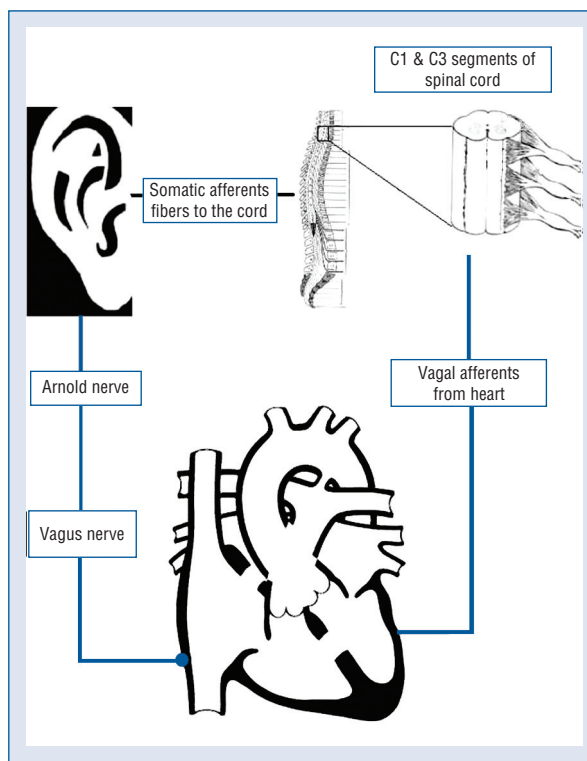


Figure 1. Anatomical basis for referred cardiac pain to ear.

of referred cardiac pain, as a delayed or missed diagnosis can lead to serious morbidity and mortality.

### Acknowledgements

The authors do not report any conflict of interest regarding this work.

### References

1. Everts B, Karlson BW, Wahrborg P et al. Localization of pain in suspected acute myocardial infarction in relation to final diagnosis, age and sex, and site and type of infarction. *Heart Lung*, 1996; 25: 430–437.
2. Kreiner M, Okeson JP, Michelis V et al. Craniofacial pain as the sole symptom of cardiac ischemia: A prospective multicenter study. *J Am Dent Assoc*, 2007; 138: 74–79.
3. Minisi AJ, Thames MD. Activation of cardiac sympathetic afferents during coronary occlusion. Evidence for reflex activation of sympathetic nervous system during transmural myocardial ischemia in the dog. *Circulation*, 1991; 84: 357–367.
4. Voronov P, Tobin MJ, Billings K et al. Postoperative pain relief in infants undergoing myringotomy and tube placement: Comparison of a novel regional anesthetic block to intranasal fentanyl. A pilot analysis. *Paediatr Anaesth*, 2008; 18: 1196–1201.
5. Chandler MJ, Zhang J, Qin C et al. Intrapericardiac injections of algogenic chemicals excite primate C1–C2 spinothalamic tract neurons. *Am J Physiol Regul Integr Comp Physiol*, 2000; 279: R560–R568.
6. Chandler MJ, Qin C, Yuan Y et al. Convergence of trigeminal input with visceral and phrenic inputs on primate C1–C2 spinothalamic tract neurons. *Brain Res*, 1999; 829: 204–208.
7. Durso BC, Israel MS, Janini ME et al. Orofacial pain of cardiac origin: A case report. *Cranio*, 2003; 21: 152–153.
8. Rothwell PM. Angina and myocardial infarction presenting with pain confined to the ear. *Postgrad Med J*, 1993; 69: 300–301.