

# Recurrent ventricular arrhythmias and myocardial infarctions associated with cocaine induced reversible coronary vasospasm

Aytul Belgi Yildirim, Ibrahim Basarici, Murathan Kucuk

Akdeniz University, School of Medicine, Department of Cardiology, Antalya, Turkey

## Abstract

*Cocaine has become the most frequently used illicit drug among patients presenting to emergency departments worldwide. Although acute myocardial infarction is the most common reported cardiovascular manifestation in this setting, there are many other potential cardiotoxic effects of cocaine use including coronary artery spasm, arrhythmia, and sudden death. We report the case of a 54 year-old male with angiographically documented reversible coronary arterial spasm leading to severe life-threatening recurrent ventricular arrhythmias and electrocardiographic changes suggesting acute myocardial infarction secondary to cocaine use. Recurrent ventricular arrhythmias of this patient required implantation of a cardioverter-defibrillator which successfully treated following arrhythmia episodes. (Cardiol J 2010; 17, 5: 512–517)*

**Key words: cocaine, arrhythmias, vasospasm, myocardial infarction, cardioverter-defibrillator**

## Introduction

Cocaine use is a growing problem worldwide. As a result, the number of cocaine-related emergency department visits, hospital admissions and deaths have increased. Acute myocardial infarction (MI) is the most common cardiac consequence of cocaine use, but significant arrhythmias are also reported [1]. The early diagnosis of cocaine-associated cardiovascular complications are essential for appropriate management. The etiology of cocaine-induced myocardial ischemia is complex and multifactorial [2]. Cocaine appears to cause acute myocardial ischemia or infarction in patients with and without pre-existing coronary artery disease. By means of the presented case, this paper focuses on the diagnosis and treatment of cardiovascular events in cocaine users.

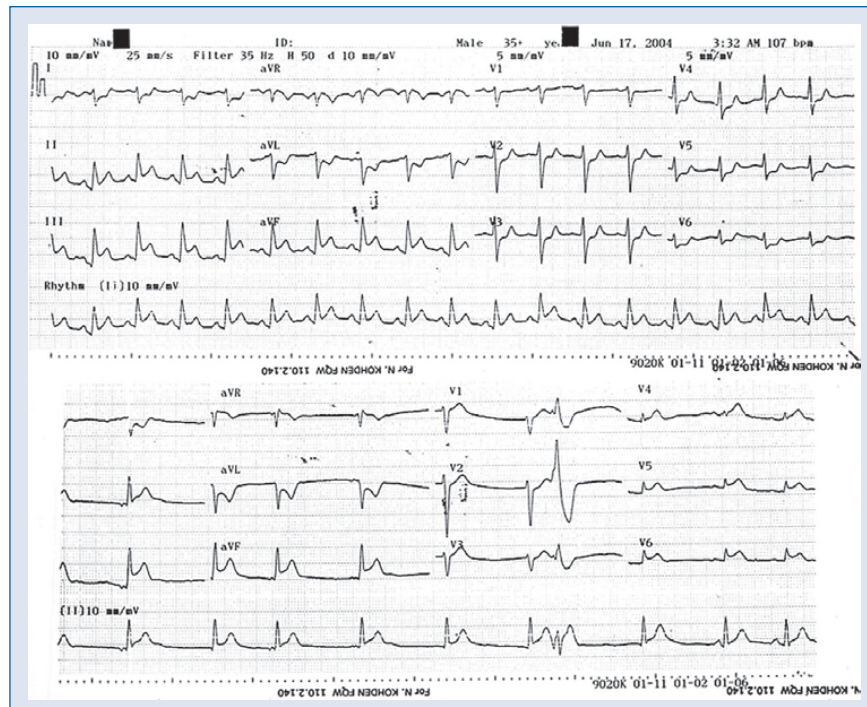
## Case report

Five years ago, a 54 year-old man was admitted to the emergency room complaining of severe chest pain. He had no established cardiovascular risk factor. However, his family warned us that he was a cocaine addict, usually via the powder form by nasal insufflation. Physical examination revealed a blood pressure of 110/70 mm Hg and irregular pulse 151 bpm without additional pathologic findings. Initial electrocardiogram (ECG) evaluation demonstrated atrial fibrillation with rapid ventricular response and 1 mm ST depression in derivations V4–V6. Admission troponin T level was slightly increased (0.42 ng/mL) and other laboratory parameters were normal. The patient was managed as acute coronary syndrome and was scheduled for coronary angiography the next day. Meanwhile,

**Address for correspondence:** Aytul Belgi Yildirim, MD, Associate Professor in Cardiology, Akdeniz Universitesi Hastanesi, Kardiyoloji Anabilim Dalı, 07059 Antalya, Turkey, tel: 0090 242 2496772, fax: 0090 242 2274490, e-mail: [aytul.belgi@gmail.com](mailto:aytul.belgi@gmail.com)

Received: 18.09.2009

Accepted: 18.10.2009

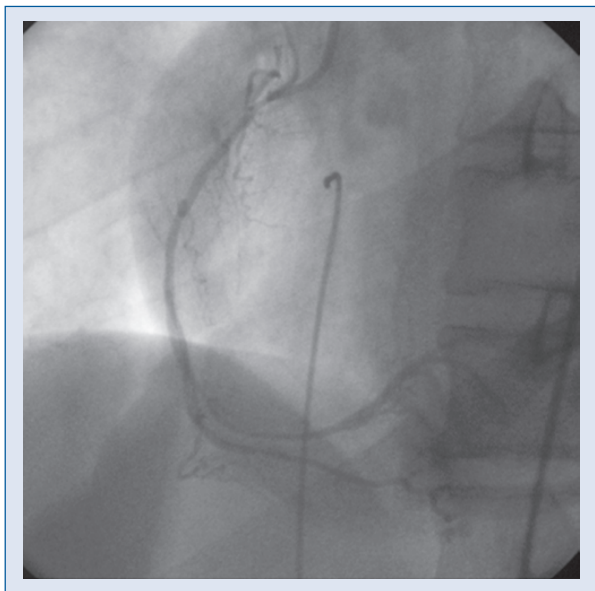


**Figure 1.** Electrocardiography (ECG) traces of the patient: 12-lead ECG (upper tracing) demonstrates ST segment elevations in inferior derivations with reciprocal changes in lateral derivations, whereas ST segment elevation in between V4R and V6R is apparent in right ventricular derivations (lower tracing) indicating an accompanying right ventricular infarction.

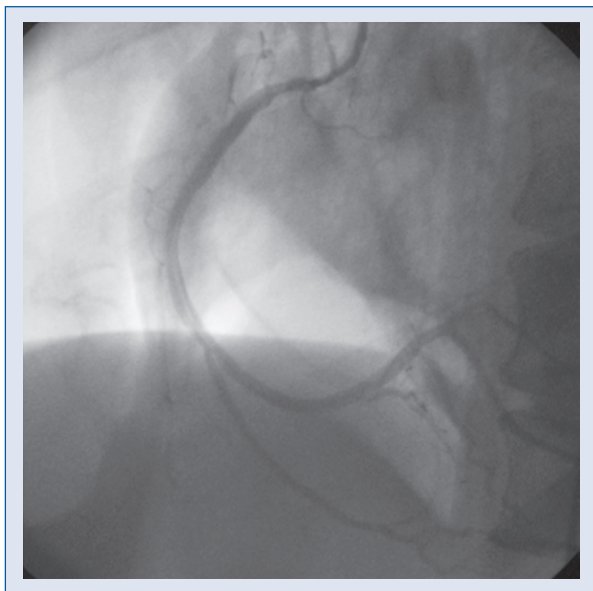
after administration of intravenous beta blocker for rate control, atrial fibrillation resolved spontaneously in the coronary care unit. The patient was discharged on acetylsalicylic acid treatment based on a coronary angiography result indicating non-significant coronary artery disease (only a plaque was determined in mid left anterior descending artery) and normal left ventriculography. He was informed of his condition in detail and of the effects of cocaine on the heart. He was encouraged to stop using cocaine, advised to seek medical help from a psychiatrist experienced in treating drug addicts, and arranged an appointment after discharge. However, on the following day the patient was readmitted to the emergency department with severe prolonged chest pain and palpitation. His ECG demonstrated ST segment elevation in inferior and right ventricular derivations (Fig. 1) with reciprocal changes in lateral derivations. Subsequently, cardiac arrest related to ventricular fibrillation developed in the emergency room. After defibrillation and resuscitation, the patient was transferred to the cath lab for primary percutaneous intervention. Coronary angiography revealed a long and severe stenosis in the mid and distal portions of the right coronary artery. Administration of nitroglycerin resolved this

severe narrowing and ST elevation was normalized suggesting a vasospastic phenomenon. Echocardiographic examination showed mild inferior hypokinesia, with a left ventricular ejection fraction of 58%. After an uneventful clinical course, the patient was discharged on maximum tolerable dose of oral nitrate therapy and registered for a detox program.

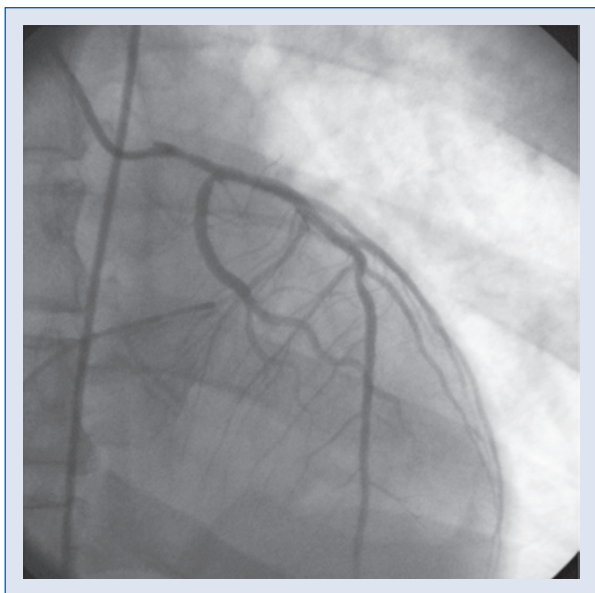
One month later, the patient was readmitted to the emergency department with cardiac arrest due to recurrent ventricular fibrillation. After defibrillation and cardiopulmonary resuscitation, bicarbonate and lidocaine therapy were administered for arrhythmia management. Electrocardiography revealed mild ST segment elevation in anterior derivations. Based on the history of the patient, and his unstable condition, an emergency control coronary angiography was performed. This time severe and diffuse narrowings through the right coronary artery and the left main coronary artery trunk were determined (Figs. 2, 3). The presence of a new stenosis which had been absent from the previous angiogram hinted at the diagnosis of vasospasm, which was proved by the complete disappearance of both lesions (Figs. 4, 5) after administration of intracoronary nitroglycerin to each coronary artery. Consequently, a calcium channel blocker



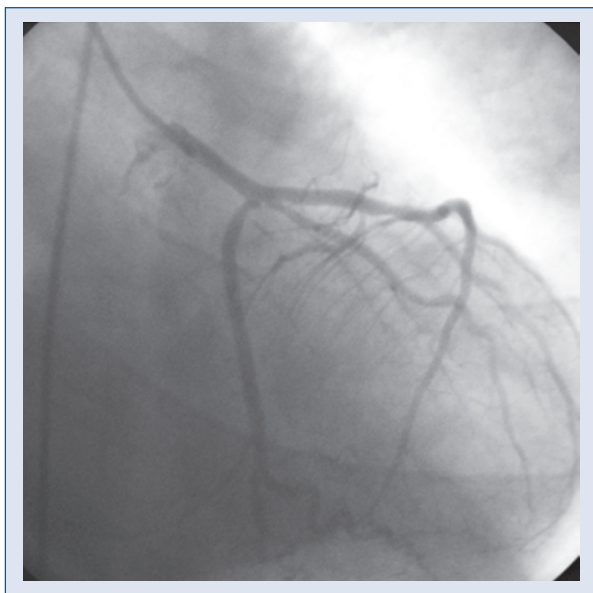
**Figure 2.** Coronary angiogram of the patient: right coronary artery injection (in left oblique view) shows diffuse narrowing throughout the whole coronary artery which is prominent in the distal segment.



**Figure 4.** Coronary angiogram of the patient: after administration of selective intracoronary nitrate, right coronary artery injection (in left oblique view) proves the relief of diffuse vasospasm in the right coronary artery which has reached its original native diameter.



**Figure 3.** Coronary angiogram of the patient: left coronary artery injection (in anteroposterior view) depicts diffuse narrowing in the left main coronary artery trunk. Also a plaque is noted in mid-portion of left anterior descending coronary artery which is concordant with the one described in the previous angiography of the patient.



**Figure 5.** Coronary angiogram of the patient: after administration of selective intracoronary nitrate, left coronary artery injection (in right caudal view) demonstrates that vasospasm in the left main coronary artery trunk has resolved.

in maximum tolerable dose was added to the oral nitrate treatment. He was advised to continue the cocaine detox program.

Seventeen months later, during a hospital stay for atypical chest pain complaints (while he was still under double vasodilator therapy) the patient suf-

ferred an in-hospital ventricular fibrillation episode and cardiac arrest. After resuscitation, his ECG demonstrated normal findings without any elevation in serial cardiac troponin measurements. Due to recurrent ventricular fibrillation under maximum dosage of oral nitrate and calcium channel blocker therapy, the patient underwent single chamber cardioverter-defibrillator (ICD) implantation and was discharged from hospital four days after the procedure. At the six month follow-up, interrogation of the device revealed two episodes of ventricular tachycardia which were effectively interrupted by ICD. No subsequent adverse event was seen at the 12 month follow-up.

## Discussion

As cocaine use has become widespread, cocaine-related cardiovascular morbidity and mortality have increased worldwide. It has been associated with various cardiovascular complications including angina pectoris, MI, arrhythmia, heart failure and sudden cardiac death [3]. There are several proposed mechanisms for the cardiotoxic effects of cocaine. Increased myocardial oxygen demand (by increasing heart rate, blood pressure and contractility), coronary vasoconstriction, platelet activation and accelerated premature atherosclerosis are proposed mechanisms in patients with cocaine-induced MI or ischemia [2, 3]. Cocaine-associated vasoconstriction occurs via stimulation of the  $\alpha$ -adrenergic receptors on smooth muscle cells in the coronary arterial bed [4]. Moreover increased endothelin and decreased nitric oxide productions by the endothelium related to cocaine use also contributes in vasoconstriction and may further aggravate coronary arterial spasm [5, 6]. It has been reported that even recreational doses of cocaine are associated with vasoconstriction of coronary arteries [2]. Although MI or coronary vasoconstriction may be more accentuated in patients with pre-existing coronary artery disease, they had also been documented in patients with normal coronary arteries [7].

There is also evidence that besides inducing myocardial ischemia, cocaine can trigger cardiac arrhythmias, probably as a result of the enhanced sympathetic state and the direct effects on the heart. Ventricular arrhythmias occurring immediately after cocaine use are more likely to result from the local anesthetic effects on the myocardium, rather than late onset arrhythmias which are generally secondary to myocardial ischemia [8]. Cocaine influences alterations in ion channels (by blocking potassium channels, increasing L-type calcium

channel current, and inhibiting sodium influx) resulting in both repolarization and depolarization abnormalities which makes the myocardium susceptible to different arrhythmias [3, 9]. Common clinical manifestations of these electrophysiological alterations involve QT prolongation on ECG, idioventricular rhythms, wide complex tachycardias, torsade de pointes and ventricular fibrillation [9–11].

Chest pain is the commonest symptom in cocaine users and accounts for approximately 16% of all cocaine-related admissions [12]. Differential diagnosis of cocaine-associated chest pain involves musculoskeletal complications, acute pulmonary syndrome, pulmonary hypertension, aortic dissection and barotrauma-related injuries including pneumomediastinum, pneumothorax, and pneumopericardium related to cocaine use [13–16].

Evaluating cocaine-associated chest pain is similar to evaluating patients with acute coronary syndromes, and involves ECG, serial cardiac markers, and some forms of stress testing. The incidence of cocaine-associated MI varies (0.7% to 6%) between studies implementing different diagnostic criteria [8]. It has been reported that after cocaine use, patients may present with chest pain similar to angina pectoris and their electrocardiographic ST segment changes mimic MI [17]. Although this paper reports a low incidence of MI and favorable in-hospital prognosis, it is worth noting that total and MB fraction of creatine kinase was utilized to confirm MI as the available biomarker at that time. Cocaine ingestion may cause rhabdomyolysis with consequent elevation in myoglobin and total creatine kinase levels. Therefore cardiac troponins are preferred markers for the diagnosis of cocaine-associated MI [8]. The use of standard ECG criteria (ST elevation) alone for the diagnosis of an acute MI in cocaine users is insufficient to determine administration of fibrinolytic therapy. However percutaneous coronary intervention should be the preferred approach, because it can precisely establish the diagnosis and additionally provides therapeutic options.

In the American Heart Association scientific statement, some therapeutic options are recommended in the management of cocaine-associated chest pain and MI [8]. Nitroglycerin, verapamil and phentolamine are the agents of choice in treating patients with cocaine-associated chest pain or cocaine-induced vasospasm. In our patient, severe coronary spasm could be ascertained and rapidly reversed with nitroglycerin injection during cardiac catheterization. Benzodiazepines are also useful in the relief of cocaine-associated chest pain by



reducing the heart rate and arterial pressure. Long acting nitrates and calcium channel blockers may be used as long-term therapy to cure anginal symptoms, but are not indicated for routine use. Beta-blockers are not recommended (except for patients with left ventricular dysfunction or coronary artery disease) in the setting of cocaine abuse [3] because of concerns about provoking coronary spasm.

The treatment of ventricular arrhythmias depends on the interval between cocaine use and arrhythmia onset. If an arrhythmia occurs immediately after cocaine use, it will likely benefit from administration of sodium bicarbonate. On the other hand, late onset arrhythmias are probably secondary to myocardial ischemia associated with cocaine use and vasodilator therapy should be the mainstay of the treatment [8]. Standard management for ventricular arrhythmias, including lidocaine, is reasonable for persistent or recurrent ventricular arrhythmias. In our patient, ventricular arrhythmias on the first and second admissions were considered to be related to ischemia associated with cocaine-induced vasospasm. So nitrate and calcium channel blockers at maximum tolerable dose were prescribed for long term management. Torsades de pointes or QT prolongation that would be the mechanism of cocaine-associated arrhythmia was not documented in our patient.

We thought that the severe life-threatening arrhythmia of the patient on his third admission was probably a result of the enhanced sympathetic state and the direct cardiotoxic effects of cocaine on the heart. Therefore, a single chamber ICD implantation was performed for secondary prevention. Our case shows that cocaine use can be associated with severe life-threatening arrhythmias with or without myocardial infarction caused by coronary vasospasm. There are no extensive specified reports on ICD implantation and its benefits in cocaine addicts. But according to a retrospective report [18], clinicians should consider and be aware of the possibility of increased defibrillation thresholds in cocaine users, something which was also verified in our case (31 joules).

Cocaine use can be ascertained by self-report or by urine, blood and hair analysis. Self-reported use of cocaine can be obtained easily. However a potential significant drawback is under-reporting by patients. Quantitative methods are more expensive, and also potentially misleading because of individual variability in cocaine metabolism and excretion [19]. Secondary prevention by detox programs may reduce cardiovascular and other morbidity associated with cocaine use. Recurrent

chest pain, MI and deaths are frequent among patients who continue to use cocaine [7]. In the presented case, detox attempts were unsuccessful and the patient was still using cocaine on each hospital admission which was responsible for recurrent cardiovascular events. We should underline that detox programs should be the mainstay of management for cocaine addicts. ICD implantation should be considered only for a select group of patients who have cardiomyopathy and low ejection fraction related to cocaine use, or in patients for whom detox programs have failed to cease their use of cocaine and who have recurrent ventricular arrhythmias.

## Conclusions

Cocaine use can cause lethal cardiovascular events including MI and ventricular arrhythmias. The possibility of cocaine use should be seriously considered in any young patient with minimal risk factors for cardiac disease presenting with MI and cardiac arrhythmias. The prognosis of patients with cardiovascular manifestations depends on whether they cease using cocaine or not. Our case indicates that implantation of an implantable cardioverter-defibrillator is an option for addicts presenting with recurrent ventricular tachycardia or fibrillation who cannot cease using cocaine by detox programs.

## Acknowledgements

The authors do not report any conflict of interest regarding this work.

## References

1. Bauman JL, DiDomenico RJ. Cocaine-induced channelopathies: Emerging evidence on the multiple mechanisms of sudden death. *J Cardiovasc Pharmacol Ther*, 2002; 7: 195–202.
2. Benzaquen BS, Cohen V, Eisenberg MJ. Effects of cocaine on the coronary arteries. *Am Heart J*, 2001; 142: 402–410.
3. Phillips K, Luk A, Soor GS, Abraham JR, Leong S, Butany J. Cocaine cardiotoxicity: A review of the pathophysiology, pathology, and treatment options. *Am J Cardiovasc Drugs*, 2009; 9: 177–196.
4. Moliterno DJ, Willard JE, Lange RA et al. Coronary-artery vasoconstriction induced by cocaine, cigarette smoking, or both. *N Engl J Med*, 1994; 330: 454–459.
5. Wilbert-Lampen U, Seliger C, Zilker T, Arendt RM. Cocaine increases the endothelial release of immunoreactive endothelin and its concentrations in human plasma and urine: reversal by incubation with sigma-receptor antagonists. *Circulation*, 1998; 98: 385–390.
6. Mo W, Singh AK, Arruda JA, Dunea G. Role of nitric oxide in cocaine induced acute hypertension. *Am J Hypertens*, 1998; 11 (Part 1): 708–714.

7. Zimmerman FH, Gustafson GM, Kemp HG Jr. Recurrent myocardial infarction associated with cocaine abuse in a young man with normal coronary arteries: evidence for coronary artery spasm culminating in thrombosis. *J Am Coll Cardiol*, 1987; 9: 964–968.
8. McCord J, Jneid H, Hollander JE et al.; American Heart Association Acute Cardiac Care Committee of the Council on Clinical Cardiology. Management of cocaine-associated chest pain and myocardial infarction: A scientific statement from the American Heart Association Acute Cardiac Care Committee of the Council on Clinical Cardiology. *Circulation*, 2008; 117: 1897–1907.
9. Wood DM, Dargan PI, Hoffman RS. Management of cocaine-induced cardiac arrhythmias due to cardiac ion channel dysfunction. *Clin Toxicol (Philadelphia)*, 2009; 47: 14–23.
10. Kerns W 2<sup>nd</sup>, Garvey L, Owens J. Cocaine-induced wide complex dysrhythmia. *J Emerg Med*, 1997; 15: 321–329.
11. Magnano AR, Talathoti NB, Hallur R et al. Effect of acute cocaine administration on the QTc interval of habitual users. *Am J Cardiol*, 2006; 97: 1244–1246.
12. Albertson TE, Marelich GP, Tharratt RS. Cocaine. In: Haddad LM, Shannon MW, Winchester JF eds. *Clinical management of poisoning and drug overdose*. 3<sup>rd</sup> Ed. WB Saunders Company, Philadelphia 1998: 542–551.
13. Eagle KA, Isselbacher EM, DeSanctis RW; International Registry for Aortic Dissection (IRAD) Investigators. Cocaine-related aortic dissection in perspective. *Circulation*, 2002; 105: 1529–1530.
14. Forrester JM, Steele AW, Waldron JA, Parsons PE. Crack lung: An acute pulmonary syndrome with a spectrum of clinical and histopathologic findings. *Am Rev Respir Dis*, 1990; 142: 462–467.
15. Albrecht CA, Jafri A, Linville L, Anderson HV. Cocaine-induced pneumopericardium. *Circulation*, 2000; 102: 2792–2794.
16. Uva JL. Spontaneous pneumothoraces, pneumomediastinum, pneumoperitoneum: Consequences of smoking crack cocaine. *Pediatr Emerg Care*, 1997; 13: 24–26.
17. Gitter MJ, Goldsmith SR, Dunbar DN, Sharkey SW. Cocaine and chest pain: Clinical features and outcome of patients hospitalized to rule out myocardial infarction. *Ann Intern Med*, 1991; 115: 277–282.
18. Chen J, Naseem RH, Obel O, Joglar JA. Habitual cocaine use is associated with high defibrillation threshold during ICD implantation. *J Cardiovasc Electrophysiol*, 2007; 18: 722–725.
19. Winhusen TM, Somoza EC, Singal B, Kim S, Horn PS, Rotrosen J. Measuring outcome in cocaine clinical trials: A comparison of sweat patches with urine toxicology and participant self-report. *Addiction*, 2003; 98: 317–324.