

# Fasciculoventricular accessory pathway: A misleading and unusual bypass tract

Marek Jastrzębski<sup>1</sup>, Piotr Kukla<sup>2</sup>

<sup>1</sup>1<sup>st</sup> Department of Cardiology and Hypertension, University Hospital, Kraków, Poland

<sup>2</sup>Department of Internal Medicine, Specialistic Hospital, Gorlice, Poland

## Abstract

*We present the case of a 25 year-old man referred for an electrophysiological study due to suspected pre-excitation as the cause of two recent syncopal episodes. The admission electrocardiogram (ECG) showed a borderline PR interval of 120 ms and apparently small delta waves visible in leads V2–V4. Intracardiac recordings showed a short HV interval of 18 ms that was stable despite decremental atrioventricular conduction. A fasciculoventricular accessory pathway was diagnosed. Administration of ajmaline normalized ECG and HV interval. We discuss electrocardiographical features of this rare bypass tract. (Cardiol J 2010; 17, 1: 83–87)*

**Key words:** pre-excitation, fasciculoventricular accessory pathway, syncope, delta wave

## Case report

A 25 year-old man was referred for an electrophysiological study due to suspected pre-excitation as the cause of two recent syncopal episodes. He also had a history of occasional, well-tolerated, short-lasting episodes of heart palpitations, and of empirical antiepileptic pharmacotherapy administered during childhood after apparently similar syncopal episodes.

The admission electrocardiogram (ECG) showed a borderline PR interval of 120 ms and apparently small delta waves visible in leads V2–V4 (Fig. 1A). The Wolff-Parkinson-White diagnosis was further supported by an intracardiac electrogram showing a short HV interval of 18 ms (Fig. 1B). Despite very proximal positioning of the His bundle catheter (to avoid recording the right bundle branch potential) it was not possible to obtain a His bundle deflection that would not merge with ventricular depolarization (Fig. 1C). Other electrophysiological study findings were a PA interval of 22 ms, an AH

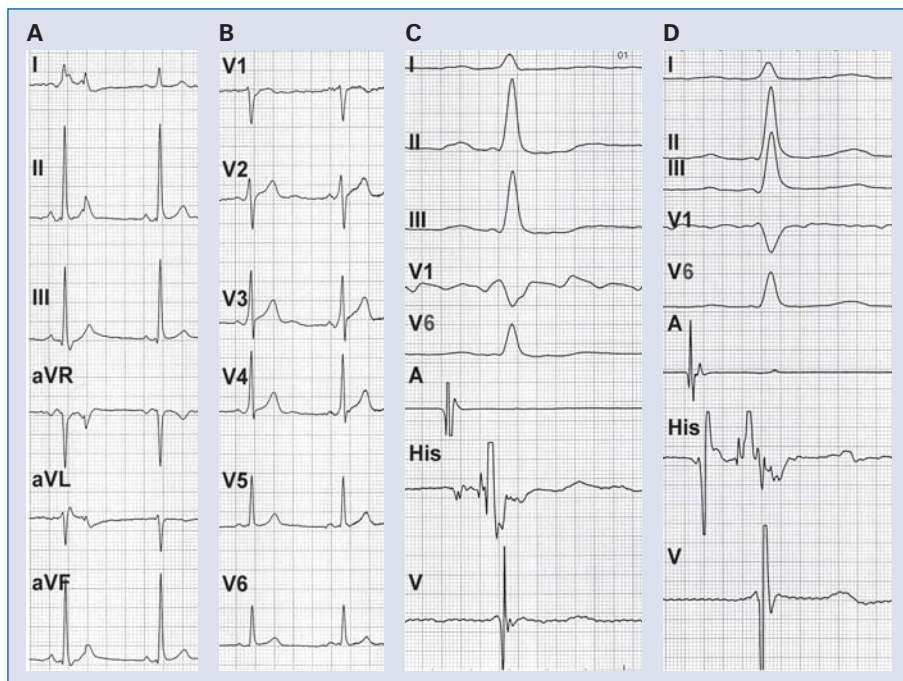
interval of 80 ms, a Wenckebach block cycle length of 380 ms, dual atrioventricular nodal physiology with occasional single ‘echo’ beats, and a retrograde Wenckebach cycle length of 420 ms with a concentric retrograde atrial activation pattern on coronary sinus catheter.

However, surprisingly, despite features suggestive of pre-excitation, QRS morphology remained constant without any change in the degree of pre-excitation during incremental atrial pacing and during premature atrial extrastimuli. Moreover, a non-sustained narrow QRS tachycardia that was induced (Fig. 2) presented QRS morphology identical to that seen during sinus rhythm. This was incompatible with an atrioventricular AP. Because of the differences in conduction properties between atrioventricular (AV) node and AP, the degree of pre-excitation (especially in a case of minimal pre-excitation) is variable during incremental atrial pacing and during premature atrial extrastimuli. In contrast, a pre-excitation pattern similar to that observed with a superoparaseptal AP (as in the

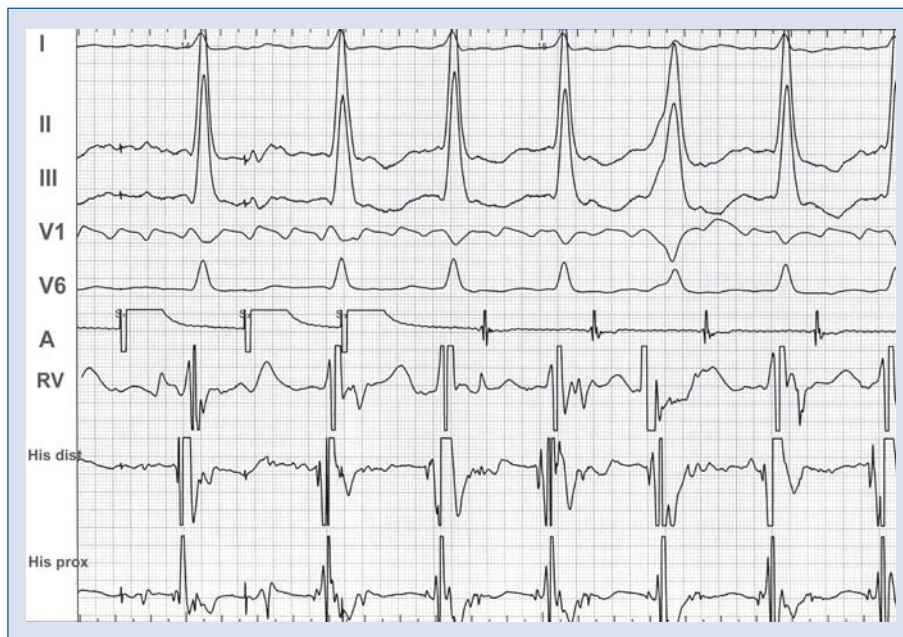**Address for correspondence:** Marek Jastrzębski, MD, 1<sup>st</sup> Department of Cardiology and Hypertension, Kopernika 17, 31–501 Kraków, Poland, tel: +48 12 424 73 00, fax: +48 12 424 73 20, e-mail: [mcjastrz@cyf-kr.edu.pl](mailto:mcjastrz@cyf-kr.edu.pl)

Received: 02.01.2009

Accepted: 16.04.2009



**Figure 1.** A. A 12-lead electrocardiogram showing subtle pre-excitation; B. Intracardiac electrograms with a standard His catheter location; C. Intracardiac electrograms with a proximal His catheter location; A — atrial, V — ventricular.



**Figure 2.** Tachycardia induction using double atrial extrastimuli:  $S_1S_1 = 500$  ms,  $S_1S_2 = 350$  ms,  $S_2S_3 = 270$  ms. The key aspect of this tracing is that the HV interval and the degree of pre-excitation remained constant, despite four different AH intervals, strongly suggestive of bystander fasciculoventricular AP.

present case) and a fixed HV interval with a constant degree of pre-excitation during incremental atrial pacing, premature atrial stimuli or supraventricular tachycardia, are hallmarks of a fasciculoventricular AP [1–3].

The induced tachycardia showed pre-excitation identical to that during sinus rhythm, since in both situations the fasciculoventricular AP acted as a bystander. The P waves during the tachycardia, which were visible after the QRS complexes, were evidently positive in leads II and III (Fig. 2), excluding from the diagnosis atrioventricular nodal reentrant tachycardia. Concentric and decremental retrograde activation pattern during ventricular pacing narrowed the differential diagnosis to atrial tachycardia or atrioventricular reentry tachycardia using a concealed superior or superoparaseptal AP. Moreover, Figure 2 shows fortuitous right ventricular premature depolarization originating close to the tip of the right ventricular catheter (positioned at the midseptum) and appearing 20 ms before the His bundle that did not influence the timing of subsequent atrial depolarization, a finding strongly arguing against the presence of a concealed atrioventricular AP. Therefore, a probable diagnosis of focal atrial tachycardia was made. Due to the difficult inducibility and short-lasting nature of the arrhythmia, this diagnosis could not be confirmed by entrainment or other differentiating maneuvers. However, the induced arrhythmia that was well tolerated, short lasting and inducible only on high-dose isoprenaline, was considered of little or no clinical significance and the procedure was aborted at this stage. Finally syncope was attributed to epilepsy and empirical anti-epileptic therapy was re-introduced. During ambulatory follow-up of 10 months — syncope did not recur.

## Discussion

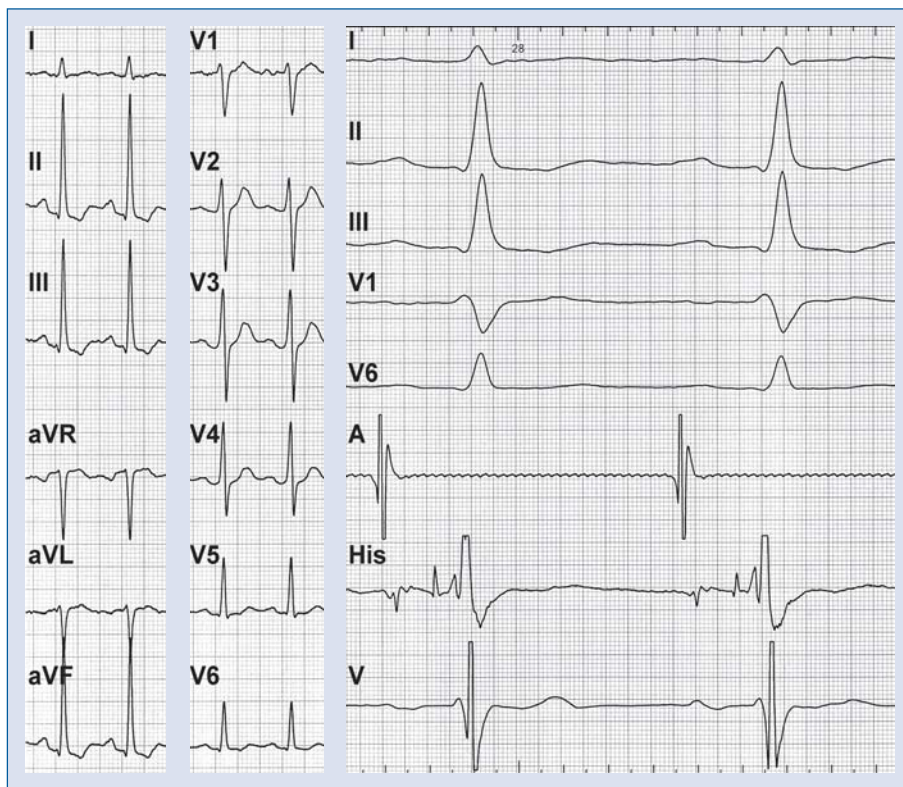
Fasciculoventricular bypass tracts are considered a very rare form of pre-excitation [4]. The true prevalence of these APs is probably underestimated because of usually minimal pre-excitation in the ECG and asymptomatic course [3]. Electrocardiographic characterization of fasciculoventricular APs is based on only a few published cases and case series [1, 2].

Signs of manifest pre-excitation in ECG can be subtle, depending on the location of the AP and the difference between conduction times through that AP and the atrioventricular node. In the present case, an apparent small septal q wave in V6 could argue against pre-excitation [4]. However, as

indicated by Bogun et al. [4], a tiny delta wave producing an rsR' pattern with a very small r wave can lead to the erroneous conclusion that a q wave in V6 is present. Careful QRS examination in the V6 suggested that our case was such an example. Therefore, the present ECG, despite only small initial QRS slurring and borderline PR interval, indeed indicates the presence of subtle pre-excitation. In the era of interventional treatment of arrhythmias, it is important to differentiate pre-excitation pattern due to fasciculoventricular AP and superoparaseptal AP. In both situations, the ECG picture might be similar and an erroneous assumption that a superoparaseptal AP is present might lead to an unnecessary and risky ablation attempt close to the AV node and His bundle. The ECG picture in the present patient was more compatible with the diagnosis of fasciculoventricular AP, since, unlike superoparaseptal atrioventricular APs, fasciculoventricular APs often characterize a QRS of no more than 120 ms and an R wave duration in V1 of less than 35 ms [1, 2].

Another important observation suggestive of fasciculoventricular AP is the presence of minimal and constant degree of pre-excitation despite different PR intervals and despite different heart rates. However, a final diagnosis can be made only during electrophysiological study with observation of a short and constant HV interval despite decremental AV conduction with prolongation of the AH interval or atrioventricular block or observation of an unchanged pre-excitation pattern during His bundle extrasystole [5].

If the refractory period of a fasciculoventricular AP is longer than the AV node refractory period (and also the His bundle refractory period), then properly timed premature atrial depolarization can block in the fasciculoventricular AP with immediate QRS normalization and HV interval prolongation, thus showing the impact of the fasciculoventricular fiber on the ECG picture. However, this could not be achieved in our case despite several attempts, probably due to the short refractory period of the AP. Selective blocking of the fasciculoventricular fiber with normalization of QRS morphology can also be achieved by administration of a class IA antiarrhythmic drug [6]. Therefore, for diagnostic purposes, 50 mg ajmalin was administered intravenously. Within minutes, this resulted in PR prolongation, HV normalization, disappearance of the delta wave, increased R wave amplitude in V1 and the appearance of a septal Q wave in V6 (Fig. 3). These effects were similar to those described by Ito et al. [6], and were considered final confirma-



**Figure 3.** Findings five minutes after intravenous ajmaline administration. A 12-lead electrocardiogram and intracardiac electrograms showing PR prolongation, HV normalization, disappearance of the delta wave, increase in amplitude of the R wave in V1 and appearance of a septal Q wave in V6, as compared to the data shown in Figure 1.

tion that a fasciculoventricular AP was indeed responsible for the minimal, constant pre-excitation pattern in the ECG of our patient.

However, these rare APs are considered a misleading electrocardiographical curiosity rather than a substrate for arrhythmias. Specifically, it is impossible for these APs to cause fast ventricular response during atrial fibrillation and syncope because the fasciculoventricular AP takes off below the AV node, from the His-Purkinje system. Moreover, fasciculoventricular bypass tracts were never proved to be a substrate for re-entrant arrhythmias, probably because of the close proximity to the native conduction system that precludes conduction delay necessary for establishment of re-entry. Consequently, the pre-excitation in our case, although present, was unrelated to the patient’s symptoms. However, coexistence of a bystander fasciculoventricular pathway with other accessory pathways or different arrhythmias, like atrioventricular nodal reentrant tachycardia or atrial tachycardia or even symptoms suggestive of arrhythmias, might be very misleading.

In conclusion, a fasciculoventricular AP may mimic an atrioventricular AP pre-excitation pattern,

and this can lead to diagnostic and therapeutic dilemmas in the context of heart palpitations and/or syncope. The current case shows the classic electrocardiographical and electrophysiological features of this rare AP variant.

### Limitations of the study

In the current case despite exclusion of manifest atrioventricular accessory pathway and firm diagnosis of fasciculoventricular pathway, exclusion of a concomitant, concealed septal accessory pathway was based only on single observation that early premature ventricular depolarization during tachycardia did not advance next atrial depolarization; parahisian pacing was not performed and other diagnostic maneuvers were not feasible due to prompt spontaneous termination of the tachycardia. Moreover, it was not possible to completely exclude relationship between the induced tachycardia and syncopal episodes. Nevertheless, the non-sustained tachycardia that was induced during high-dose isoprenaline infusion was well tolerated and was likely a non-clinical arrhythmia, further clinical course of the patient seems to support that.

## Acknowledgements

The authors do not report any conflict of interest regarding this work.

## References

1. Oh S, Choi YS, Choi EK et al. Electrocardiographic characteristics of fasciculoventricular pathways. *Pacing Clin Electrophysiol*, 2005; 28: 25–28.
2. Sternick EB, Rodriguez LM, Gerken LM, Wellens HJ. Electrocardiogram in patients with fasciculoventricular pathways: A comparative study with anteroseptal and midseptal accessory pathways. *Heart Rhythm*, 2005; 2: 1–6.
3. Josephson ME. Preexcitation syndromes. In: Josephson ME ed. *Clinical cardiac electrophysiology*. Lippincott Williams & Wilkins, Philadelphia 2008.
4. Bogun F, Kalusche D, Li YG, Auth-Eisernitz S, Gronefeld G, Hohnloser SH. Septal Q waves in surface electrocardiographic lead V6 exclude minimal ventricular preexcitation. *Am J Cardiol*, 1999; 84: 101–104.
5. Tung R, Sklyar E, Josephson M. An unusual form of preexcitation: Fasciculoventricular bypass tract. *Heart Rhythm*, 2008; 5: 1767–1768.
6. Ito M, Onodera S, Noshiro H et al. Effect of class Ia antiarrhythmic agents on fasciculoventricular fibers. *J Electrocardiol*, 1990; 23: 323–329.