

Idiopathic intrafascicular reentrant left ventricular tachycardia in an elite cyclist athlete

Andrés Ricardo Pérez Riera¹, Ricardo Gitti Ragoonete¹, Celso Ferreira Filho¹,
Marcelo Ferreira¹, Edgardo Schapachnik², Sergio Dubner³, Celso Ferreira¹,
Agnieszka Mochon⁴, Li Zhang⁴

¹For International VCG Investigators; Electro-Vectorcardiographic Section, ABC Faculty of Medicine (FMABC), Foundation of ABC (FUABC), Santo André, São Paulo, Brazil

²Dr. Cosme Argerich Hospital, Buenos Aires, Argentina

³Clínica and Maternidad Suizo Argentina, Buenos Aires, Argentina

⁴For Main Line Health Heart Center and Lankenau Hospital, Wynnewood, PA, USA

Abstract

A 32 year-old Caucasian male, an elite athlete, was admitted to the emergency department because of a sudden onset of palpitations which had lasted more than 12 hours and were associated with chest discomfort. He had a two-year history of recurrent stress-induced palpitations. He denied either episodes of syncope or any family history of sudden death. Physical examination was normal. He had no evidence of structural heart disease. The electrocardiography (ECG) documented during the event supported the diagnosis of idiopathic reentrant left ventricular tachycardia. Ventricular tachycardia ablation was successful. This case demonstrates that a careful physical examination and correct ECG diagnosis can lead to an appropriate arrhythmia management. (Cardiol J 2009; 16, 6: 564–567)

Key words: idiopathic left ventricular tachycardia, athlete's heart apparent structural normal heart

Case report

Identification

A 32 year-old Caucasian Brazilian male, elite athlete (cyclist) in ectomorph biotype.

Complaint and duration

Regular heart palpitations, associated with atypical chest pain, began two days prior to the visit to the emergency department. Our patient complained of recurrent rapid palpitations triggered by exertion (walking short distances or climbing stairs), associated with dizziness and diffuse chest discomfort, described as “burning” with moderate

intensity, without radiation. He denied nausea, vomiting or diaphoresis. The symptoms were intermittent; they stopped for hours and always re-occurred with exertion. At the beginning, the palpitations lasted from 30 minutes to one hour. But at the time of presentation in the emergency room, they had already lasted for 12 hours without interruption.

Our patient reported that progressive symptoms of palpitations started two years ago. They occurred always after training and lasted for around 20 minutes. The symptoms were always less intense than the current ones. He denied syncope, dizziness, or any symptom of low output during these episodes.

Address for correspondence: Andrés Ricardo Pérez Riera, MD, Rua Sebastião Afonso, 885-Jd. Miriam 04417-100, Sao Paulo, Brazil, tel: +55 11 5621-2390, fax: +55 11 5625 7278/5506 0398, e-mail: riera@uol.com.br

Received: 7.02.2009

Accepted: 11.02.2009

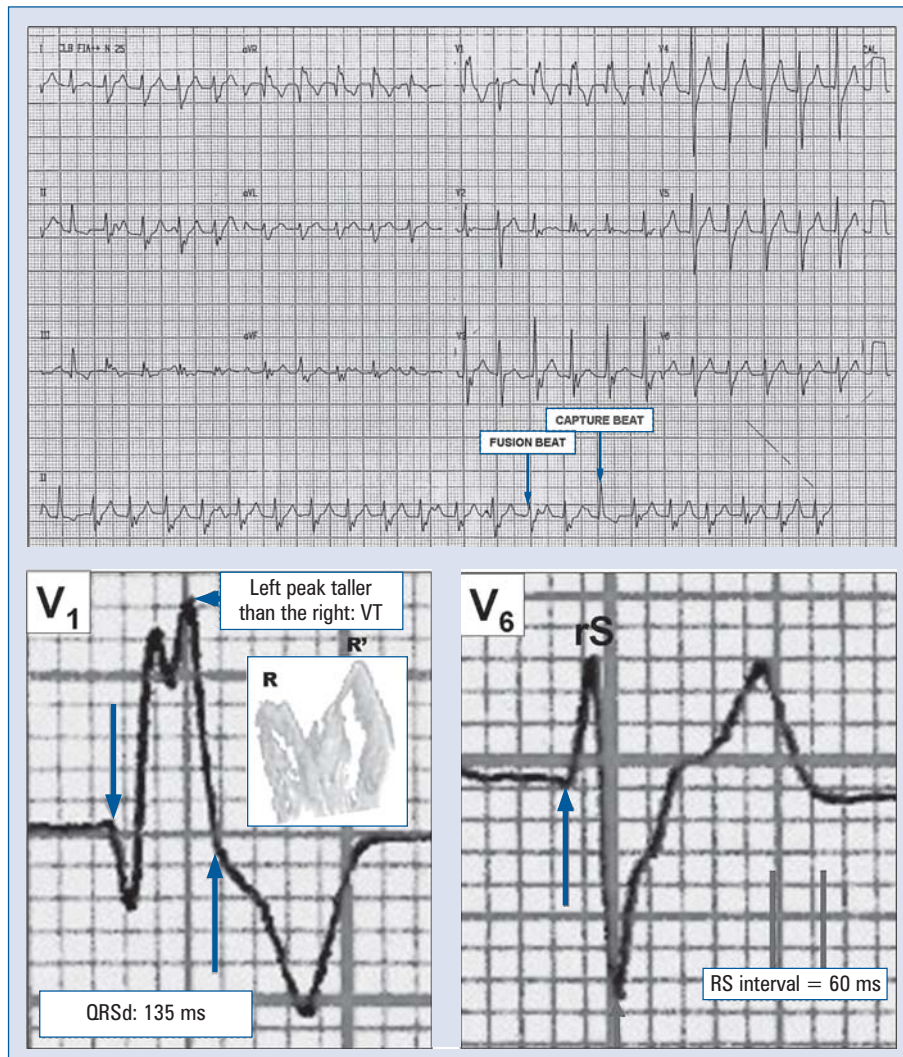


Figure 1. Electrocardiography recorded during palpitations showing following features: the ectopic beats showing right bundle branch block pattern with QRS axis shifted to right and extreme left axis deviation; rS pattern is shown in leads I, and aVL and qR in lead III, indicating intrafascicular re-entrant left ventricular tachycardia re-entry was facilitated via left anterior fascicle; the QRS is relatively narrow or borderline-broad (between 120 ms and 140 ms) with RS interval (from the beginning of R wave until the nadir of S wave) < 80 ms in all precordial leads. In V1 biphasic pattern (qR) and notched R wave showing left R peak (second) taller than the right one (first): the ‘rabbit ear clue’ sign in V1 [4], and RS ratio < 1 in V6.

Personal history: Competitive athlete, cyclist, covering on average 400 km per week; training from three to four hours per day. He denies any cardiovascular risk factor.

Family history: Noncontributory.

Physical examination: Blood pressure 110/70 mm Hg, heart rate 150 bpm, respiratory rate 26 rpm, jugular venous pulse presents with irregular cannon “a” waves and absence of stasis.

Pulmonary system: Lungs clear to auscultation bilaterally.

Cardiovascular system: The ictus cordis was palpable at the fifth left intercostal space, on mid-clavicular line. The first heart sound displayed a varying intensity. The second sound was normal. No murmurs.

Abdomen: Soft, non-tender, non-distended. Bowel sounds present. No hepatosplenomegaly.

Limbs: Pulses present on all four extremities, good peripheral perfusion, without edema.

The electrocardiography (ECG) recorded during an episode of palpitation is shown in Figures 1–3.

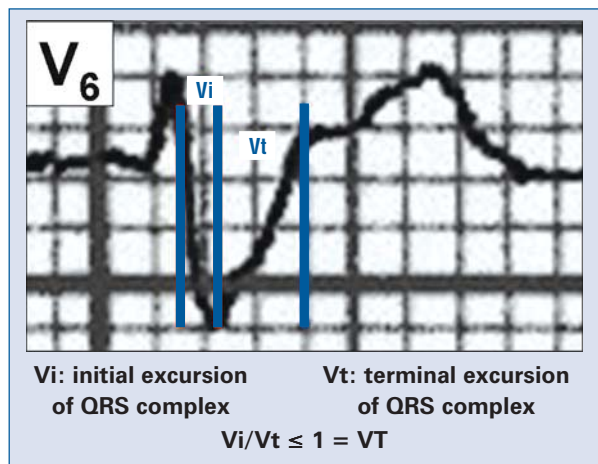


Figure 2. Initial excursion of negative QRS complexes (Vi)/terminal excursion of QRS complexes (Vt) < 1 (Vi/Vt < 1) [5].

Transthoracic echocardiogram and cineventriculography were normal. The ventricular repolarization abnormalities, shown in the ECG immediately

after the event (Fig. 4), and the complaints of chest pain, led to a cineangiography.

Electrophysiology study

Programmed ventricular stimulation (PVS)

During PVS, there was induction of tachycardia of wide QRS, right bundle branch block (RBBB) pattern, with upward axis of 420 ms. Absence of ventricle-atrial conduction.

Percutaneous radiofrequency catheter ablation (PRCA)

Left ventricular mapping looking for the earliest ectopy in relation to QRS. PRCA was conducted with thermo-controlled applications (60°C, 30 s) in the middle septal region of the anterior wall. After waiting for 30 minutes, there was no recurrence of arrhythmia, even after PVS with up to three extra-stimuli and on isoproterenol infusion.

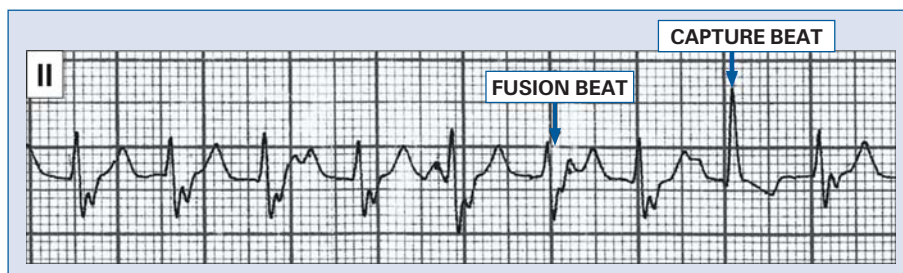


Figure 3. Capture and fusion beats are observed (atrioventricular dissociation). Conclusion: idiopathic intrafascicular re-entrant left ventricular tachycardia.

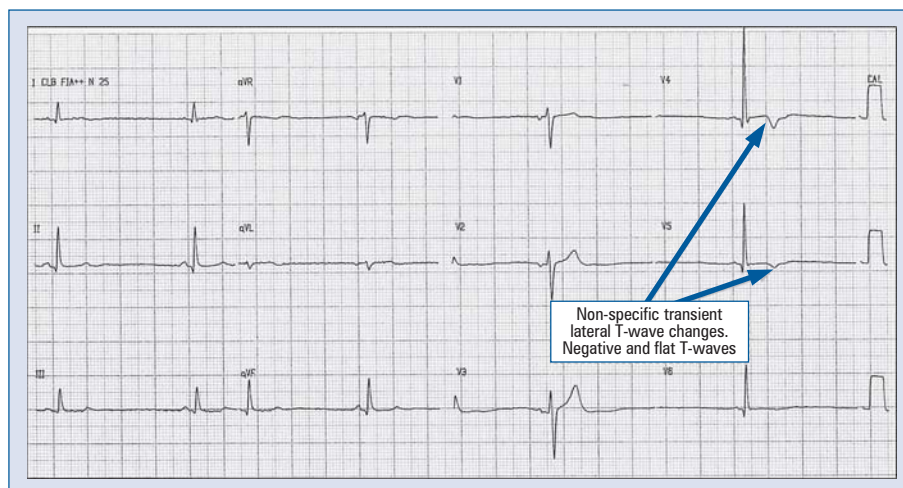


Figure 4. A resting electrocardiography recorded immediately after ventricular tachycardia event showing typical features of athletic heart: increased QRS amplitude in V4–V5 associated with asymmetric T wave inversion. The T wave amplitude is low in inferior limb leads.

Discussion

Idiopathic intrafascicular reentrant left ventricular tachycardia (ILVT) or verapamil-sensitive ventricular tachycardia [1] is the second most common form of idiopathic VT. ILVT is usually seen in young males without apparent structural heart disease, featuring paroxysmal palpitations and RBBB morphology. QRS axis shifting depends on the fascicle involved. Characteristically, extreme left axis deviation is seen in left anterior fascicular tachycardia, whereas left axis (-45 to -60) deviation is noted with left posterior fascicular tachycardia. Zipes et al. [2] described a triad characteristic for ILVT: induction with atrial pacing, RBBB pattern with extreme left axis deviation, and no structural heart disease.

Idiopathic ventricular tachycardia (VT) encloses a heterogeneous group of tachycardias that may result from multiple cellular electrophysiological mechanisms [3]. It is characterized by two predominant forms. The most common form originates from the right ventricular outflow tract and presents as repetitive monomorphic VT or exercise-induced VT. The tachycardia is adenosine-sensitive and is thought to be caused by cAMP-mediated triggered activity. The other major form seen in this case is verapamil-sensitive intrafascicular re-entrant tachycardia, which most often originates in the region

of the left posterior fascicle. Both forms of idiopathic VT can be readily treated with PRCA.

Conclusions

Recognizing ILVT and its unique characteristics can lead to a correct diagnosis and facilitate appropriate therapy.

Acknowledgements

The authors do not report any conflict of interest regarding this work.

References

1. Belhassen B, Rotmensch HH, Laniado S. Response of recurrent sustained ventricular tachycardia to verapamil. *Br Heart J*, 1981; 46: 679–682.
2. Zipes DP, Foster PR, Troup PJ et al. Atrial induction of ventricular tachycardia: reentry versus triggered automaticity. *Am J Cardiol*, 1979; 44: 1–8.
3. Griffith MJ, Garratt CJ, Rowland E et al. tachycardia. Effects of intravenous adenosine on verapamil-sensitive “idiopathic” ventricular. *Am J Cardiol*, 1994; 73: 759–764.
4. Gozensky C, Thorne D. Rabbit ears: An aid in distinguishing ventricular ectopy from aberration. *Heart Lung*, 1974; 3: 634–636.
5. Vereckeai A, Duray G, Szénási G et al. New algorithm using only lead aVR for differential diagnosis of wide QRS complex tachycardia. *Heart Rhythm*, 2008; 5: 89–98.