

Synergistic effects of cardiac resynchronization therapy and Bachmann's bundle pacing on heart failure with atrial tachyarrhythmias

Chikaya Omichi, Atsushi Kawasaki, Atsunobu Kasai

Cardiovascular Center, Division of Cardiology, Kitahara Hospital, Tokyo, Japan

Abstract

Cardiac resynchronization therapy (CRT) is electrical resynchronization of the ventricles. Bachmann's bundle (BB) pacing is considered to be electrical resynchronization of the atria. Atrial fibrillation (AF) and congestive heart failure (HF) often coexist in the same patient. A 69 year-old man who underwent CRT combined with BB pacing for HF and atrial tachycardias or atrial fibrillation (AF) improved HF symptoms. The combined therapy reduced the number of admissions and occurrence of atrial tachyarrhythmias. It is possible that CRT combined with BB pacing could provide synergistic, beneficial effects on symptoms in patients with HF and AF and hence break a vicious circle. (Cardiol J 2009; 16, 4: 358–361)

Key words: cardiac resynchronization therapy, Bachmann's bundle pacing, atrial fibrillation, heart failure

Introduction

Cardiac resynchronization therapy (CRT) is electrical resynchronization of the ventricles. Bachmann's bundle (BB) pacing is considered to be electrical resynchronization of the atria. The synergistic effects of CRT and BB pacing have yet to be determined in patients with atrial tachyarrhythmias and heart failure (HF).

Case report

A 69 year-old man was admitted with dyspnea on exertion and palpitations. He underwent aortic valve replacement for aortic regurgitation due to rheumatic fever at the age of 32 and was re-operated upon at the age of 57. Body surface electrocardiography demonstrated left bundle branch block, a superior QRS axis and prolonged QRS duration, 200ms during sinus rhythm (Fig. 1A). Echocardi-

graphy revealed left ventricular (LV) dilatation, 62 mm, and dyssynchrony with a low LV ejection fraction, 0.34 and mild mitral valve regurgitation. He was admitted several times to treat congestive HF and atrial tachycardias. He underwent catheter ablation for refractory atrial tachycardias. Two different re-entrant atrial tachycardias were induced by programmed atrial extra-stimuli. The atrial tachycardias were terminated by catheter ablation of cavo-tricuspid isthmus and point-by-point ablation with an entrainment mapping technique.

He experienced a recurrence of HF with paroxysmal atrial fibrillation (AF) several months after the ablation of atrial tachycardias. His symptoms increased to NYHA class IV and quality of life deteriorated despite optimized medical therapy including loop diuretics, spironolactone, digoxin, beta-blocker, angiotensin receptor blocker and administration of intravenous inotropic agents. He needed lengthy hospitalization with the increased symptoms.

Address for correspondence: Chikaya Omichi, MD, PhD, Division of Cardiology, Cardiovascular Center, Kitahara Hospital, 1-7-23 Owada-cho, Hachioji, Tokyo, 192-0045, Japan, tel: 81 42 645 1110, fax: 81 42 645 1140, e-mail: omichi@kitaharahosp.com

Received: 9.09.2008

Accepted: 24.11.2008

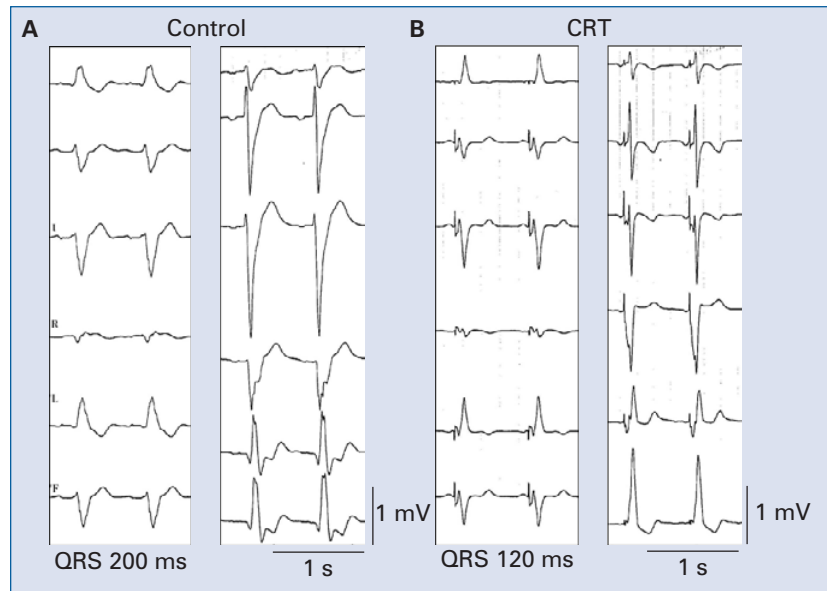


Figure 1. 12-lead electrocardiography demonstrates the QRS width before (A) and after (B) cardiac resynchronization therapy (CRT) pacemaker implantation. QRS width has shortened from 200 to 120 ms.

Hemodynamic data revealed pulmonary capillary wedge pressure was 29 mm Hg and pulmonary artery pressure 50/20 mm Hg. Echocardiography showed further deterioration of LV ejection fraction. He qualified for implantation of CRT for HF. The target site for the left ventricular pacing lead was a postero-lateral tributary of the coronary sinus. The coronary sinus lead was connected to a CRT pacemaker (InSync model 8040, Medtronic Inc, Minneapolis, MN, USA). The patient received the bipolar atrial screw-in pacing lead in Bachmann's bundle region, atrial septal site and a standard right ventricular pacing lead. The CRT pacemaker was programmed in biventricular DDD mode with a lower rate of 70 beats/min and atrio-ventricular delay was 150 ms. electrocardiography revealed a shortened QRS width of 120 ms after the initiation of CRT (Fig. 1B). P wave duration also decreased when atrial pacing was performed, compared with the control. Clinical improvement was observed from NYHA class IV to NYHA class II within two weeks (Fig. 2). Chest X-ray showed an improvement of congestive HF (Fig. 3). The serum brain natriuretic peptide level decreased from over 400 to less than 250 pg/mL two months after the CRT implantation (Fig. 2). No paroxysmal AF or atrial tachyarrhythmias occurred after the combined CRT and BB pacing (Fig. 2). Thus, no more inotropic agents were needed and he was discharged after cardiac rehabilitation. He has been followed up for one year without an admission for HF or tachyarrhythmias.

Ambulatory pacemaker monitoring during follow-up disclosed no incidence of AF or atrial tachyarrhythmias except for asymptomatic episodes of atrial ectopic beats.

Discussion

In our case study, the CRT and BB pacing significantly improved symptoms of severe HF and prevented atrial tachyarrhythmias and paroxysmal AF. The combined therapies could enhance each pacing effect on improving symptoms of HF and preventing atrial tachyarrhythmias.

CRT is an effective adjunctive therapy for the treatment of symptomatic moderate and severe HF [1]. CRT not only increases the likelihood of clinical improvement, but also reduces the risk of clinical deterioration during the course of follow-up. AF and CHF often co-exist in the same patient and constitute a vicious circle in which CHF promotes AF and AF aggravates CHF. However, a CRT device is less effective in terms of the suppression of atrial tachyarrhythmias or AF. Padeletti et al. [2] first examined whether AF suppression algorithm to CRT improved the prognosis of patients. They suggested that CRT combined with a refined pacing algorithm represented a major advance in the management of AF and CHF by electrical stimulation. Fung et al. [3] reported that patients with CRT had a significantly lower incidence of AF than controls. Other reports have on the contrary shown that

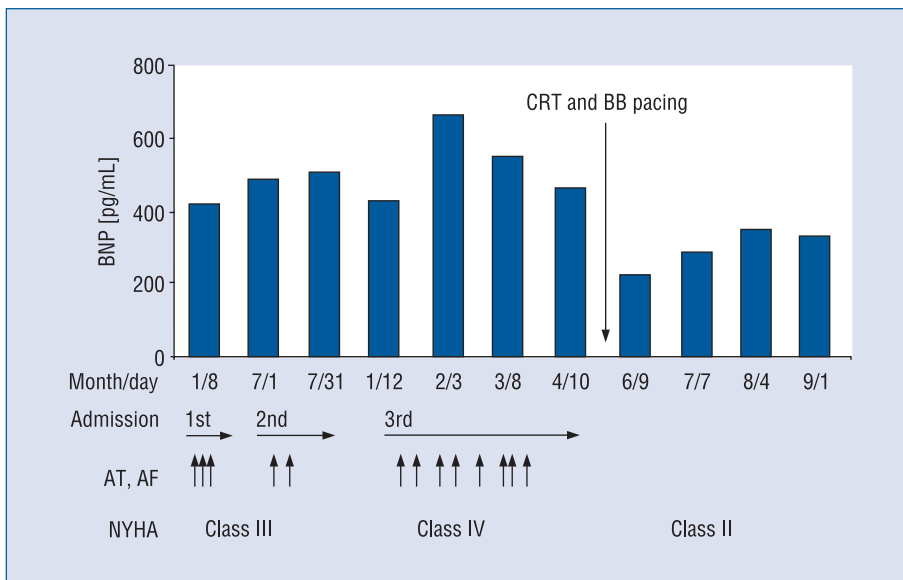


Figure 2. Serum brain natriuretic peptide (BNP) level during clinical course and duration of admission, occurrence of paroxysmal atrial fibrillation (AF), atrial tachycardias (AT) and NYHA class before and after cardiac resynchronization therapy (CRT) combined with Bachmann’s bundle (BB) pacing implantation. The BNP decreased after CRT implantation and symptoms improved without paroxysmal AF and AT.

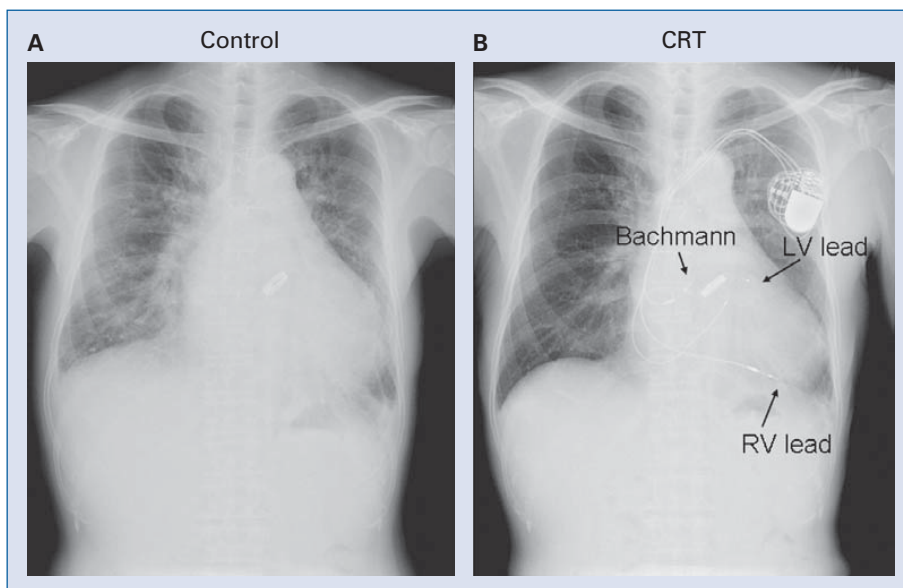


Figure 3. Chest X-ray shows an improvement of congestive heart failure before (A) and after (B) cardiac resynchronization therapy and Bachmann’s bundle pacing implantation; RV — right ventricle, LV — left ventricle.

CRT did not influence the incidence of AF [4, 5]. Atrioventricular (A-V) junction ablation and pacing are commonly performed in CRT candidates with chronic AF. As for paroxysmal AF, effective pacing algorithm and pacing site should be introduced as a therapeutic option.

Studies had reported that BB pacing could prevent paroxysmal AF [6, 7]. The prevention of AF could be associated with BB pacing which causes a shorter total atrial activation time and less interatrial conduction delay. Furthermore, atrial septal pacing decreases dispersion of refractoriness,

which may be preferable in patients with paroxysmal AF.

CRT provides proper detection of atrial signals and reliable atrial pacing when effective A-V synchronous pacing is feasible. In addition to the A-V and V-V synchronicity of CRT, BB pacing could lead to an appropriate A-A synchronicity and represent a significant advance in the management of AF and severe HF patients.

In conclusion, the CRT combined with BB pacing has improved symptoms of HF and reduced number of admissions and occurrence of atrial tachyarrhythmias. It is possible that CRT combined with BB pacing could provide synergistic, beneficial effects on symptoms in patients with HF and AF, thus breaking the vicious circle.

Acknowledgements

The authors do not report any conflict of interest regarding this work.

References

1. Abraham WT, Fisher WG, Smith AL et al. MIRACLE Study Group. Multicenter InSync Randomized Clinical Evaluation. Cardiac resynchronization in chronic heart failure. *N Engl J Med*, 2002; 346: 1845–1853.
2. Padeletti L, Musilli N, Porciani MC et al. Atrial fibrillation and cardiac resynchronization therapy: The MASCOT study. *Europace*, 2004; 5 (suppl. 1): S49–S54.
3. Fung JW, Yu CM, Chan JY, Chan HC, Yip GW, Zhang Q, Sanderson JE. Effects of cardiac resynchronization therapy on incidence of atrial fibrillation in patients with poor left ventricular systolic function. *Am J Cardiol*, 2005; 96: 728–731.
4. Hoppe UC, Casares JM, Eiskjaer H, Hagemann A, Cleland JG, Freemantle N, Erdmann E. Effect of cardiac resynchronization on the incidence of atrial fibrillation in patients with severe heart failure. *Circulation*, 2006; 114: 18–25.
5. Saxon LA. Does cardiac resynchronization therapy reduce the incidence of atrial fibrillation, and does atrial fibrillation compromise the cardiac resynchronization therapy effect? *Heart Rhythm*, 2007; 4 (3 suppl.): S31–S33.
6. Khaja A, Flaker G. Bachmann's bundle: does it play a role in atrial fibrillation? *Pacing Clin Electrophysiol*, 2005; 28: 855–863.
7. Bailin SJ, Adler S, Giudici M. Prevention of chronic atrial fibrillation by pacing in the region of Bachmann's bundle: Results of a multicenter randomized trial. *J Cardiovasc Electrophysiol*, 2001; 12: 912–917.