

# Myocardial infarction after an electric shock: A rare complication

Aksuyek Celebi<sup>1</sup>, Okan Gulel<sup>2</sup>, Hulya Cicekcioglu<sup>1</sup>, Serkan Gokaslan<sup>1</sup>,  
Gurkan Kututcularoglu<sup>1</sup>, Vasfi Ulusoy<sup>1</sup>

<sup>1</sup>Numune Education and Research Hospital Cardiology, Ankara, Turkey

<sup>2</sup>19 Mayıs University Cardiology Samsun, Turkey

## Abstract

*Myocardial infarction is one potential outcome after an electric shock though it is seen relatively rarely. Nonetheless, an increased death rate because of cardiopulmonary arrest is of concern and merits careful scrutiny. Here, we report a man with myocardial infarction following electrical shock. Although he had frankly normal coronary arteries by coronary angiography, myocardial infarction was objectively evident by cardiac enzymes, electrocardiography and echocardiography. Oral medication with a beta-blocker and angiotensin converting enzyme inhibitor was started. He was discharged in good health after stabilization for a co-existing pelvic fracture and retroperitoneal hematoma. The patient had an uneventful follow-up one year later, with persisting non-specific electrocardiographic changes. (Cardiol J 2009; 16, 4: 362–364)*

**Key words:** electrical shock, myocardial infarction, electrocardiography

## Introduction

Electrical shock usually leads to multiple injury and death. It affects the cardiovascular system in nearly one third of patients. The primary cause of death from electrical shock is cardiopulmonary arrest [1]. Myocardial infarction is a potential, though rare, consequence of electric shock.

## Case report

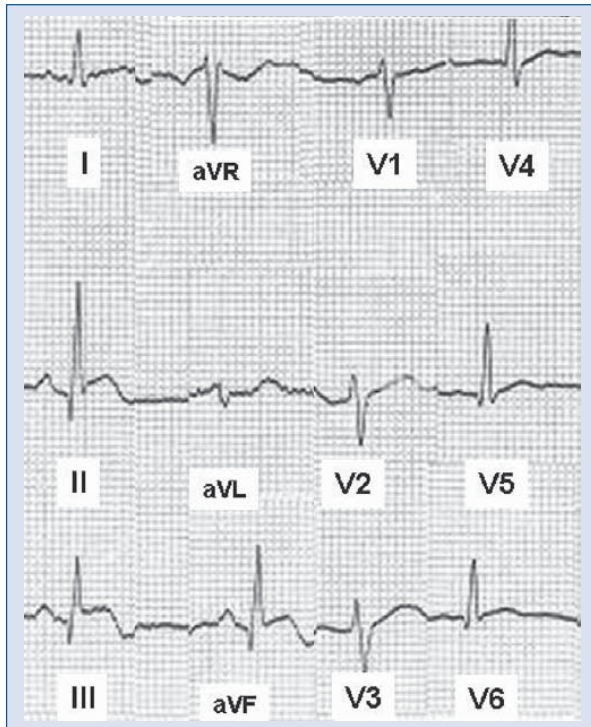
A 25 year-old man suffering from chest pain was admitted to our emergency department following accidental contact with an electricity power line at a lamp-post. After the shock, he had fallen to the ground. There were no pre-existing medical problems. At admission, blood pressure and heart rate were 125/87 mm Hg and 95 beats per minute respectively. Cardiovascular examination was unremarkable. There were macerated burns on the anterior side of his body, extending from inguinal

region to subclavicular region bilaterally. Electrocardiography (ECG) revealed sinus rhythm with > 1 mm ST segment elevation and biphasic T waves in inferior leads, suggesting evolving inferior myocardial infarction (Fig. 1). Transthoracic echocardiography (TTE) demonstrated normal global systolic function (ejection fraction = 59%) and hypokinesia of the left ventricular inferior wall. Serum creatine kinase (CK), CK-MB and troponin I levels were markedly high [7150 U/L (25–200 U/L), > 400 U/L (0–25 U/L), 24 ng/mL (< 1.5 ng/mL) respectively]. Abdominal computed tomography showed a pelvic fracture and retroperitoneal hematoma. After stabilization, he underwent coronary angiography. Both left and right coronary arteries were free of any occlusive lesions. However, left ventriculography complied with ECG findings in detecting hypokinesia of the inferior wall. Beta-blocker and angiotensin converting enzyme inhibitor therapies were started. He was discharged from hospital uneventfully after treatment for electrical burns, pelvic fracture

**Address for correspondence:** Aksuyek Savas Celebi, Numune Education and Research Hospital Cardiology, Ankara, Turkey, tel: +90 505 625 1453, fax: +90 312 3110 115, e-mail: savascelebi@yahoo.com

Received: 13.08.2008

Accepted: 23.10.2008



**Figure 1.** Admission electrocardiography, showing ST elevation of inferior derivations.

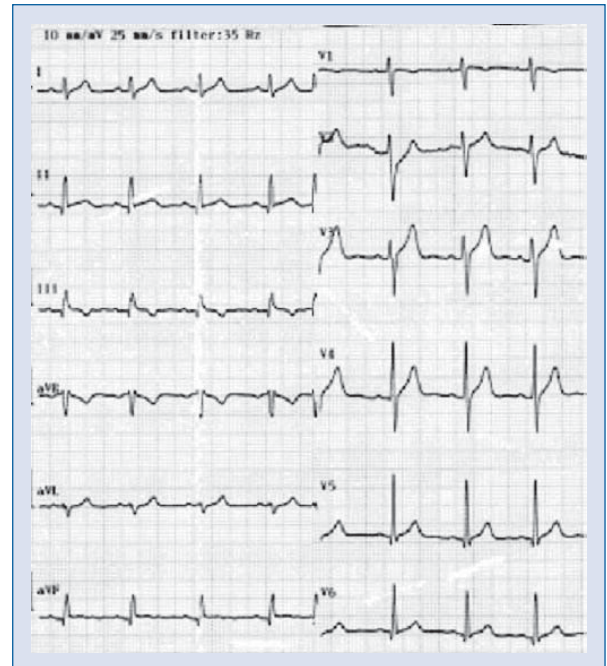
and retroperitoneal hematoma. After one year, ECG showed minimal ST segment elevation ( $< 1$  mm) in inferior leads, T wave inversion in lead III and flattening of T wave in lead aVF (Fig. 2). There was no sequel of myocardial injury and systolic function was normal by TTE.

### Discussion

Electrically injured patients typically are young and male [2], and electrical injury to adults mostly occurs in an occupational setting [3]. Widespread and conflicting data is available in terms of myocardial injury after an electric shock.

Despite the controversy, some mechanisms have been proposed to account for myocardial injury after electrical shock. These are: coronary artery spasm [4]; direct thrombogenic effect on coronary arteries [5]; direct thermal effect on myocardium [4]; ischemia secondary to arrhythmia-induced hypotension [6]; coronary artery ischemia as part of a generalized vascular injury [7]; and direct contusion during cardiopulmonary resuscitation with subsequent coronary artery injury [8]. Also, hypoxic condition after respiratory arrest might possibly contribute to myocardial injury [9].

In one report, abnormal ECG was detected in approximately 31% of patients following an electric



**Figure 2.** Electrocardiography one year later.

shock [10]. Non-specific ST segment changes and sinus tachycardia are the most commonly reported ECG findings [11]. Other ECG findings include QT prolongation, bundle branch block, atrial and ventricular fibrillation, atrial and ventricular premature contractions [10, 11]. Given the non-transmural nature of necrosis, ST segment elevation rarely occurs due to electrical shock [12]. ST elevation of inferior derivations is, however, observed more often, as in our case. This seemingly higher predominance is explained by the right coronary artery's close proximity to the chest surface during its course, which makes it vulnerable to electrical shock [7]. These notable ECG changes can normalize and tend to be totally reversible in long-term survivors [10]. In contrast, the patient described herein had persistent ECG abnormalities, even after one year.

Both CK and CK-MB can markedly increase, owing to concomitant skeletal muscle injury and cardiopulmonary resuscitation. It is unclear to what extent skeletal muscle injury contributes to this increase. This can cause a spurious diagnosis of myocardial infarction after electrical shock. Therefore, CK and CK-MB are suggested to be less specific markers for myocardial injury [13]. The above-mentioned condition may have tarnished the value of CK and CK-MB in identifying myocardial infarction after electrical shock. Elevation of troponin I is more likely to increase in the event of myocar-

dial injury rather than skeletal muscle injury. Seen in this light, specific troponin I should unquestionably be the preferred cardiac enzyme.

Assessment of left ventricular systolic function after electrical shock is clinically relevant. Echocardiography can be beneficial in determining the presence of myocardial injury and its severity after electrical shock. It may reveal diffuse hypokinesia of myocardium, as well as regional hypokinesia. Echocardiographic findings may markedly improve in the follow-up [1, 14]. Additionally, echocardiography may provide confirmation of the induced myocardial injury, as happened in the present case.

In essence, coronary angiography is the first choice for the detection of the underlying mechanism of myocardial injury after electrical shock. Lesions are categorized as obstructive or non-obstructive. Demonstration of normal coronary arteries evokes non-obstructive mechanism. Coronary artery spasm [4], direct thermal effect on myocardium [4], ischemia secondary to arrhythmia-induced hypotension [6], direct contusion during cardiopulmonary resuscitation with subsequent coronary artery injury [8] and hypoxic condition after respiratory arrest [9], could all have contributed to myocardial injury in the current case. There was no history or evidence of cardiopulmonary resuscitation, hypoxic condition or arrhythmia-induced hypotension. Therefore, coronary artery spasm and direct thermal effect seemed the likeliest explanations for our case.

The optimal management of myocardial injury after electrical shock may be challenging since there is no consensus as to the best management of ST segment elevation myocardial infarction after electrical shock. Contraindications for fibrinolysis such as prolonged resuscitation, trauma or hematoma may unfortunately accompany electrical injury. So, coronary angiography with subsequent percutaneous coronary intervention may be better than fibrinolytic treatment as an initial reperfusion strategy. On the other hand, myocardial injury might occur due to a non-occlusive mechanism, as in the present case. So there may be no need for either medical or mechanical reperfusion. Thus, coronary angiography is of central importance and may clearly guide the therapy. Co-existing tachyarrhythmia can mostly be handled by anti-arrhythmic drugs [14]. Angiotensin converting enzyme inhibitors are as reliably effective as angiotensin II receptor blockers at protecting against remodeling [14]. Cardiac complications are managed similarly to other myocardial infarction causes and require follow-up evaluation [15].

In addition to these, patients should be managed in exactly the same way as following trauma.

## Conclusions

In conclusion, troponin I and echocardiography should be the primary considerations in order to detect myocardial injury after electrical shock. Despite the uncertainty of therapeutic options and lack of guidelines, coronary angiography can help determine whether myocardial injury is of occlusive or non-occlusive origin, thereby assisting towards a more tailored treatment. Considering the high incidence of cardiac complications, patients should ideally be observed closely during hospitalization and after discharge.

## Acknowledgements

The authors do not report any conflict of interest regarding this work.

## References

1. Homma S, Gillam LD, Weyman AE. Echocardiographic observations in survivors of acute electrical injury. *Chest*, 1990; 97: 103–105.
2. Purdue GF, Hunt JL. Electrocardiographic monitoring after electrical injury: Necessity or luxury. *J Trauma*, 1986; 26: 166–167.
3. Cooper MA. Electrical and lightning injuries. *Emerg Med Clin North Am*, 1984; 2: 489–501.
4. Xenopoulos N, Movahed A, Hudson P, Reeves WC. Myocardial injury in electrocution. *Am Heart J*, 1991; 122: 1481–1484.
5. Baubion N, Metzger JP, Heulin A, Grosdemouge A, De Vernejoul P, Vacheron A. Myocardial infarction caused by electric injury. Value of coronarography (in French). *Ann Med Interne (Paris)*, 1985; 136: 659–662.
6. Oltman CL, Clark CB, Kane NL et al. Coronary vascular dysfunction associated with direct current shock injury. *Basic Res Cardiol*, 2003; 98: 406–415.
7. James TN, Riddick L, Embry JH. Cardiac abnormalities demonstrated postmortem in four cases of accidental electrocution and their potential significance relative to nonfatal electrical injuries of the heart. *Am Heart J*, 1990; 120: 143–157.
8. Oliva PB, Breckinridge JC. Acute myocardial infarction with normal and near normal coronary arteries. Documentation with coronary arteriography within 12 1/2 hours of the onset of symptoms in two cases (three episodes). *Am J Cardiol*, 1977; 40: 1000–1007.
9. Koumbourlis AC. Electrical injuries. *Crit Care Med*, 2002; 30 (suppl. 11): S424–S430.
10. Housinger TA, Green L, Shahangian S, Saffle JR, Warden GD. A prospective study of myocardial damage in electrical injuries. *J Trauma*, 1985; 25: 122–124.
11. Carleton SC. Cardiac problems associated with electrical injury. *Cardiol Clin*, 1995; 13: 263–266.
12. Chandra NC, Siu CO, Munster AM. Clinical predictors of myocardial damage after high voltage electrical injury. *Crit Care Med*, 1990; 18: 293–297.
13. Hammond J, Ward CG. Myocardial damage and electrical injuries: Significance of early elevation of CPK-MB isoenzymes. *South Med J*, 1986; 79: 414–416.
14. McGill MP, Kamp TJ, Rahko PS. High-voltage injury resulting in permanent right heart dysfunction. *Chest*, 1999; 115: 586–587.
15. Kirchner JT Jr, Larson DL, Tyson KR. Cardiac rupture following electrical injury. *J Trauma*, 1977; 17: 389–391.