

Left ventricular diverticulum, a rare echocardiographic finding: Two adult patients and review of the literature

Tomás Francisco Cianciulli^{1*}, Patricia del Carmen Gonzalez Colaso²,
María Cristina Saccheri¹, Jorge A. Lax¹, Héctor J. Redruello¹,
Juan E. Guerra¹, Horacio Alberto Prezioso¹, Luis A. Vidal¹

¹Departments of Cardiology, Hospital del Gobierno de la Ciudad de Buenos Aires
“Dr. Cosme Argerich”, Buenos Aires, Argentina

²Hospital “Juan A. Fernández”, Buenos Aires, Argentina

*Researchers of the Secretary of Health, Government of the City of Buenos Aires, Argentina

Abstract

Congenital diverticulum of the left ventricle is a very rare cardiac abnormality characterized by a local embryological development failure of the ventricular muscle. It may present as an isolated disorder or may be associated with other cardiac abnormalities. Clinically, it has been reported that it can lead to chest pain, arrhythmias, cardiac rupture, and sudden death, although frequently the course is asymptomatic. This article presents two illustrative cases of left ventricular diverticulum. The diagnosis was made by two-dimensional echocardiography and was confirmed by cardiac catheterization. There were no other thoracoabdominal or cardiac abnormalities. The patient was asymptomatic and surgical resection was not indicated. Given the few cases reported in the medical literature, the information available is scarce; hence, physicians should be trained to make the appropriate diagnosis. (Cardiol J 2009; 16: 76–81)

Key words: two-dimensional echocardiography, congenital left ventricular diverticulum, cardiac catheterization

Introduction

Ventricular diverticula are a rare congenital disorder, with a prevalence ranging between 0.26% and 0.4%, and less than 100 cases reported in the English literature. Although it is often associated with other cardiac and non-cardiac congenital anomalies, it can also present alone, as an incidental finding in adult patients.

Given the few cases reported in the medical literature, the information available is scarce, and that hinders its detection with imaging diagnostic methods. Although extremely rare, cardiac diver-

ticula may be associated with high morbidity and mortality rates; hence, physicians should be trained to make the appropriate diagnosis.

In this report, we describe two cases of adult patients with an incidental diagnosis of isolated congenital left ventricular (LV) diverticulum.

Case 1

The patient was a 56-year-old woman, who presented with atypical effort-induced chest pain and palpitations. Her only risk factors were age and hypertension. Her blood pressure was 160/90 mm Hg

Address for correspondence: Tomás F. Cianciulli, MD, FACC, Hospital “Dr. Cosme Argerich”. Pi y Margall 750, Capital Federal (C11155AHB), Buenos Aires, Argentina, e-mail: tcianciulli@fibertel.com.ar

Received: 16.08.2008

Accepted: 26.10.2008

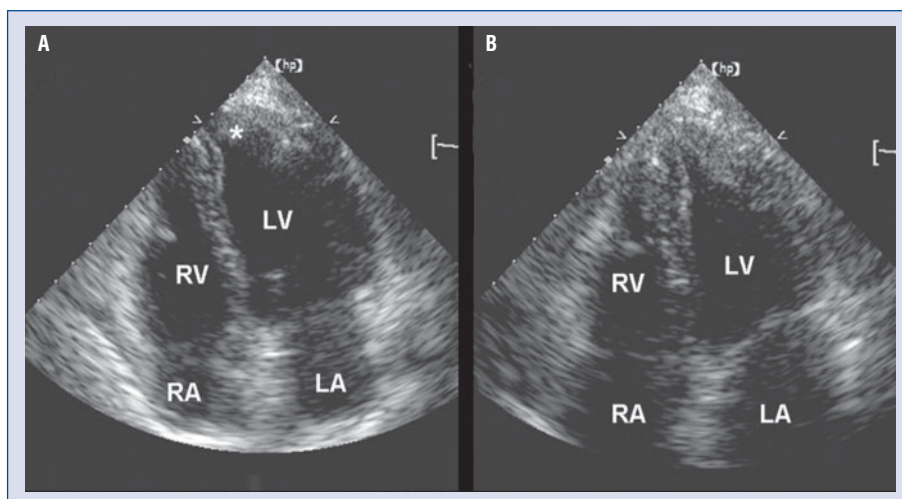


Figure 1. Two-dimensional transthoracic echocardiography. Apical four chamber view showing an apical left ventricular diverticulum (*) during diastole (A) and systole (B); LA — left atrium; RA — right atrium; LV — left ventricle; RV — right ventricle.

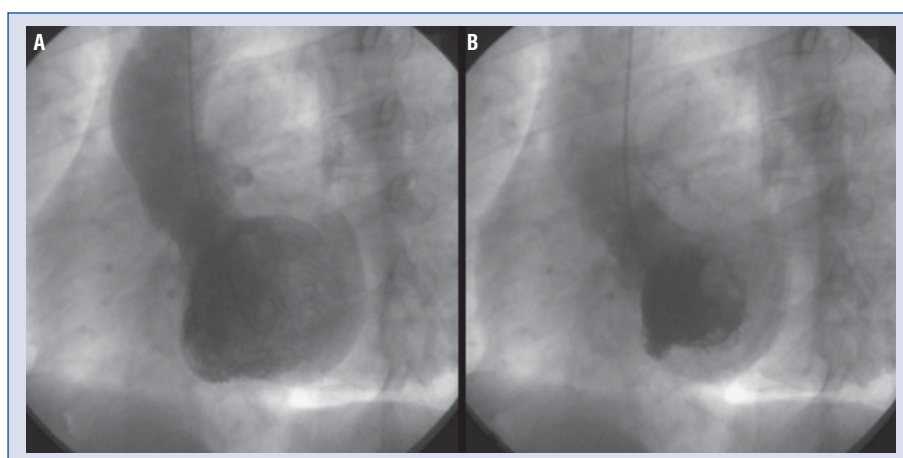


Figure 2. Left ventriculography in left anterior oblique view at end-diastole (A) and end-systole (B) illustrates the diverticulum originating from the apex of the left ventricle with contraction during systole.

and her pulse was regular at 50 beats/min. No heart murmur was detected and her lungs were clear. An abdominal examination was unremarkable and oedema was absent. No abnormal neurological findings were noted.

The 12-lead electrocardiogram (ECG) revealed sinus bradycardia (50 beats/min) and was not suggestive of ischemia, while the chest X-ray was normal.

The results of laboratory tests were unremarkable and Chagas serology was negative. The 24-hour Holter recording showed sinus rhythm and occasional supraventricular and ventricular arrhythmia.

On two-dimensional echocardiography (2-D echo), the right and left ventricles were normal in size and function. From the apical 4-chamber view, an accessory finger-shaped chamber with a narrow

neck (12 mm) was seen in the LV apex; contraction was synchronous with that of the LV (Fig. 1). This typical appearance on 2-D echo suggested the presence of a congenital ventricular diverticulum. The diverticular wall was similar in thickness and acoustic properties to the LV wall, and its contractility was so evident that neither contrast nor pulsed Doppler was needed to demonstrate contraction. The 2-D echo ruled out associated congenital disorders and was the best tool for patient diagnosis and follow-up.

The coronary angiography showed normal coronary anatomy. Left ventriculography ejection fraction was normal, and the left anterior oblique view revealed a contractile diverticulum in the apical wall of the LV (Fig. 2).

Maximal treadmill exercise testing was performed to investigate ischemia; however, neither ST depression nor angina was induced.

Given the absence of symptoms related to the ventricular diverticulum, watchful waiting was decided upon. The patient has currently been followed for 2 years and remains asymptomatic.

Case 2

A 22-year-old male patient was referred for cardiovascular monitoring to make competitive sports high performance. There were no coronary risk factors. His blood pressure was 120/80 mm Hg and he had a regular pulse of 60 beats/min. No heart murmur was detected and his lungs were clear. An abdominal examination was unremarkable. No abnormal neurological findings were noted, and the results of laboratory tests, chest X-ray, ECG, 24-hour Holter, and maximal treadmill exercise testing were unremarkable.

Two-D echocardiography revealed normal left ventricular function and internal diameters. From the apical 2-chamber view, an accessory bilobed tongue-like shaped chamber with a narrow neck (16 mm) was seen; contraction was synchronous with that of the LV (Fig. 3). The diverticular wall was similar in thickness and acoustic properties to the LV wall. Colour flow mapping showed a rapid diastolic filling. The 2-D echo ruled out associated congenital disorders. The transesophageal echocardiography did not give additional information.

The coronary angiography showed normal coronary anatomy. On left ventriculography ejection fraction was normal, and the right anterior oblique view revealed a bilobed contractile diverticulum at the inferior wall of the LV (Fig. 4).

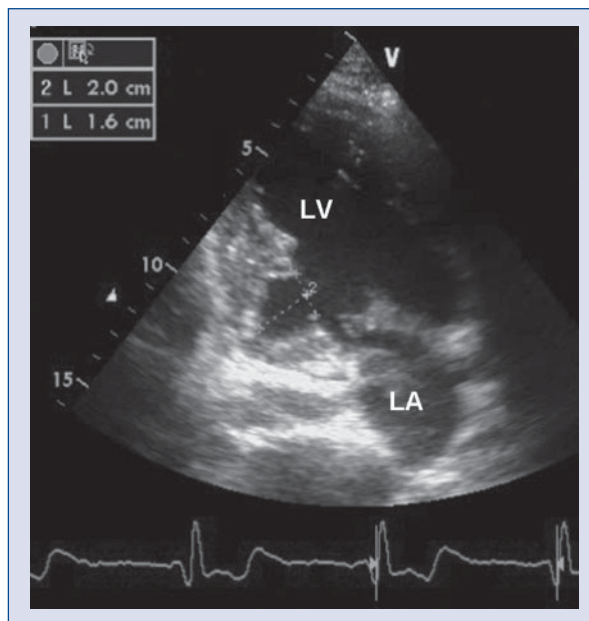


Figure 3. Two-dimensional transthoracic echocardiography. Apical two chamber view showing an inferobasal left ventricular diverticulum during diastole; LA — left atrium; LV — left ventricle.

Given the absence of symptoms related to the ventricular diverticulum, watchful waiting was decided upon. The patient has currently been followed for one year and remains asymptomatic.

Discussion

A congenital left ventricular diverticulum is a rare cardiac malformation consisting of a localized protrusion of endocardium and myocardium from the free wall of the LV. Possible etiologies of the left ventricular diverticulum include intrinsic

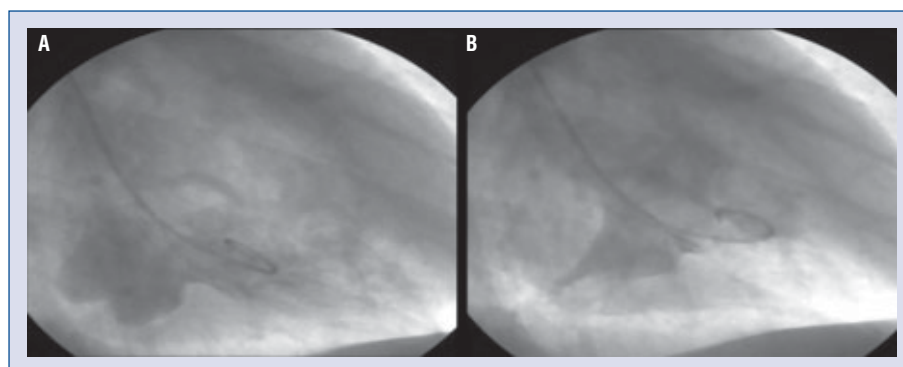


Figure 4. Left ventriculography in right anterior oblique view at end-diastole (A) and end-systole (B) illustrates the diverticulum originating from the inferior wall of the left ventricle with contraction during systole.

abnormalities during embryogenesis, such as maldevelopment of myocardial intraventricular sinusoids or acquired malformations *in utero*, including coronary artery abnormalities, viral infections, or arrhythmia-related vascular accidents [1], which may result in a localized weakness of the LV wall with gradual protrusion, due to the high intraventricular pressure.

A congenital ventricular diverticulum is a malformation with very low prevalence. In the adult population, it was reported to be about 0.4% in an autopsy series of patients with cardiac death [2], and about 0.26% in non-selected patients who underwent cardiac catheterization. It is more frequent in the left than in the right ventricle [3], but may be found in either of the two ventricles, and rarely [4] may even be multiple (diverticulosis).

When the ventricular diverticulum is associated with congenital anomalies of the thoracic and abdominal midline, with diaphragmatic and sternal defects and partial absence of the infero-apical pericardium, it is called syndrome or pentalogy of Cantrell [5]. Additionally, it may be associated to congenital cardiac abnormalities, such as ventricular septal defect, tetralogy of Fallot, or tricuspid atresia. In 30% of cases, it occurs as an isolated congenital anomaly, such as in this case report.

According to the pathology findings, they are classified in two types depending on their content: muscular or fibrous [6]. The fibrous congenital diverticulum is located in the base of the heart, near the subvalvular area and frequently causes aortic or mitral regurgitation, it has no contractile function and is not associated with other malformations. The muscular congenital diverticulum is typically located in the LV apex, has a narrow neck, includes all three cardiac layers, and is associated with other congenital cardiac disorders, particularly Cantrell's syndrome, but it is rarely found in asymptomatic adults as an isolated disorder with no associated malformations, as described in this report. Muscular diverticula may also involve the inferior or anterior walls of the LV.

When they present alone (with no associated malformations) the diagnosis is difficult because patients are usually asymptomatic [1], although they may present with systemic embolism, fatal ventricular arrhythmias, or sudden death due to rupture.

The ECG may show incomplete bundle branch blocks or non-specific ST-T changes [6].

The chest X-ray is usually normal, even in cases of large diverticula. The chest X-ray is helpful in the diagnosis of an apical congenital diverticulum when it shows dextrocardia or mesocardia, which is part of Cantrell's syndrome.

Two-D echocardiography is the diagnostic tool that allows accurate detection of congenital diverticula and assessment of their morphology, location, possible thrombosis and associated congenital cardiac disorders. A congenital muscular ventricular diverticulum appears on 2-D echo as a tongue-like or finger-shaped outpouching of the ventricle, which contains full-thickness myocardial wall with acoustic properties similar to the ventricular wall. A narrow neck and a finger-like contractile pouch are typical characteristics of the congenital muscular ventricular diverticulum [7]. Occasionally, the diverticulum is small and second harmonic echocardiography may be required for its adequate visualization.

Angiographic ventriculography offers another diagnostic option, but because of its invasive nature it is less useful than 2-D echo and is only used to confirm the diagnosis in patients with chest pain who require coronary angiography. For diverticula located in the LV apex (case 1), the 60° left anterior oblique view must be used. The 30° right anterior oblique projection identifies diverticula located in the inferior (case 2) or anterior wall of the LV. It is characterized by a narrow neck and normal contractility, resulting in rapid filling with contrast medium, which is completely ejected within two to four contractions. The coronary vessels supplying and coursing over the diverticulum are normal, with no evidence of stenosis or atheromatous disease.

Cardiovascular magnetic resonance is another useful diagnostic tool, but is not as readily available as 2-D echo in clinical practice. It may be very useful in patients with a poor acoustic window, but was not necessary in our patients. Magnetic resonance imaging is very useful because it can distinguish congenital aneurysmal fibrosis with delayed contrast enhancement from a congenital diverticulum that has a normal signal.

Scintigraphic imaging with Tc-sestamibi often shows normal perfusion in the left ventricular diverticulum.

Diverticula are often clinically difficult to distinguish from congenital left ventricular aneurysms. The important diagnostic characteristics of the diverticulum are its narrow neck, normal ejection fraction, a systolic flow pattern from the diverticulum to the ventricle, and its small size and circular shape [8]. The histological exam of the surgically treated diverticulum confirms the presence of the three myocardial layers without fibrosis. In contrast, an LV aneurysm may be caused by a congenital or acquired abnormality, and in the latter case is often caused by coronary artery disease; it has a wide neck, no myocardial muscle layer on histology,

a layer of fibrous tissue which is occasionally calcified, and exhibits akinesis or paradoxical expansion during systole.

The natural history of a congenital ventricular diverticulum is not completely understood, but most patients remain asymptomatic and without complications throughout their lifetime, suggesting a benign clinical course [3].

As opposed to congenital or acquired aneurysms, cardiac diverticula, especially when isolated, entail a better prognosis [9, 10]. Nonetheless, a few fatal complications have been reported.

Spontaneous rupture of a diverticulum has been found in some patients with sudden death. Cardiac rupture seems to be more prevalent in the basal location, perhaps due to a predominance of fibrous lesions in this location [11].

Tachycardia and ventricular fibrillation are other mechanisms that may contribute to sudden death in these patients. Although there are too few cases to make any association with the location, it is interesting to note that the diverticular location in cases of sudden death involved inferior or posterior wall segments [12–14]. Among patients with symptomatic sustained ventricular tachycardia, the vast majority of these arrhythmias arise from re-entry circuits originating in the left ventricular congenital diverticulum.

Systemic embolism [15] has also been described as a very rare complication of a congenital diverticulum, but since the diverticulum contracts and the endocardium is normal, blood stasis is unlikely.

The treatment of a congenital diverticulum, because of its low prevalence, is not standardized, and large trials with long observation periods are lacking. Therefore, treatment modalities are determined by clinical presentation, findings in the individual patient, and the presence of associated midline or intracardiac anomalies, including ventricular septal defect, tetralogy of Fallot, and tricuspid atresia.

Surgical resection of the diverticulum is performed in patients who require the surgical correction of an associated congenital cardiac disorder. In such cases, the diverticulum is excluded by means of a cardiopulmonary bypass. In the case of an isolated ventricular diverticulum, plication and closure of the orifice can be achieved with a pericardial or Dacron patch without the need for cardiopulmonary bypass.

However, in patients with an asymptomatic ventricular diverticulum, treatment is somewhat controversial. Several institutions propose an early prophylactic surgical resection to avoid the risk of rupture, systemic thromboembolism, arrhythmias,

or sudden death [16]. Nevertheless, other authors, taking into account the small size of the diverticulum and the relatively benign prognosis in most cases, recommend conservative treatment and periodic follow-up if no changes in size are detected [3].

The characteristics and location of the diverticulum should be taken into account for patient management. For example, muscular diverticula are less likely to rupture than the fibrous type [17]. Also, the extremely rare cases of large diverticula may be a possible source of thromboembolic episodes, which suggests a potential indication for antiplatelet therapy or chronic anticoagulation in patients with a nonsurgical diverticulum. However, there is presently no clinical evidence to support this approach.

If symptoms appear, treatment should be started immediately. Patients with ventricular arrhythmias may be treated with antiarrhythmic drugs, and radiofrequency ablation may be considered for refractory cases. In patients with symptomatic sustained ventricular tachycardia not amenable to catheter ablation an implantable cardioverter-defibrillator could be necessary, but in the reports of patients with ventricular tachycardia such patients underwent surgical resection and cryoablation surgery. None of the reported patients received an implantable cardioverter-defibrillator.

Several authors suggest that contraction of the diverticulum may cause ischemia with chest pain and ECG changes, and such patients might benefit from treatment with beta-blockers.

When symptoms are refractory, or in the very rare cases of rapid growth of the diverticulum assessed by echocardiography, elective surgical resection should be considered [18].

Our patients had a small muscular diverticulum which caused no symptoms or complications, without risk of rupture, and hence they were not candidates for surgical resection. The decision was to follow them with annual echocardiography and Holter monitoring in order to assess the progression of the disease.

Conclusions

We may conclude that in adults, congenital diverticula not associated with defects of the thoracoabdominal midline or other congenital cardiac disorders are extremely rare. Two-D echocardiogram is a reliable tool for its diagnosis and follow-up in patients managed with a conservative approach. Given the few cases reported in the medical

literature, the information available is scarce, and that hinders its detection with imaging diagnostic methods. Although extremely rare, cardiac diverticula may be associated with high morbidity and mortality rates; hence, physicians should be trained to make the appropriate diagnosis.

The scarce knowledge about this condition underscores the need for a large, multinational registry to study the natural progression of the disorder and explore therapeutic options.

Acknowledgements

The authors do not report any conflict of interest regarding this work.

References

1. Brachlow A, Sable C, Smith S, Slack M, Martin G. Fetal diagnosis and postnatal follow-up of an asymptomatic congenital left ventricular diverticulum. *Pediatr Cardiol*, 2002; 23: 658–660.
2. Skapinker S. Diverticulum of the left ventricle of the heart, review of the literature and report of a successful removal of the diverticulum. *Arch Surg*, 1951; 63: 629–634.
3. Archbold RA, Robinson NM, Mills PG. Long-term follow-up of a true contractile left ventricular diverticulum. *Am J Cardiol*, 1999; 83: 810–813.
4. Takahashi M, Nishikimi T, Tamano K et al. Multiple left ventricular diverticula detected by second harmonic imaging: A case report. *Circ J*, 2003; 67: 972–974.
5. Cantrell JR, Haller JA, Ravitch MM. A syndrome of congenital defects involving the abdominal wall, sternum, diaphragm, pericardium and heart. *Surg Gynecol Obstet*, 1958; 107: 602–614.
6. Wu JM, Yu CY. Isolated congenital left ventricular diverticulum. *Pediatric Cardiol*, 1996; 17:254-256.
7. Huang G, Pavan D, Antonini-Canterin, F, Piazza R, Burelli C, Nicolosi GL. Asymptomatic isolated congenital left ventricle muscular diverticulum in an adult: A case report. *Echocardiography*, 2003; 20: 191–196
8. Teske DW, McGovern JJ, Allen HD. Congenital fibrous left ventricular diverticulum. *Am Heart J*, 1993; 126: 1233–1235.
9. Barutcu I, Gullu H, Kosar F. Isolated true contractile left ventricular diverticulum in an adult patient. *Internat J Cardiol*, 2004; 97: 141–142.
10. Marijon E, Ou P, Fermont L et al. Diagnosis and outcome in congenital ventricular diverticulum and aneurysm. *J Thorac Cardiovasc Surg*, 2006; 131: 433–437.
11. Mady C. Left ventricular diverticulum: analysis of two operated cases and review of the literature. *Angiology*, 1982; 33: 280–286.
12. Maloy WC, Arrants JE, Sowell BF, Hendrix GH. Left ventricular aneurysm of uncertain etiology with recurrent ventricular arrhythmias. *N Engl J Med*, 1971; 285: 662–663.
13. Fellows CL, Bardy GH, Ivey TD, Werner JA, Draheim JJ, Greene HL. Ventricular dysrhythmias associated with congenital left ventricular aneurysm. *Am J Cardiol*, 1986; 57: 997–999.
14. Tandar A, Meredith KG, Anderson JL. Multiple left ventricular diverticuli in an asymptomatic adult: Case report and review of the literature. *Catheter Cardiovasc Interv*, 2007; 69: 453–458.
15. Bell WE, Ehmke DA. Diverticulum of the left ventricle in a child with fatal cerebral embolization. *South Med J*, 1971; 64: 537–540.
16. Uchida T, Uemura H, Yagihara T, Kawahira Y, Yoshikawa Y, Kitamura S. Congenital diverticulum of the left ventricle. *Jpn J Thorac Cardiovasc Surg*, 2001; 49: 244–246.
17. Ichikawa K, Makino K, Futagami Y. Isolated congenital left ventricular diverticulum in an adult. A case report. *Angiology*, 1994; 45: 743–747.
18. Hasse J, Mihatsch JM, Wolff G, Gradel E. Therapy of refractory ventricular tachycardia in congenital diverticulum of the left ventricle. Clinical aspects and surgical therapy of a rare malformation. *Schweiz Med Wochenschr*, 1976; 106: 182–185.