

Fungal endocarditis complicated by shock in the course of long-term permanent cardiac pacing

Wiesława Duszyńska¹, Grażyna Kübler¹, Joanna Moszczyńska-Stulin¹, Jarosław Janc¹,
Andrzej Dumański², Anna Goździk² and Andrzej Kübler¹

¹Department of Anaesthesiology and Intensive Therapy, Wrocław Medical University, Wrocław, Poland

²Department of Cardiac Surgery, Wrocław Medical University, Wrocław, Poland

Abstract

The case is presented of a 52-year-old female patient who was diagnosed as having fungal endocarditis due to the Mucor species infection. The patient had had permanent cardiac pacing for 23 years. She was admitted to the hospital with symptoms of sepsis, and TTE revealed the development of vegetations on the pacemaker leads. Cardiac surgery with removal of the infected system was performed and a new pacemaker with an epicardial lead was implanted. After the surgery the patient's clinical course was complicated by multiple organ dysfunction syndrome and septic shock, which was resistant to traditional treatment. Administration of human recombinant activated protein C (Xigris) improved organ function and enabled selective antifungal therapy to be continued. The patient was discharged from hospital 48 days later in a good condition. (Folia Cardiol. 2006; 13: 344–347)

endocarditis, sepsis, mucormycosis, permanent cardiac pacing, activated protein C

Introduction

Mucormycosis is an infrequent acute fungal infection, which has an extremely high mortality rate even with aggressive surgical intervention. The manifestations of such endocardial and valve mucormycosis have been reported in patients after cardiac surgery [1, 2]. The major aetiological agents of mucormycosis are common saprophytic mould fungi (of the Mucorales type), frequently found in the soil and decaying food and vegetables. The spores of these fungi are ubiquitous and gain entrance to the human body through the mouth and nose, where they attach themselves to the nasal or oral

mucosa in the form of characteristic deeply furrowed cotton-like colonies. Spread occurs when the fungus invades the nasal cavity, which may result in rapid progressive pneumonia. The spores may also enter the body through injured skin and/or surgical wounds, directly invading blood vessels, which can lead to inflammation, thrombosis, infarctions and necrosis of the infected tissue. Infection is described almost exclusively in patients with compromised immune systems and in patients with poorly controlled diabetes. The conditions most commonly associated with this type of infection also include chronic steroid use, antibiotic therapy and treatment with cytostatics [3]. Thus far, to the author's knowledge, there have been no reports describing fungal endocarditis caused by *Mucor species* in the course of long-term cardiac pacing.

Address for correspondence: Dr med. Grażyna Kübler
Department of Anaesthesiology and Intensive Therapy
Wrocław Medical University
Chalubińskiego 1a, 50–368 Wrocław, Poland
Tel: +48 71 784 26 75, fax: +48 71 327 04 24
e-mail: office@anest.am.wroc.pl
Received: 23.08.2005 Accepted: 7.04.2006

Case description

A 52-year-old female patient with cardiac pacing programmed in VVI mode and implanted in

1981 was admitted to the hospital because of sick sinus syndrome and a third degree paroxysmal AV block followed by loss of consciousness. In 1990, 9 years after the initial implantation, she was admitted to the Electrostimulation Department for the first follow-up as a result of a sudden loss of consciousness. The investigation revealed malfunction of the pacemaker lead and the patient was readmitted for implantation of a new pacemaker system. Because of venous confluence malformation, access to the same pocket of the heart was achieved through the right external jugular vein and the old lead was removed. However, the patient did not comply with the pacemaker follow-up protocol. In 2002 she was admitted to the hospital following several episodes of fainting. The pacemaker battery was completely discharged, requiring immediate replacement. Following these two surgical interventions no complications were reported during the perioperative period. Two years later, in August 2004, the patient was readmitted because of purulent drainage from the surgical wound on the neck. She reported that she had been unsuccessfully trying different home methods to treat the wound. Under the cefuroxim antibiotic cover the inflamed tissues were removed, which resulted in a proper healing of the wound. All cultures of the wound drainage developed *Staphylococcus epidermidis* strains. According to well-accepted standards for active endocarditis, blood samples were collected and the microbiological cultures were performed in the universal growth medium BacT/ALERT. All the blood cultures were negative, and the good clinical condition of the patient did not suggest ongoing endocarditis at that time. The patient was discharged from hospital on prescribed antibiotic treatment (for two weeks), which included amoxycyclin with clavulanic acid. Six weeks later she developed fever, hyperhidrosis, cough and a general progressive weakness. After one week of in which she self-administered antipyretic drugs she was admitted to another local hospital and was initially treated for pneumonia. After a few days, diagnosed with endocarditis, she was admitted for continuing treatment to the Department of Cardiac Surgery. The transoesophageal echocardiography examination showed enlargement of the left ventricle (ED = 68 mm, ES = 50 mm) with decreased global ventricular function, and the ejection fraction was 46.5% (according to the Teicholtz formula). Furthermore, one of the pacemaker leads in the atrium showed the presence of a large spherical mass (24.5 × 21 mm), indicating vegetations balling out into the ostium of the tricuspid valve (Fig. 1). No vegetation was

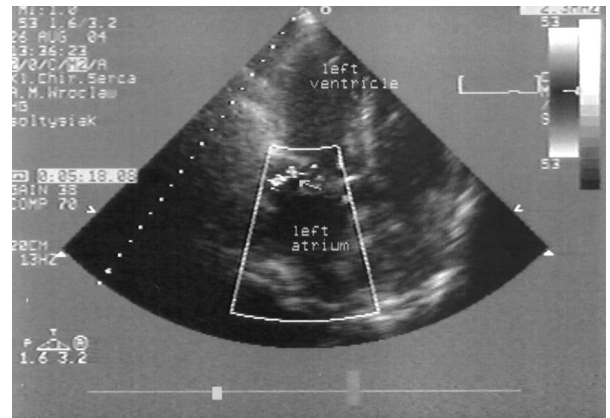


Figure 1. Two-dimensional echocardiograph showing massive vegetations on the pacing lead in the right atrium.

noted on the slightly thickened cusps of either the mitral or the tricuspid valves, which had signs of mild regurgitation. Blood cultures were still negative. The patient, who was qualified for urgent surgical intervention, was treated empirically with vancomycin and cefuroxim. During surgery both endocavitary leads were removed. There was one large mass of vegetation (30 × 20 × 10 mm) and several small ones attached to one of the leads. The old pacemaker system was extracted and the new one was implanted into the abdominal integument and then connected with the epicardiac pacing lead. Tricuspid valvuloplasty was also performed. Samples for microbiological tests (cardiac cavity blood, cardiac and tricuspid valve tissue and pacing lead tips) were collected during the surgery. Tissue samples and the lead tips were placed into sterile containers with Schaedler medium, used for the cultivation of fungi. Blood samples were collected in BacT/ALERT medium and a wound swab, performed by using wooden applicators, was transferred into the AMIES BO41 (AAGMED RAWA) vial with transport medium. All samples were immediately sent to the microbiological clinical laboratory. Although antibiotic therapy was continued with the adjunction of antifungal drug 5-fluorocytosin, the fever still persisted. On the patient's neck along the right jugular vein a swelling and redness of the area where the old lead had been placed were observed as well as an increase in skin surface temperature and significant swelling of the right arm. Four days later the patient's clinical course deteriorated as a result of circulatory and respiratory insufficiency, and she was transferred for further treatment to the Department of Anaesthesiology and Intensive Therapy. Despite intensive supportive care her

clinical course was complicated by septic shock with multiple organ dysfunction syndrome. The patient was intubated and an optimal treatment according to standard procedures was initiated [4]. The 7-day microbiological cultures of the intraoperative samples developed an exclusive fungus. On the basis of the macroscopic and microscopic findings the fungus was identified as *Mucor species*.

Previous antibiotic therapy was stopped and meronem with amphotericin B was administered. In view of the patient's continued deterioration and lack of reaction to the antimicrobial therapy, human recombinant activated protein C (Xigris, Eli Lilly) was added (96-hour infusion) on the third day of septic shock, which resulted in gradual stabilisation of the circulatory system and significantly improved liver and kidney function parameters on the second day of treatment. The patient was extubated 15 days after surgery and non-invasive ventilation was then conducted through a nose mask. A control TTE examination indicated that left ventricle enlargement (ED = 62 mm, ES = 43 mm) and ejection fraction were improved (EF = 52%). No vegetations were detected and all blood samples were negative. In addition, both the pulmonary changes and the local skin infections of the neck healed rapidly, and on day 28 the patient started her own respiration. At this point she was given oral drugs including karwedilol, digoksin, furosemid, and trandolarpil. After 48 days of hospitalisation the patient was discharged in a good condition, cardiological medications having been prescribed. At present (June 2005) the patient has shown no recurrence of infection recurrence during 6 months follow-up, and her clinical condition is good. However, recent TTE examinations have identified enlargement of the left ventricle (ED = 63 mm, ES = 43 mm) with an ejection fraction EF = 55% and slight thickening of both the mitral and tricuspid valves without any signs of vegetation. Additional follow-up examinations have revealed no cardiac insufficiency.

Discussion

Infective endocarditis is a rare complication of permanent cardiac pacing. The incidence of infection following pacemaker implantation ranges from 1% to 7% and is caused mostly by staphylococci [5–8]. Fungal endocarditis is very infrequent and thus far only a few clinical cases have been described. Most commonly it is caused by *Candida albicans*, *Aspergillus fumigatus*, and *Acremonium species* [9–12]. Fungal endocarditis is particularly common following repeated surgeries involving pacemaker sys-

tem replacements or in association with infections of surgery wounds, bedsores, and fistulae in the pacemaker area, as well as prolonged antibiotic therapy. Mortality rate in the course of fungal endocarditis is high (40–70%) and in patients undergoing conservative therapy may even reach 100% [5, 8, 13]. The diagnosis is often delayed because of negative test cultures at the early stages and the fact that admission to the hospital usually takes place at an advanced stage of the disease. According to published reports, transthoracic and, particularly, transoesophageal echocardiography seem to be very useful for early diagnosis of endocarditis [9, 10, 13]. This should be performed in all patients with prolonged fever who have implanted cardiac electrotherapy devices (defibrillators and pacemakers). Common features of fungal endocarditis, often observed intraoperatively, are large vegetations with extensive infiltrations and focal lesions in the cardiac muscle.

Early diagnosis of mucormycosis endocarditis is very difficult and is usually proven at autopsy. Mycological tests are time consuming and are usually performed by means of direct microscopic evaluation or culture of different samples, including secretions, tissues and blood. In all the cultures studied a compact mass of threadlike irregular filaments can be observed, forming the mycelium of a fungus.

Spores of *Mucor species* can be inhaled through the mouth and nose, or they may enter the body through injured skin, directly invading the blood vessels, which can lead to inflammation and systemic infection (sepsis) or its severe form — septic shock. Despite advances in diagnosis, treatment of mucormycosis endocarditis is very difficult. The use of prolonged amphotericin therapy combined with surgery (extraction of the source of infection) remains the mainstay of treatment. Amphotericin is a high efficiency antifungal drug but has many serious side effects. It is important to continue using this medicine for at least two weeks and, if it is well tolerated, even up to 6–8 weeks.

In the reported case it was not possible to establish definitely the exact time and entry of the fungal infection. Although inoculation of the fungus could take place through the surgical wound after the previous surgical replacement of the cardiac pacemaker (in 2002), such a long period from the onset of infection to the first symptoms of the disease seems unlikely. It is quite possible that our patient developed a respiratory tract infection caused by spores inhaled from the air which subsequently penetrated to the blood vessels. Another possibility could be a neck wound infection at the

site of the damaged skin above the pacemaker lead and an expansion of the inflammatory process to the heart. The last mechanism seems to be the most likely. This was a patient at high-risk of infective endocarditis because of several factors, including surgical interventions, the presence of two pacemaker leads in the heart (one of which was 23 years old) and patient non-compliance with follow-up regimens. All the procedures in this case were therefore performed urgently because of the life threatening condition of the patient (disruption of lead continuity, complete discharge of the pacemaker battery, using home methods to heal the neck wound and high fever upon hospital admission). The *Mucor species* fungus, which is resistant to standard chemotherapeutics and which was a major aetiological factor, was detected in test cultures 7 days after surgery. By this time the patient had developed all the symptoms of septic shock. However, she survived because of the successful therapeutic management of septic shock and multiple organ dysfunction, performed at the Department of Anaesthesiology and Intensive Therapy. Another critical factor was the administration of human recombinant activated protein C, which significantly reduces mortality in patients with severe sepsis and organ failure [4]. According to recent reports, this drug is an effective anticoagulant and has anti-inflammatory, anti-apoptotic, and profibrinolytic properties. In the reported case this drug blocked the development of circulatory-respiratory dysfunction, which resulted in more effective antibiotic activity. The septic shock treatment with activated protein C may be associated with the non-specific action of this drug. This mechanism may be responsible for inhibiting the pathomechanism of sepsis, not by directly influencing pathogenic micro-organisms, but rather by breaking the vicious circle of the self-driving pathological processes such as inflammation and intravascular clotting.

This is a new and extremely promising direction for the effective therapy of difficult systemic infections and septic shock. However, administration of human recombinant protein C should take place only under very strictly controlled conditions and according to well-established indications and contraindications associated with the monitoring of the clinical course [4]. This drug may, therefore, only be applied in intensive care units.

Conclusions

1. Fever of unknown aetiology in patients with implanted cardiac electrotherapy systems should

always carry a clinical suspicion of infective endocarditis.

2. Fungi may be considered an aetiological factor of infective endocarditis.
3. Echocardiography evaluation is a valuable diagnostic procedure in patients clinically suspected of infective endocarditis.
4. The only effective management of patients with infective endocarditis and vegetations detected on pacemaker leads requires urgent removal of the entire pacing system and administration of empirical followed by direct antibiotic therapy.
5. Administration of human recombinant activated protein C significantly reduces multiple organ dysfunction during the course of septic shock and enables further effective therapy to be performed.

References

1. Sanchez-Recade A, Mo JL, Domínguez F, Mate I. Successful treatment of prosthetic aortic valve mucormycosis. *Chest*, 1999; 116: 1818–1820.
2. Tedder M, Sprat J, Anstadt M, Hedge S, Tedder S, Love J. Pulmonary mucormycosis: results of medical and surgical therapy. *Ann Thorac Surg*, 1994; 57: 1044–1050.
3. Simon K, Rotter K, Jeleń M, Gładysz A. Mukormykoza mózgu u pacjenta z zespołem nabytego upośledzenia odporności AIDS. *Mikol Lek*, 1977; 4: 175–178.
4. Dellinger RP, Carlet JM, Masur H et al. Surviving sepsis. Campaign guidelines for management of severe sepsis and septic shock. *Crit Care Med*, 2004; 32: 858–873.
5. Laguno M, Miro O, Font C, de la Sierra A. Pacemaker-related endocarditis. Report of 7 cases and review of the literature. *Cardiology*, 1998; 90: 244–248.
6. Van Camp G, Vandebossche JL. Recognition of pacemaker lead infection by transoesophageal echocardiography. *Br Heart J*, 1991; 65: 2290–2300.
7. Clug D, Lacrois D, Savoye Ch et al. Systemic infection related to endocarditis on pacemaker leads. Clinical presentation and management. *Circulation*, 1977; 95: 2098–2107.
8. Meszaros J. Chemioterapia infekcyjnego zapalenia wsierdza: przyjęte poglądy i kontrowersje. *Kardiol Pol*, 2003; 58: 15–28.
9. Wilson HA, Downes TR, Julian JS, White WL, Haponik EF. Candida endocarditis. A treatable form of pacemaker infection. *Chest*, 1993; 103: 283–284.
10. Cole WJ, Slater J, Kronzon I et al. Candida albicans — infected transvenous pacemaker wire: detection by two-dimensional echocardiography. *Am Heart J*, 1986; 111: 417–418.
11. Dunn ChJ, Ruder M, Deresinski SC. Aspergillus fumigatus infection of an automatic internal cardiac defibrillator. *PACE*, 1996; 19: 2156–2157.
12. Kouvousis N, Lazaros G, Christoforatu E et al. Pacemaker pocket infection due to *Acremonium species*. *PACE*, 2002; 25: 378–379.
13. Bohm A, Banyai F, Preda I, Zamolyi K. The treatment of septicaemia in pacemaker patients. *PACE*, 1996; 19: 1105–1111.