

# Endocarditis with aortic root pseudoaneurysm rupture

Michael W. Fong<sup>1</sup>, Peter Knight<sup>2</sup>, John H. Schriefer<sup>1</sup>,  
Ehab Eassa<sup>3</sup> and Thomas A. Rocco Jr.<sup>1</sup>

<sup>1</sup>Department of Medicine, Division of Cardiovascular Disease, University of Rochester, USA

<sup>2</sup>Department of Surgery, Division of Cardiac Surgery, University of Rochester, USA

<sup>3</sup>Highland Hospital, Cardiology Division, Rochester, USA

## Abstract

*We report a case of aortic valve endocarditis complicated by aortic root pseudoaneurysm and rupture.* (Cardiol J 2007; 14: 202–204)

**Key words:** endocarditis, aortic valve, pseudoaneurysm, cardiac surgery

A 74 year-old woman presented to the Emergency Department after three days' dyspnoea and orthopnoea, as well as cough and vague chest pain. She had been discharged from the hospital 6 weeks previously, following an admission for *E. coli* urosepsis complicated by a perinephric abscess, but denied any fevers or chills on this presentation.

On physical exam in the Emergency Department, she was afebrile, with a heart rate of 71 beats per minute and a respiratory rate of 24 breaths per minute, and hypotensive, with a blood pressure/wide pulse pressure of 85/30 mm Hg. Her oxygen saturation was 88.9% by pulse oximetry. She appeared to be in moderate respiratory distress and on lung examination had diffuse crackles. An S3 gallop was heard on cardiac auscultation, and 1+ oedema was noted to the mid-calf level. Chest radiography showed diffuse interstitial markings consistent with pulmonary oedema.

The patient was initially treated with diuretics, antibiotics for possible community acquired pneumonia, and BiPAP. Her oxygen saturation improved over

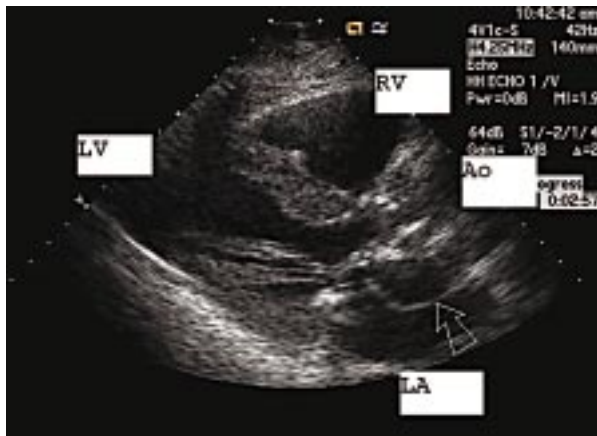the course of 4 h, and she was eventually placed on a Venturi mask. Shortly afterwards the patient became acutely agitated, short of breath and hypoxaemic. She was intubated and admitted to the Critical Care Unit.

On admission to the unit, the patient was noted by the critical care team to be mottled and bradycardic, with a heart rate of 50 beats per minute. She was tachypnoeic, with a respiratory rate of 33 breaths per minute, and hypotensive, with a blood pressure of 72/36 mm Hg. Laboratory studies revealed profound metabolic acidosis with a CO<sub>2</sub> < 10 mEq/L, serum potassium of 6.3 mEq/L, an anion gap of 29 and arterial lactate of 11.4 U/L. She had a white blood-cell count of 12,400, haematocrit of 29%, serum creatinine of 1.7 mg/dL, troponin T of 0.17 mg/dL (normal < 0.01 mg/dL) and an INR of 12.4.

The patient had an episode of sustained ventricular tachycardia, for which she was cardioverted into sinus rhythm. An ECG revealed normal sinus rhythm with a QS complex in leads V1–V3 and ST depression in V3–V5.

Because of persistent hypotension, she was volume resuscitated with *i.v.* normal saline and transfused with two units of fresh frozen plasma and one unit of packed red blood cells. Pressor support was initiated with *i.v.* levophed and dopamine, and an emergency cardiology consult was obtained. On cardiac examination by the consultant the patient was noted to have a “to-and-fro” systolic/diastolic murmur.

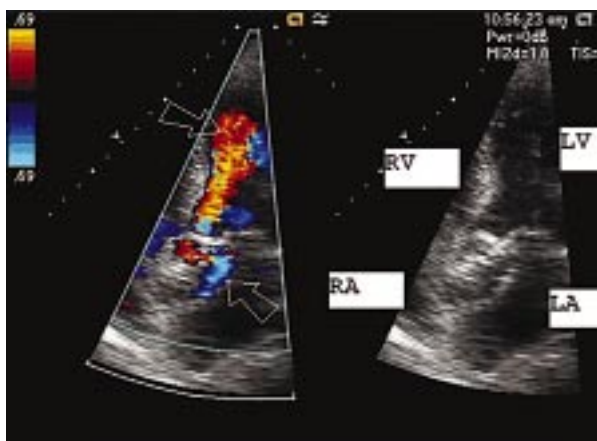
Address for correspondence: Dr. Michael W. Fong  
University of Rochester Medical Center  
601 Elmwood Avenue, Rochester, NY 14642, USA  
Tel: (585) 275 2222, fax: (585) 341 8489  
e-mail: Michael\_Fong@urmc.rochester.edu  
Received: 18.11.2006 Accepted: 27.01.2007



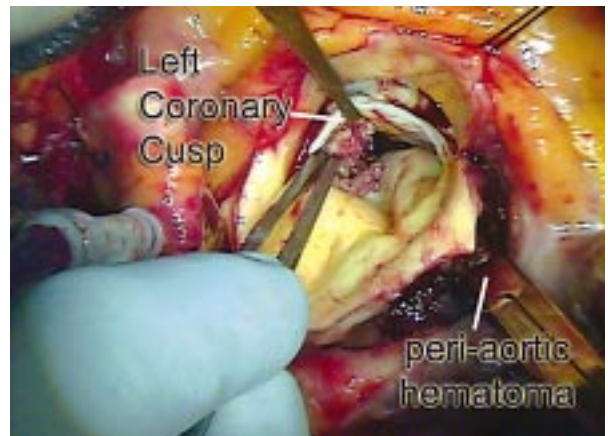
**Figure 1.** Parasternal long axis view demonstrating formation of pseudoaneurysm adjacent to the left sinus of Valsalva (indicated by arrow).

An emergency trans-thoracic Doppler-echocardiogram revealed an abnormal aortic valve and aortic root enlargement with a double-lumen appearance in the region of the non-coronary cusp (Fig. 1). Doppler/coulour flow interrogation revealed significant aortic regurgitation (Fig. 2) with significant aorto-right atrial fistula flow. There was also evidence of aortic stenosis and mild-to-moderate mitral and tricuspid regurgitation. Examination of the left ventricle revealed mild left ventricular hypertrophy with normal systolic function.

Blood cultures were drawn, and *i.v.* zosyn and vancomycin were administered. Arrangements were made for urgent transfer to our tertiary care centre and evaluation by the cardiothoracic surgical staff.



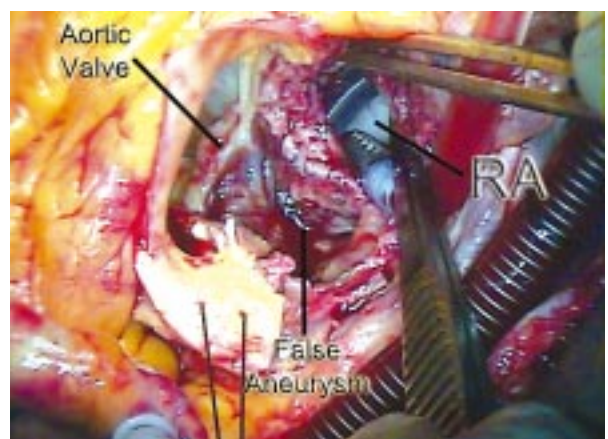
**Figure 2.** Apical 5-chamber view (right) with colour flow Doppler (left) demonstrating aortic regurgitation (red colour, top arrow) as well as flow from aortic root into the pseudoaneurysm (bottom arrow, blue colour).



**Figure 3.** Superior view of the aortic valve following aortic resection. There is evidence of endocarditis on the valve and haematoma in the pseudoaneurysm cavity.

Upon the patient's arrival at the tertiary centre a transoesophageal echocardiogram was performed and the patient was taken urgently to the operating room. She was found to have active endocarditis (Fig. 3), with a perforation of the non-coronary sinus of Valsalva, resulting in a large aorto-right atrial fistula as well as an aorto-left ventricular fistula (Fig. 4). The defect in the right atrial free wall measured 10 cm<sup>2</sup>.

Bicaval cannulation with moderate hypothermia and retrograde cardioplegia were utilised. The aorta was transected 4 cm above the sinotubular junction, the aortic leaflets resected and the fistula identified. The ascending aorta was resected and the abscess cavity debrided. The defect in the right atrium was identified and the edges were debrided. The defect was patched with bovine pericardium,



**Figure 4.** Relationship of the aortic valve, pseudoaneurysm and right atrial fistula viewed from above.

and the aortic valve and ascending aorta replaced with a porcine root. The patient was discontinued from cardiopulmonary bypass without difficulty and admitted to the Cardiac Care Unit for further management.

The patient was seen at a follow-up visit three months after discharge and was doing well.

### Discussion

An aorto-right atrial fistula is a rare phenomenon, which has been reported in the presence of aortic dissection [1], sinus of Valsalva aneurysm rupture [2], following blunt trauma [3] and as a congenital anomaly [4]. It has rarely been seen in post-surgical scenarios, including aortic valve replacement [5] and aortic dissection repair [6], and as an iatrogenic complication following internal jugular vein catheterisation [7] and closure of an atrial septal defect using an Amplatzer device [8]. It has also been reported as a complication of rheumatological diseases, including rheumatoid arthritis [9] and Bechet's disease [10].

To our knowledge, this is the first report of an aorto-right atrial fistula in the presence of native aortic valve endocarditis. Darwazah et al. [11] previously reported a case of inflammatory periprosthetic valvular leak and fistula formation, and Akowuah et al. [12] reported a case of fistula associated with native tricuspid valve endocarditis.

In the rare cases of aorto-right atrial fistula patients frequently present with refractory heart failure. However, sudden onset pulmonary oedema and chest pain have also been reported. A continuous murmur is often heard on physical examination, and echocardiography demonstrates turbulent flow into the atrium throughout the cardiac cycle, but mainly in systole. The treatment is surgical correction with repair of the affected aortic segment as well as annular debridement and valve replacement if necessary [13].

### References

1. Fujii H, Oka T, Kawaguchi H. et al. Aorto-atrial fistula associated with recurrent aortic dissection after ascending aorta replacement. *J Cardiovasc Surg*, 1998; 39: 817–819.
2. Cullen S, Sullivan ID. Images in cardiovascular medicine. Ruptured sinus of Valsalva with aorta-to-right atrial fistula. *Circulation*, 1998; 98: 2503–2504.
3. Chang H, Chu SH, Lee YT. Traumatic aorto-right atrial fistula after blunt chest injury. *Ann Thorac Surg*, 1989; 47: 778–779.
4. Hsu JT, Ho WJ, Wang CL, Cheng NJ. Heart failure due to giant congenital aorto-right atrial fistula: report of a case. *Int J Clin Pract Suppl*, 2005; 147: 9–11.
5. Badak O, Akdeniz B, Aslan O, Kirimli O, Goldeli O, Guneri S. Rare complication of aortic valve replacement: aorto-right atrial fistula. *Anadolu Kardiyol Derg*, 2003; 3: 373.
6. Jassal DS, Neilan TG, Hung J. A continuous murmur. *Echocardiography*, 2006; 23: 60–61.
7. Danenberg HD, Hasin Y, Milgalter E et al. Aorto-atrial fistula following internal jugular vein catheterization. *Eur Heart J*, 1995; 16: 279–281.
8. Chun DS, Turrentine MW, Moustapha A, Hoyer MH. Development of aorta-to-right atrial fistula following closure of secundum atrial septal defect using the Amplatzer septal occluder. *Catheter Cardiovasc Interv*, 2003; 58: 246–251.
9. Crean PA, Reid DS, Buchanan J. Aorto-atrial fistula in rheumatoid arthritis. *Ann Rheum Dis*, 1983; 42: 203–205.
10. Melua A, Campbell N, McCluskey D, MacGowan SW. Aorto-atrial fistula without aneurysm formation in Behcet's disease. *Heart*, 1998; 80: 200–201.
11. Darwazah A, Kiswani M, Ismail H, Hawari M, Awad S. Aorto-right atrial fistula: a complication of prosthetic aortic valve endocarditis. A case report. *J Heart Valve Dis*, 2006; 15: 142–145.
12. Akowuah EF, Casula R, Thanos A, Cooper GJ. Aorto-right atrial fistula associated with native tricuspid valve endocarditis. *J Cardiovasc Surg (Torino)*, 2002; 43: 841–842.
13. Ananthasubramaniam K. Clinical and echocardiographic features of aorto-atrial fistulas. *Cardiovasc Ultrasound*, 2005; 3: 1.