

Repeated ventricular “torsade de pointes” tachycardia and cardiogenic shock in the course of hypothyroidism

Krzysztof Chojnowski¹, Anna Bielec¹, Marek Czarkowski¹, Joanna Dmowska-Chalaba¹,
Janusz Kochanowski² and Agnieszka Wąsowska³

¹Chair and Department of Internal Medicine and Endocrinology, Medical University, Warsaw, Poland

²Chair and Department of Cardiology, Medical University, Warsaw, Poland

³Public Medical Center for Postgraduate Schools, Warsaw, Poland

Abstract

Few publications report the possibility of “torsade de pointes” (TdP) type tachycardia and ventricular fibrillation occurring in patients with prolonged QT syndrome in the course of hypothyroidism. The authors present the case of a 51-year-old woman with Hashimoto disease and hypothyroidism, inadequately supplemented with L-thyroxine. This patient was admitted to the ward with symptoms of hypometabolic crisis. She was diagnosed with shock and had marked sinus bradycardia with a QT interval prolongation of 0.8 s and paroxysmal TdP-type ventricular tachycardia. TdP was triggered by R-on-T ventricular extrasystoles. Laboratory tests revealed profound hypothyroidism. As pharmacological treatment of the arrhythmia and bradycardia was ineffective, an endocavitary electrode was introduced. As a result of ventricular stimulation with a frequency of 90/min, shortening of the QT interval and disappearance of the cardiac arrhythmia and cardiogenic shock symptoms were obtained. L-thyroxine was administered and two days later ventricular stimulation was discontinued. When corrected for heart rate, the QT interval (QT_c) was 0.43 s and no QT prolongation was detected in the course of a follow-up period of several months, during which L-thyroxine supplementation was adequate. Hypothyroidism may be the cause of life-threatening arrhythmias secondary to acquired long QT syndrome. Ventricular electrostimulation proved to be a life-saving intervention in this case in which prolonged QT syndrome and ventricular cardiac arrhythmias complicated hypometabolic crisis. (Cardiol J 2007; 14: 198–201)

Key words: hypothyroidism, long QT interval, torsade de pointes

Introduction

It is well known that an excess or deficit of thyroid hormones affects the cardiovascular system. A typical ECG in hypothyroidism shows bradycardia, a low voltage of the QRS complexes, elongation of the PQ and flattening or inverting of the T waves [1]. However, less well known is the fact that hypothyroidism may be the cause of atrioventricular blocks and of acquired long QT syndrome (LQTS). Only a few publications report life-threatening

Address for correspondence: Dr med. Krzysztof Chojnowski
Chair and Department of Internal Medicine
and Endocrinology, Medical University
Banacha 1a, 02–097 Warszawa, Poland
Tel: +48 22 599 29 70, e-mail: Krzycho@amwaw.edu.pl
Received: 13.09.2006 Accepted: 23.11.2006

Table 1. Presents some of the pathological findings in physical examination, QTc (corrected QT interval) and major biochemical results in course of hospitalisation.

Parameter	Norm	15.09.2003			16.09.2003	22.09.2003	08.10.2003
		0.00	2.00	6.00			
Temperature		34.7°C	35.8°C	36.0°C	36.1°C	36.1°C	
Blood pressure [mm Hg]		70/40	90/60	110/60	120/70	135/95	
Heart rhythm [1/min]		56	55	91	60	64	88
QTc [s] by Bazett's formula		0.71	0.66 (stymulate)	0.62 (stymulate)	0.54	0.34	0.43
TSH [μ IU/mL]	0.49–4.67	246.6				174.9	8.14
fT ₃ [pg/mL]	1.45–3.48	0.66					
fT ₄ [ng/dL]	0.71–1.85	0.33					
Na ⁺ [mmol/L]	137–149	141			141	138	132
K ⁺ [mmol/L]	3.6–5.0	3.4			4.4	4.8	4.50
Ca ²⁺ [mmol/L]	2.20–2.75	1.95			2.64	2.43	
Creatinine [mmol/L]	44–124	159			115	65	97
Anty-TPO [IU/ml]	< 100	1375					

paroxysmal ventricular fibrillation occurring in patients with prolonged QT syndrome in the course of hypothyroidism [2–4]. The most common causes of acquired LQTS are drugs (anti-arrhythmic, antipsychotic, tricyclic antidepressant or cisapride), organic heart disease, dyselectrolytaemia (hypokalaemia, hypocalcaemia and hypomagnesaemia) and metabolic factors [5]. It is important to emphasise that hypothyroidism is not mentioned as one of the causes of acquired LQTS even in significant sourcebooks, and there are only a few notes in monographs dealing with the subject [6, 7].

Case report

A 51-year-old woman with hypothyroidism in the course of Hashimoto disease diagnosed three years previously (a high titer of thyreoperoxidase antibodies; Table 1) was hospitalised because of deterioration in her general condition and disturbances of consciousness. During the transport to hospital torsade de pointes (TdP)-type tachycardia occurred (Fig. 1A). On admission to Casualty and then to The Department of Internal Diseases and Endocrinology she was in a serious general condition, lethargic and without logical verbal contact. Data on her history received from a family member disclosed that for the last few weeks she had reduced the dose of L-thyroxine and tri-iodothyronine taken without prior consultation with her endocrinologist.

Physical examination revealed signs of hypometabolic crisis (Table 1), and therefore 200 mg

of hydrocortisone were administrated intravenously. Because of anamnesis of persistent headaches over three weeks, nausea, generalised muscle weakness and a positive Babinski sign on the right side, which were present on physical examination, computed tomography and ophthalmological examination were performed with no abnormal findings.

In ECG and in telemetric monitoring sinus bradycardia was recorded with marked QT interval prolongation (Fig. 1B, Table 1) and R-on-T ventricular extrasystoles (Fig. 1C). Some of the extrasystoles triggered numerous episodes of paroxysmal ventricular tachycardia (Fig. 1D). A dose of 150 mg of amiodarone in bolus injection terminated the tachycardia for several minutes. Because of the relapse of ventricular arrhythmias, continuous amiodarone infusion was started (300 mg of amiodarone in 5% glucose at a velocity of 6.2 ml/h). Owing to hypotonia and electrolytic disturbances (Table 1) fluids containing KCl and CaCO₃ were administered intravenously. During the two-hour amiodarone infusion we observed clinically significant bradycardia (55–30/min), hypotension and elongation of the QT interval to 0.79 s. We discontinued the drug administration, introduced an endocavitary electrode and forced stimulation with a frequency of 90/min. We observed a shortening of the QT interval to 0.46 s (Fig. 1E) and resolution of the symptoms of cardiogenic crisis. Nine hours after admission to the department temporary electrostimulation was switched off. In ECG monitoring we initially observed sinus rhythm 82/min (QTc 0.6) but after about 60 minutes

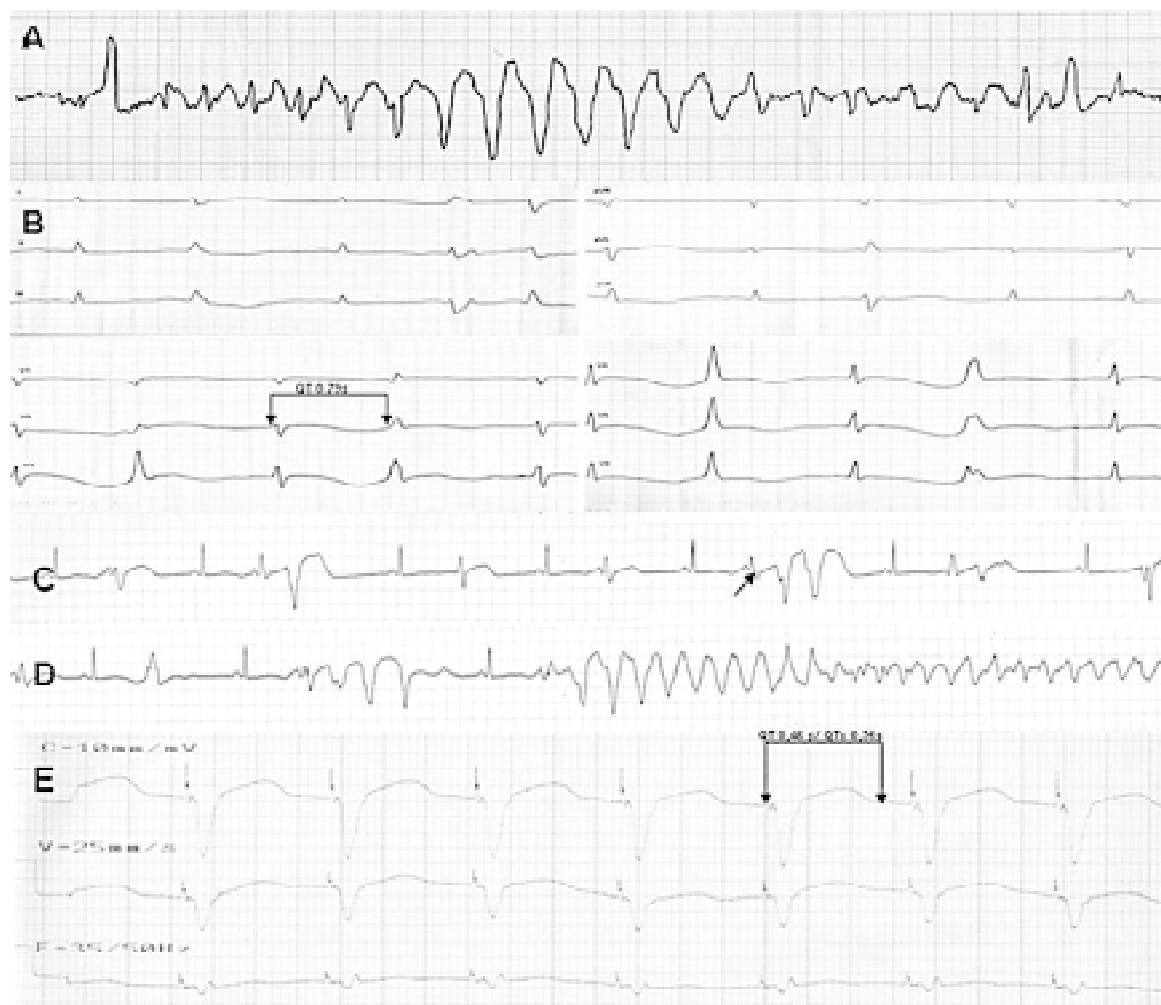


Figure 1. A. Torsade de pointes paroxysmal ventricular tachycardia registered prior to hospitalisation (by an Emergency Ambulance Unit) in a patient with a hypometabolic crisis; B. Prolongation of QT interval and multifocal ventricular extrasystoles prior to onset of endocavitary electrode stimulation; C. Ventricular R-on-T extrasystoles (pointer); D. Ventricular extrasystoles and ventricular tachycardia triggered by R-on-T extrasystoles registered on telemetry; E. Endocavitary electrode-evoked rhythm.

bradycardia (about 50 beats per minute) appeared with episodes of paroxysmal ventricular tachycardia of 150–200 beats per minute. We decided to continue the electrostimulation. The first oral dose of 50 µg of L-thyroxine was given eight hours after admission to the hospital. After laboratory tests, which revealed a very low concentration of free thyroxine and a high concentration of thyroid-stimulating hormone (Table 1), the drug dose was increased to 150 µg per day.

During the second day of hospitalisation, after compensating for electrolyte deficiency, external stimulation was discontinued. In ECG and telemetry monitoring stable regular sinus rhythm (52–69/min) remained and there were no marked decreases in blood pressure (Table 1). Ventricular tachy-

cardia did not return and consequently we stopped the electrostimulation and removed the endocavitary electrode. Within the next few days QTc was within the range 0.42 to 0.44.

In the echocardiograph performed on the third day of hospitalisation only impairment of the relaxation of the left ventricle was recorded. After one week of L-thyroxine supplementation the defect of relaxation disappeared. In neither examination were contraction disturbances, valve disorders or the presence of fluid in the pericardium observed.

During the first few days of hospitalisation we administered hydrocortisone because of the possibility of concomitant adrenal insufficiency due to autoimmune disease. On the fifth day of the treatment a short cosyntropin stimulation test was

conducted, which excluded the suspicion of adrenal insufficiency, and after this hydrocortisone was withdrawn. The patient was discharged from hospital in good general condition. She was put in the care of the endocrinological outpatient clinic. Finally, we diagnosed cardiogenic and hypometabolic shock in the course of TdP-type ventricular arrhythmias secondary to LQT S in a patient with profound hypothyroidism. In ECG performed one year after the hospitalisation the QT interval was normal.

Discussion

The physiological chronotropic response and normal tension of the heart muscle in diastolic phase depend on the proper expression of tri-iodothyronine in the heart cells and its stimulating influence on $\text{Na}^+\text{-K}^+$ ATPase and Ca^{2+} ATPase in endoplasmic reticulum. Normal heart contractility is also related to proper tri-iodothyronine-stimulated transcription of the myosin heavy-chain alpha gene and inhibition of the heavy-chain beta gene. Moreover, proper tri-iodothyronine expression in the cardiac muscle affects the number of β -adrenergic receptors and their sensitivity to catecholamines [8].

Profound hypothyroidism and decreased expression of tri-iodothyronine in the heart cells may cause a worsening of cardiac contractility, a decreasing heart rate and a slowing down of the conduction of electrical stimuli in the heart muscle. This may be the reason for bradycardia and elongation of the QT interval and, in consequence, life-threatening arrhythmias may occur, for example TdP-type tachycardia.

Decreased tri-iodothyronine expression and electrolyte disorders such as moderate hypokalaemia and hypocalcaemia probably prompted LQTS and shock in this case. It is important to note that amiodarone was not sufficiently effective to prevent recurrent ventricular arrhythmias. Few publications report that lignocaine or bretylium tosylate may interrupt this kind of paroxysmal tachycardia [4]. In this case significant bradycardia and marked elongation of the QT interval limited the possibility of applying anti-arrhythmic drugs. This is why an en-

docavital electrode was introduced. During cardiac stimulation we observed shortening of the QT interval and disappearance of the ventricular arrhythmias. Fast L-thyroxine supplementation caused physiological heart-rate acceleration, progressive shortening of the QT interval and ECG normalisation.

Conclusions

1. Hypothyroidism may be the cause of life-threatening arrhythmias secondary to acquired long QT syndrome.
2. Ventricular electrostimulation was a life-saving procedure in this case of prolonged QT syndrome and ventricular arrhythmias in the course of hypometabolic crisis.
3. The use of temporary ventricular electrostimulation protected the patient against dangerous ventricular arrhythmias, while balancing the deficiency of thyroid hormones and electrolytes.

References

1. Dąbrowska B, Dąbrowski A. Podręcznik elektrokardiografii. 5th Ed. PZWL, Warszawa 2005: 213–216.
2. Fredlund BO, Olsson SB. Long QT interval and ventricular tachycardia of "torsade de pointe" type in hypothyroidism. *Acta Med Scand*, 1983; 213: 231–235.
3. Hansen JE. Paroxysmal ventricular tachycardia associated with myxedema. A case report. *Am Heart J*, 1961; 61: 692–697.
4. Kukła P, Szczuka K, Słowiak-Lewińska T et al. Nabyty zespół długiego QT z częstoskurczami typu torsade de pointes w przebiegu niedoczynności tarczycy. *Kardiologia Pol*, 2003; 58: 224–226.
5. Al-Khatib SM, Allen LaPointe NM, Kramer JM et al. What clinicians should know about the QT interval. *JAMA*, 2003; 289: 2120–2127.
6. Zipes DP, Libby P, Bonow RO, Braunwald E. Braunwald's heart disease — a textbook of cardiovascular medicine. Elsevier Saunders, Philadelphia 2005: 851–852.
7. Camm AJ, Malik M, Yap YG. Acquired long QT syndrome. Blackwell Science, London 2003.
8. Danzi S, Klein I. Thyroid hormone-regulated cardiac gene expression and cardiovascular disease. *Thyroid*, 2002; 12: 467–471.