

# Early septal activation, successful lateral ablation

Hamid Reza Bonakdar, Amir Farjam Fazelifar, Zahra Emkanjoo, Majid Haghjoo, Abolfath Alizadeh, Mohammad Tayyebi and Mohammad Ali Sadr-Ameli

Department of Pacemaker and Cardiac Electrophysiology,  
Rajaie Cardiovascular Medical and Research Centre, Tehran, Iran

## Abstract

*The coronary sinus activation pattern is an important clue for the detection of arrhythmia mechanisms and/or localization of accessory pathways. Any change in this pattern during radiofrequency ablation should be evaluated carefully to recognize the presence of another accessory pathway or innocence of the accessory pathway during arrhythmia. Intra-atrial conduction block can change the coronary sinus activation pattern. Negligence regarding this phenomenon can cause irreversible complications. Here we describe a case with left lateral accessory pathway conduction in which intra-atrial conduction block completely reversed the coronary sinus activation pattern. (Cardiol J 2008; 15: 181–185)*

**Key words:** accessory pathway, intra-atrial conduction block, ablation

## Introduction

Intra-atrial conduction block may change the coronary sinus activation pattern during left accessory pathway (AP) ablation. This barrier can convert an eccentric activation to a concentric activation pattern [1, 2]. This phenomenon has important implications for the application of radiofrequency (RF) ablation. We present a case with left lateral accessory pathway in which mitral isthmus block was unmasked with RF ablation.

## Case report

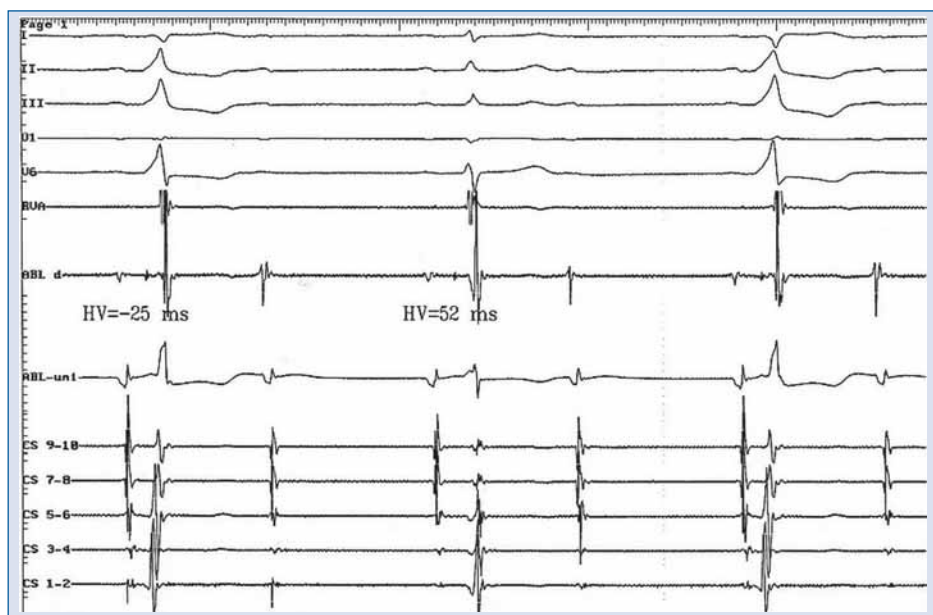
A 39-year-old man was referred to our centre for left lateral AP ablation. His medical history showed a successful bidirectional left lateral AP and slow pathway ablation for inducible atypical atrioventricular nodal re-entry tachycardia (AVNRT) (slow-intermediate) about one year before the last admission, as reported by the previous centre. The data that were available from the index procedure

note were as follow: a narrow complex tachycardia was easily induced in the presence of bidirectional left lateral AP. During RF application in the lateral part of mitral ring, the eccentric retrograde A-wave activation converted to a concentric pattern with the earliest retrograde A wave on an His catheter. Arrhythmia cycle length and VA interval on the His catheter did not change. Atrial activity did not advance with ventricular depolarization from the RV apex when the His bundle was in its refractory period. Antegrade conduction of AP was abolished after arrhythmia termination with rapid ventricular pacing. Antegrade conduction of the left lateral accessory pathway was abolished. Arrhythmia was easily inducible with programmed stimulation from the right atrium with an AH prolongation of about 20–30 ms. The new arrhythmia diagnosed as atypical AVNRT and slow pathway ablation was done after several applications of RF energy in the right posteroseptal and midseptal areas. Post ablation characteristics were as follows: PR = 230 ms, AH = 168 ms, HV = 53 ms, QRS = 78 ms,

**Address for correspondence:** Amir Farjam Fazelifar, MD, Department of Pacemaker and Cardiac Electrophysiology, Rajaie Cardiovascular Medical and Research Centre, Mellat Park, Vali-E-Asr Avenue, Tehran, 1996911151, Iran, P.O. Box 15745-1341, tel: 0098 21 2392 2931, fax: 0098 21 2204 8174, e-mail: fazelifar@gmail.com

Received: 20.06.2007

Accepted: 21.11.2007



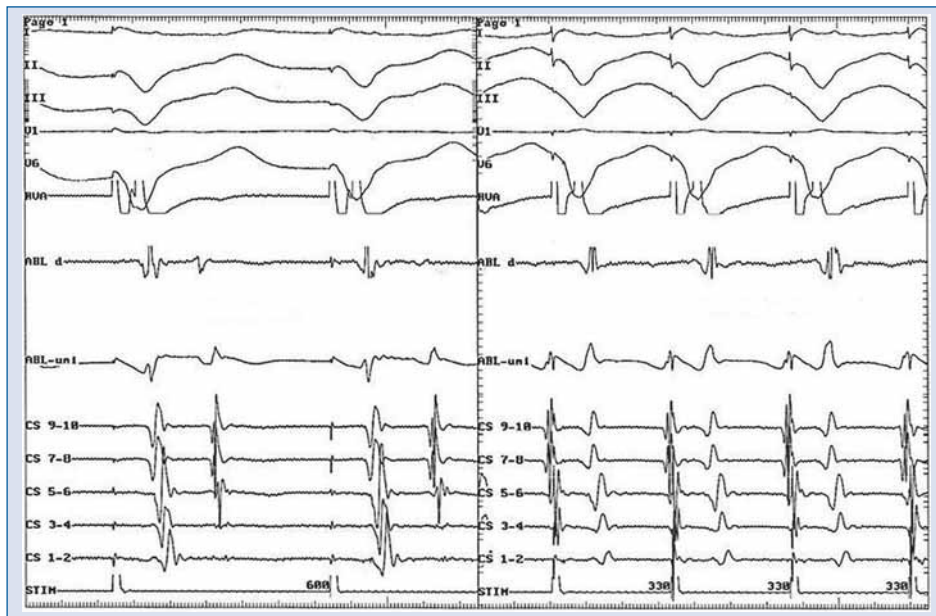**Figure 1.** 2:1 atrioventricular block during normal sinus rhythm. Please notice the intermittent normal and left lateral accessory pathway conduction. Ablation catheter is in the His position and coronary sinus 1–2 shows distal part of coronary sinus.

AVWP = 520 ms, VAWP < 300 ms, antegrade effective refractory period of AVN = 470 ms and retrograde effective refractory period of AVN < 230 ms. Ten months after the index procedure, he was readmitted to our centre because of dizziness. His ECG showed intermittent overt pre-excited beats, normal beats with long PR interval and Wenckebach rhythm (Fig. 1). A dual chamber pacemaker (kappa KDR701, Medtronic Inc, Minneapolis, USA) was implanted for symptomatic Wenckebach rhythm. After pacemaker implantation the patient complained of palpitations and the development of symptoms similar to pacemaker syndrome. He was transferred to the EP lab for an electrophysiological study. PPM was programmed to VVI with a 30 bpm back up mode. A quadripolar catheter was placed in RV apex, a decapolar steerable catheter was placed in the coronary sinus (CS 1–2 showed activation of the lateral part of the mitral ring) and a 4 mm ablation catheter was placed in the His area at the beginning of the study. Basic conduction times and refractory periods were as follows: PR interval = 215 ms, AH = 158 ms, HV = 52 ms and AV Wenckebach rate > 600 ms during normal conduction and short PR interval with negative HV interval during overt pre-excitation. The antegrade effective refractory period of AP was more than 600 ms during sinus rhythm (Fig. 1). Distal coronary sinus pacing with cycle length less than 400 ms uncovered

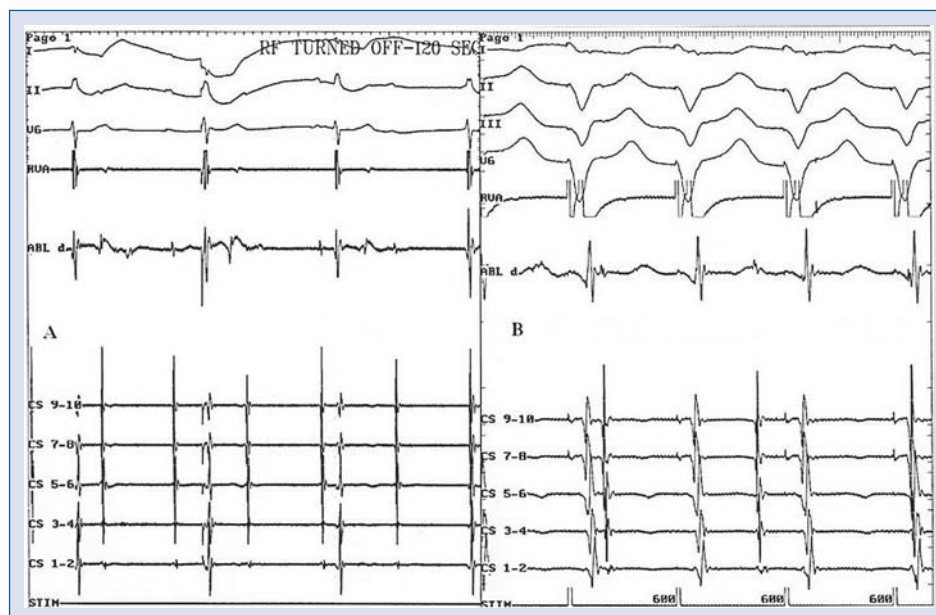overt left lateral AP conduction. Ventricular pacing from the RV apex in a different cycle length revealed a concentric LA activation with the shortest VA interval on the His catheter (Fig. 2). The VA Wenckebach point was less than 300 ms. Successful left lateral AP ablation was done via retrograde aortic approach. The intrinsic rhythm was sinus with high degree AV block. Immediately after left lateral AP ablation, ventricular pacing showed ventricular dissociation in drive cycle length = 600 ms (Fig. 3). The patient's PPM was programmed to DDD mode and he was transferred to his ward without any complications. Six months after ablation, he was asymptomatic with normal PPM function.

## Discussion

In patients with orthodromic atrioventricular reciprocating tachycardia (OAVRT), the coronary sinus activation pattern is an important key for accessory pathway localization. A change in retrograde coronary sinus activation pattern, produced by a radiofrequency lesion, suggests the coexistence of two or more accessory pathways involved in the arrhythmia, the presence of a single AP with a bifurcated atrial insertion [1] and/or the arrhythmia mechanism is AVNRT and the accessory pathway acts as an innocent bystander. Another important phenomenon that should be noticed during left



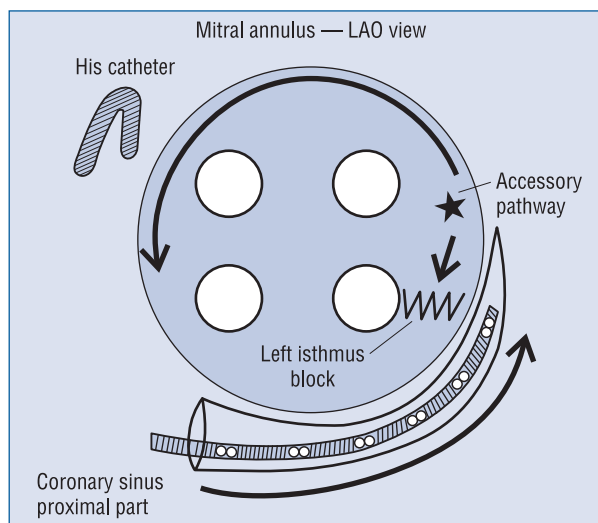
**Figure 2.** Right ventricular apex pacing in different cycle length shows 1:1 VA conduction with earliest retrograde A wave in ablation catheter which is placed in the His position.



**Figure 3. A.** Complete atrioventricular block after successful left lateral accessory pathway ablation; **B.** VA dissociation during right ventricular apex pacing (drive cycle length = 600 ms).

lateral AP ablation is intra-atrial conduction block [2]. This barrier after radiofrequency ablation can change retrograde left atrial activation without any effect on the main arrhythmia mechanism or primary accessory pathway conduction. In typical right atrial flutter, the anatomic and electrophysiological substrates (cavotricuspid isthmus) have been well de-

scribed [3–5]. A similar barrier in the left atrium is also well described [2, 6]. Cheng et al. [6] studied six cadaver hearts and showed the inferoposterior muscle bundle in relation to the surrounding left atrial structure. The muscle bundle was found parallel to the coronary sinus and was divided into two parts: one anterior and one posterior to the base of



**Figure 4.** Left atrial isthmus block between the mitral annulus and left inferior pulmonary vein after radiofrequency ablation. During right ventricular pacing, atrial depolarization proceeds from the accessory pathway insertion site along the superior mitral annulus to the His. It then propagates to the proximal and subsequently to the distal coronary sinus. This intra-atrial conduction block can show a concentric activation pattern; LAO — left anterior oblique.

the left atrial appendage [6]. In this case, although the electrophysiological data from the first ablation procedure were not available and no tachyarrhythmia was inducible during our electrophysiological study, it is possible that after the former ablation of left lateral accessory pathway, a conduction block between the lateral AP and the inferior mitral annulus was created and resulted in counterclockwise left atrium activation along the annulus and reversal of His/CS activation sequence (Fig. 4). In such cases, the arrhythmia cycle length and VA interval on His catheter do not change before and after complete medial intra-atrial conduction block. Development of concentric retrograde activity, after radiofrequency ablation for left lateral or left anterolateral accessory pathways, can suggest that a second septal accessory pathway or the left accessory pathway was not part of the circuit of arrhythmia, like AVNRT with a bystander accessory pathway. For differential diagnosis, a few electrophysiological manoeuvres should be performed. Atrial activity advancement can be seen during orthodromic AVNRT using septal accessory pathway when the premature ventricular complex is sent from the right ventricular apex in refractoriness of the His bundle. Advancement from the apex of the

right ventricle in the presence of a left lateral accessory pathway is less useful. When an eccentric pattern changes to a concentric pattern during RF ablation, we should check the advancement by premature depolarization from the lateral aspect of the left ventricle when the mitral isthmus block is suspicious and any advancement by premature depolarization from the right ventricle apex is negative. Another important point for differential diagnosis is notice of the characteristics of arrhythmia induction. AH prolongation or AH jump before arrhythmia initiation can suggest AVNRT as the main arrhythmia mechanism, and left lateral AP acts as an innocent bystander during arrhythmia. Advancement has to be negative in this arrhythmia and accessory pathway ablation cannot terminate arrhythmia induction. Arrhythmia cycle length and VA interval on His catheter should be checked carefully before and after any change in coronary sinus activation pattern. After intra-atrial conduction block, the mentioned intervals usually do not change. We could not induce any arrhythmia in this patient. VA dissociation after antegrade accessory pathway ablation revealed that the left lateral accessory pathway was the only way of retrograde conduction. During the electro physiological study, before left lateral accessory pathway ablation, ventricular pacing from RV apex up to drive cycle length < 300 ms showed a concentric His/proximal to distal part of CS activation pattern instead of the expected reverse activation model. This pattern is an important piece of evidence for the presence of intra-atrial conduction (mitral isthmus) block after RF application.

## Conclusions

Coronary sinus activation during ventricular pacing or supraventricular tachyarrhythmia is an important clue for the detection of arrhythmia mechanisms or the localization of left accessory pathways during mitral ring mapping. Any change in coronary sinus activation pattern after radiofrequency ablation can be suggestive of the presence of another accessory pathway or innocence of accessory pathway in induction and maintenance of arrhythmia. Intra-atrial conduction block can be seen infrequently during left accessory pathway ablation, but it should be considered carefully in any change of coronary sinus activation pattern in order to avoid inappropriate ablation along the mitral ring or septal area. No attention to this phenomenon can prolong ablation time and increase procedure complications and make catastrophic events such as atrioventricular node (AVN) conduction disturbance.

## Acknowledgements

The authors do not report any conflict of interest regarding this work.

## References

1. de Vasconcelos JT, Costa ER, dos Santos Galvao Filho S, Barcellos CM, Maldonado JG. Block of the mitral-pulmonary isthmus during ablation of a single left-sided accessory pathway causing different patterns of retrograde atrial activation. *Arq Bras Cardiol*, 2002; 78: 497–509.
2. Luria DM, Nemej J, Etheridge SP et al. Intraatrial conduction block along the mitral valve annulus during accessory pathway ablation: evidence for a left atrial isthmus. *J Cardiovasc Electro-physiol*, 2001; 12: 744–749.
3. Klein G, Guiraudon G, Sharma A, Milstein S. Demonstration of macro-reentry and feasibility of operative therapy in the common type of atrial flutter. *Am J Cardiol*, 1986; 57: 587–591.
4. Kalman J, Olgin J, Lee RJ, Saxon LA, Lesh MD. The anterior barrier in human atrial flutter. Role of tricuspid annulus. *Circulation*, 1995; 92: I406.
5. Cosio FG, Lopes-Gil M, Goicolea A, Arribas F, Barroso JL. Radiofrequency ablation of the inferior vena cava-tricuspid valve isthmus in common atrial flutter. *Am J Cardiol*, 1993; 71: 705–709.
6. Cheng J, Yang Y, Ursell PC et al. Protected circumferential conduction in the posterior atrioventricular vestibule of the left atrium: Electrophysiological and anatomic correlates. *PACE*, 2005; 28: 692–701.