

Transcatheter closure of iatrogenic perimembranous ventricular septal defect after aortic valve and ascending aorta replacement using an Amplatzer membranous ventricular septal occluder

Maciej Chojnicki¹, Adam Sukiennik¹, Lech Anisimowicz²,
Iwona Świątkiewicz¹ and Wojciech Pawliszak²

¹Department of Cardiology and Internal Diseases, Nicolaus Copernicus University,
Collegium Medicum, Bydgoszcz, Poland

²Department of Cardiac Surgery, Nicolaus Copernicus University, Collegium Medicum, Bydgoszcz, Poland

Abstract

Iatrogenic perimembranous ventricular septal defect is a rare complication after surgical replacement of the aortic valve, and so transcatheter closure of such a defect is not a routine procedure. We report the successful closure of an iatrogenic perimembranous ventricular septal defect which occurred after the replacement of the aortic valve and ascending aorta. (Cardiol J 2008; 15: 189–191)

Key words: interventional treatment, postsurgical ventricular septal defect, aortic valve replacement

Introduction

Iatrogenic perimembranous ventricular septal defect is a rare complication after surgical replacement of the aortic valve. Small defects are usually hemodynamically insignificant and do not need to be closed. However, some of the small ventricular septal defects occurring after such surgery may gradually enlarge, and subsequent intervention may be indicated. Since 2002, when Hijazi et al. [1] published their initial experience of percutaneous closure of congenital perimembranous ventricular septal defect with an Amplatzer membranous ventricular septal defect occluder, this procedure has been considered an alternative to surgical closure in several centres [2–4]. However, transcatheter closure of iatrogenic perimembranous ventricular septal defect after aortic valve replacement was first described by Holzer et al. [5] in 2004 and is not routine procedure.

We report the successful closure of an iatrogenic perimembranous ventricular septal defect (PMVSD) which occurred after previous replacement of the aortic valve, and subsequent replacement of the ascending aorta and valve with composite graft.

Case report

A 70-year-old male with a history of aortic valve replacement with St Jude prosthesis performed three years previously was admitted with type-A acute ascending aortic dissection. Urgent replacement of the aortic valve and dissected ascending aorta was performed. In view of the age of the patient and the heavily damaged tissues in the aortic ring, a modified composite graft made of a Dacron tube with incorporated Hancock II valve bioprosthesis was used, similar to the technique described by Urbanski [6]. The post-operative course was complicated by a complete heart block, which needed

Address for correspondence: Maciej Chojnicki, MD, PhD, Department of Cardiology and Internal Diseases, Nicolaus Copernicus University, Collegium Medicum in Bydgoszcz, M. Skłodowskiej-Curie 9, 85–094 Bydgoszcz, Poland, tel: +48 52 585 40 23; fax: +48 52 585 40 24, e-mail: maciej.chojnicki@cm.umk.pl
Received: 12.11.2007 Accepted: 19.02.2008

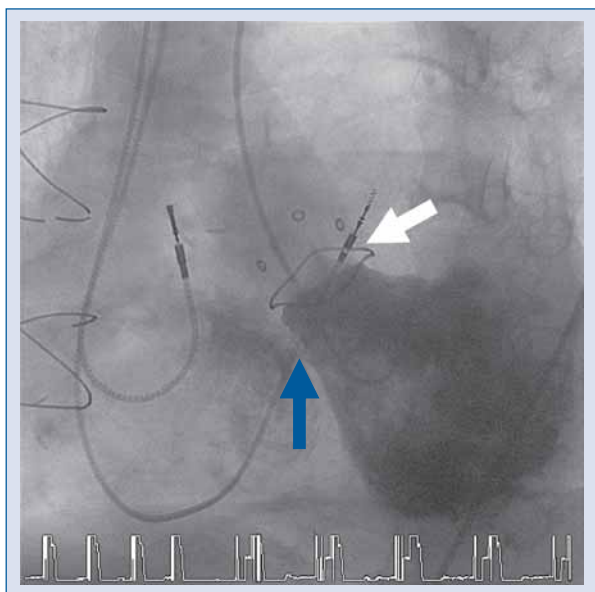


Figure 1. Cineangiographic image in the long-axial oblique view demonstrating the ventricular septal defect (blue arrow) and position of aortic bioprosthesis (white arrow).

implantation of a pacemaker, and prolonged mechanical ventilation due to chronic obstructive pulmonary disease. Transthoracic and subsequent transoesophageal echocardiography revealed a restrictive 6 mm PMVSD. Because of the lack of symptoms (New York Heart Association functional class II) and the shunt estimated as hemodynamically insignificant, the patient was managed conservatively and sent home. However, six months later the patient showed deterioration of exercise capacity to New York Heart Association functional class III/IV. Echocardiography revealed that the ventricular septal defect had increased in size from 6 mm to 10 mm. Because of his general condition and previous surgical history, percutaneous closure of the perimembranous ventricular septal defect was recommended to avoid the risk of yet another surgical intervention.

The procedure was performed with a standard technique using fluoroscopic and transoesophageal echocardiographic guidance [1].

Right femoral vein and right femoral artery approach was used. The aortic bioprosthesis was crossed using a 6 F, 3.5 cm Judkins right coronary catheter over a 0.035" Terumo glide wire (Terumo). A 6 F pigtail catheter was advanced over a wire to the left ventricle. Left ventriculography demonstrated a 10 mm perimembranous ventricular septal defect (Fig. 1). Consequently, the pigtail catheter was exchanged for a 6 F, 3.5 cm Judkins right coronary catheter. The tip of catheter was manipulated to the PMVSD, and the glide wire was advanced

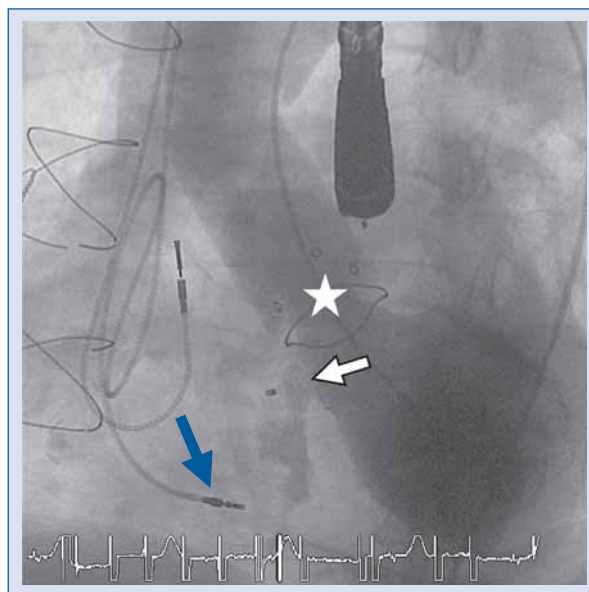


Figure 2. Cineangiographic image in the long-axial oblique view after implantation of a device in the ventricular septal defect demonstrating a trivial leak through the centre of the device (white arrow), position of aortic bioprosthesis (white star) and displacement of ventricular pacing electrode (blue arrow).

to the right ventricle and the main pulmonary artery. The Judkins catheter was advanced to the main pulmonary artery and the glide wire was exchanged for a 0.035", 300 cm long Noodle wire (AGA Medical). The wire was snared from the main pulmonary artery using a 25 mm Gooseneck snare (Microvena) and exteriorized out the right femoral vein. Over the wire from the venous side, an 8 F Torqueview delivery sheath (AGA Medical) was advanced. During attempts to pass the delivery sheath through the ventricular septal defect, the ventricular pacing lead was dislodged, so a temporary pacing lead was placed in the right ventricle. The ventricular septal defect was closed using the technique described in detail by Hijazi et al. [1]. A 12 mm Amplatzer perimembranous ventricular septal defect occluder was used. Angiography after implantation of the device revealed a trivial leak through the mesh of the device (Fig. 2). The procedure was otherwise uncomplicated and at the end a new permanent pacing electrode was implanted. Echocardiography a day after the procedure showed complete closure of the ventricular septal defect. Follow-up assessments six months and one year after the procedure confirmed complete closure of the ventricular septal defect, no aortic bioprosthesis dysfunction and improvement of symptoms to New York Heart Association functional class II.

Discussion

Percutaneous closure of ventricular septal defects is an alternative to the surgical treatment in selected cases. Ventricular septal defects are a rare complication after cardiac surgery but they may occur more often in patients who have undergone repeat cardiac surgery in the left ventricular outflow tract. In such patients, further repeat surgery may carry an increased operative risk. Therefore, percutaneous treatment with a device is an attractive therapeutic option. Results of transcatheter closure of iatrogenic ventricular septal defect, even in patients with mechanical aortic valve prosthesis, have been published in the past few years and are very encouraging. Holzer et al. [5] first described two patients with iatrogenic perimembranous ventricular septal defect after aortic valve replacement, who were treated by transcatheter interventional device closure. Our patient underwent an operation in which a dissection of the ascending aorta and previously implanted mechanical aortic valve prosthesis were removed and replaced with a composite graft using a biological valve sewn into a Dacron tube using Urbanski's method. The prosthetic valve in this type of operation is sewn into the aortic graft, a few millimetres above the level of the native aortic orifice (Fig. 3). Urbanski's method allows the use of a prosthetic valve of at least one size bigger than conventional conduits and carries the advantage of easily obtaining a tight, elastic and hemostatic composite graft connection to the left ventricle. In our case, the distance between the proximal aortic valvular edge and the upper border of the ventricular septal defect allowed percutaneous closure of the iatrogenic defect using a device. Special care must be taken when crossing the aortic bioprosthesis to avoid damage to the prosthesis leaflet.

Iatrogenic ventricular septal defect is a rare but potentially serious complication of aortic valve replacement and may be difficult to treat. Interventional closure of a hemodynamically significant perimembranous ventricular septal defect with an Amplatzer PMVSD occluder (AGA Medical) is possible in patients in whom a ventricular septal defect is likely to occur after previous replacement of the ascending aorta and valve.

Acknowledgments

The authors would like to thank Professor Michael Tynan and doctor Shakeel Qureshi for review of the manuscript. We would also like to thank Tomasz Rozwadowski for preparation of the figures.

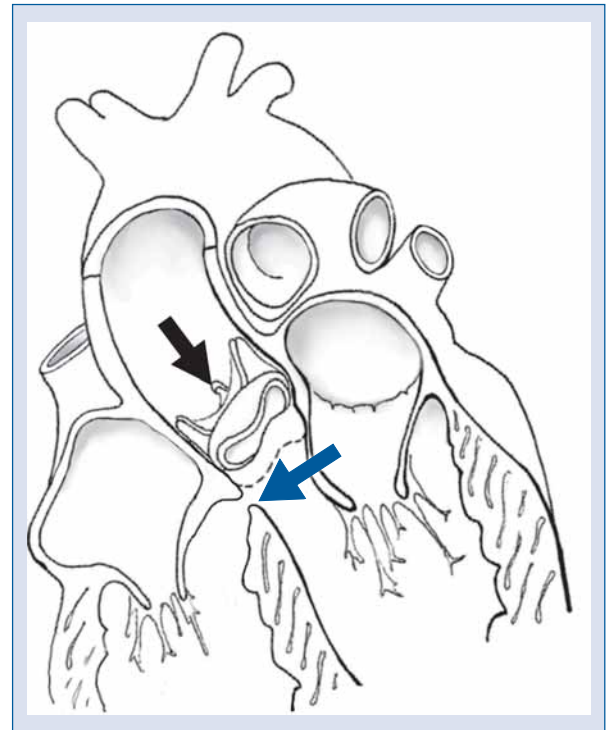


Figure 3. Schematic demonstration of the position of ventricular septal defect (blue arrow) and bioprosthesis (black arrow). Note the intermittent line shows previous prosthetic valve position.

The authors do not report any conflict of interest regarding this work.

References

- Hijazi Z, Hakim F, Haweleh A et al. Catheter closure of perimembranous ventricular septal defect using the new Amplatzer membranous VSD occluder: Initial experience. *Catheter Cardiovasc Interv*, 2002; 56: 508–515.
- Masura J, Gao W, Gavora P et al. Percutaneous closure of perimembranous ventricular septal defects with the eccentric Amplatzer device: Multicenter follow-up study. *Pediatr Cardiol*, 2005; 26: 216–219.
- Szkutnik M, Qureshi S, Kusa J, Rosenthal E, Bialkowski J. Use of the Amplatzer muscular ventricular septal defect occluder for closure of perimembranous ventricular septal defects. *Heart*, 2007; 93: 284–286.
- Walsh M, Coleman D, Oslizlok P, Walsh K. Percutaneous closure of postoperative ventricular septal defects with the Amplatzer device. *Catheter Cardiovasc Interv*, 2006; 67: 445–451.
- Holzer R, Latson L, Hijazi Z. Device closure of iatrogenic membranous ventricular septal defects after prosthetic aortic valve replacement using the Amplatzer membranous ventricular septal occluder. *Catheter Cardiovasc Interv*, 2004; 62: 276–280.
- Urbanski P. Replacement of ascending aorta and aortic valve with a valve stentless composite graft. *Ann Thorac Surg*, 1999; 67: 1501–1502.